

CASE REPORT

Legionnaires' Disease: A Rare Entity in Puerto Rico?

KAREM PRÍNCIPE RODRÍGUEZ, MD; WILLIAM RODRÍGUEZ CINTRÓN, MD, FACP, FCCP, FCCM

Legionnaires' disease is a severe, often fatal pneumonia, caused by *Legionella pneumophila*. Its incidence is reported about 6%. In Puerto Rico, there is no data available of the prevalence of Legionnaires' disease. A

case of Legionnaires' is presented as well as data to support that the prevalence in our Island is higher than the reported elsewhere. Key words: Legionnaires disease, Pneumonia, Epidemiology, Puerto Rico

Legionnaires' disease was described for the first time in 1977 by Fraser et al after an outbreak of pneumonia during the American Legion Convention held in Philadelphia in 1976 (1). This outbreak caused 225 cases with 34 deaths. Since its isolation, there has been described 34 species of *Legionella* and more than 52 serogroups have been described. The reported incidence has ranged from 1 to 27%, although the most consistent value is about 6% (2). Studies ranks *Legionella spp.* second in incidence, after *Pneumococcus*, as the cause of severe community-acquired pneumonia with high mortality (3-4). Although rare, the availability of more sensitive diagnostic techniques, should prompt our inquisitiveness and consider this clinical entity (5). In Puerto Rico, no study has been published on the prevalence of Legionnaire's disease in our population, although preliminary screenings suggests that the disease is more prevalent in Puerto Rico than reported in other countries. We present a case of Legionnaires' disease diagnosed in our institution and supporting data to make physicians aware of the presence of this entity in our geographical environment.

Case Report

A 55-year-old man with adult-onset diabetes mellitus on troglitazone (Rezulin®) and an active smoker of 30

From the Department of Medicine, Pulmonary Diseases Training Program, San Juan Veterans Affairs Medical Center, San Juan, Puerto Rico.

Presented in part at the Annual Meeting of the American College of Physicians, Philadelphia, Pennsylvania, April 2000.

Address for correspondence to: William Rodriguez, MD, Pulmonary Section OPA Room 1F218, 10 Casia Street, San Juan, PR 00921-3201, Tel. (787)641-7582 ext. 31589, Fax.(787) 641-9541, E-mail: william@prmail.net

pack/year, came to our center with general malaise, shortness of breath, dry cough, fever, headaches and diarrhea of 3 days duration. He had no abdominal pain, vomits or sputum production. He had no hobbies, there were no pets in his house or history recent trips abroad. He was febrile (104.0° F, oral), moderately tachypneic (RR 32/min.), tachycardic (110 bpm) and his blood pressure was 140/80. He was alert and active, but acutely ill. A grade 2/6 systolic murmur was heard along the left sternal border, no gallops or rubs were present. He had symmetric lung expansion with subcostal retractions, dullness at the right lung base with decreased breath sounds as well as inspiratory crackles at the left base. Chest radiograph showed increased reticular markings at the left base (Fig. 1A). Laboratory findings showed serum sodium of 124 meq/l, potassium 3.3 meq/l and creatine phosphokinase (CPK) of 684 U/L. There was no leukocytosis nor left shifting in the differential count, the pO₂ was 57.8 mmHg and the alveolo-capillary gradient was increased at room air.

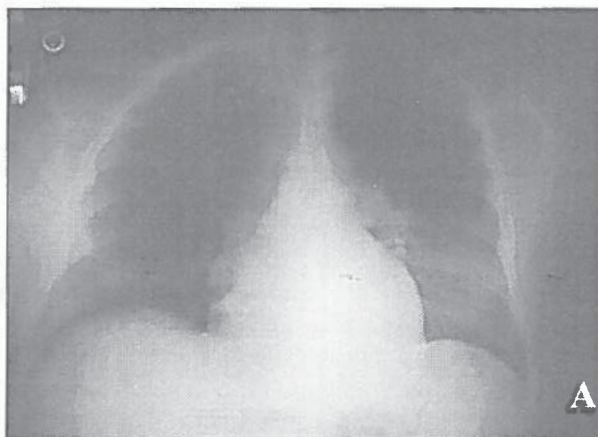


Figure 1A. Chest radiograph upon admission, which shows a reticular infiltrate in the lower lobe of the left lung.

He was admitted with the diagnosis of left lower lobe pneumonia and started on ceftriaxone (Rocephin®) 1 gm IV daily and erythromycin 500 mg IV every six hours. Despite treatment, the patient's clinical condition deteriorated, dyspnea and hypoxemia increased. Chest radiograph showed progression of the left lower lobe infiltrate with alveolar consolidation and small left pleural effusion (Fig. 1B). On the 5th hospital day the patient

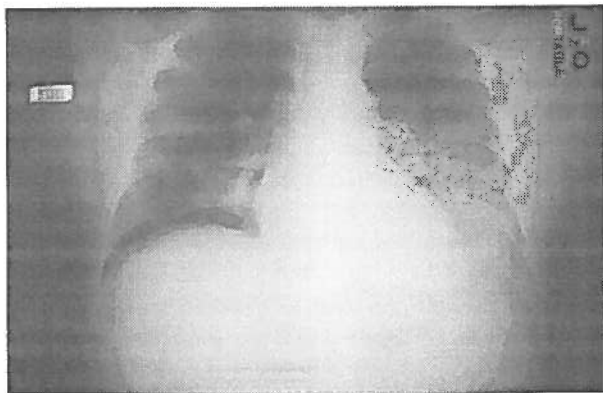

Figure 1B. Follow-up chest radiograph shows worsening of the left lower lobe infiltrate as assessed by further lobe consolidation and development of a small pleural effusion.

underwent a flexible bronchoscopy with bronchioalveolar lavage and transbronchial biopsy. Clear secretions were seen and mild bronchial inflammation was reported on the pathology exam. Cytology and cultures were negative for malignancy, bacteria, fungus, virus and mycobacteria. The antibiotic therapy was modified and high dose erythromycin (1.0 gm every 6 hours) was started. This produced a marked improvement in his clinical condition. By this time, the *Legionella* antigen in urine was reported positive and the serum *Legionella* antibody was reported 1:256 dilutions. He continued improving and was discharged home after 14 days of high dose IV erythromycin therapy.

Discussion

In Puerto Rico, there is no data at the Department of Health on the prevalence of Legionnaires' disease. In 1987, Hazen TC et al, reported the presence of *Legionella spp.* in Puerto Ricans waters (6). They analyzed marine and freshwater samples for *Legionella spp.* by direct fluorescent antibody (DFA) and guinea pig confirmation. They found that *Legionella spp.* was ubiquitous. Moreover, the DFA densities fluctuated from 10^1 to 10^5 cells ml^{-1} , which were higher than that found in corresponding habitats in the United States (DFA densities 10^3) (7). The densities considered pathogenic to humans are 10^5 to 10^6 cells ml^{-1} .

A survey was done on 88 patients that died of undiagnosed pneumonia or acute respiratory distress syndrome at the Puerto Rico Medical Center in 1984. Thirteen of these patients (15%) were positive for *Legionella pneumophila* by DFA staining of lung tissue, suggesting that Legionnaires' is a common cause of fatal pneumonia in Puerto Rico (8).

A preliminary survey done from January 1997 to September 1999 in the San Juan Veterans Affairs Medical Center, found 390 patients diagnosed with atypical pneumonia. Of these, only ten patients had samples taken for *Legionella* and two of them (20%) were positive (unpublished data). On the other hand, as part of an investigational trial with community acquired pneumonia, two out of eleven patients (18%) have been found with Legionnaires' disease at our institution.

Although these surveys includes small number of patients and may lack statistical power, they suggest that the prevalence of Legionnaires' disease in Puerto Rico ranges between 15-20%, incidences much higher than those reported elsewhere. It is known that water is the natural habitat for *Legionella* and that warm water exerts a crucial influence on the growth of the organism by favoring its proliferation and that of other protozoan that shelter the microorganism. Hazen et al (6) demonstrated a positive correlation between *Legionella spp.* densities and water temperature, alkaline pH, phosphates and sulfates and they suggests that the high concentration of organic matter in wet tropics provide *Legionella spp.* and other microorganisms with the substrates needed to reach higher densities. This could explain the tendency toward higher incidence in Puerto Rico. The small number of cases reported in our island is worrisome, since it implies an underdiagnosis and underreporting of the disease. Legionnaires' disease presents as a severe, often fatal pneumonia. It is important that therapy must be instituted early, since the bacillus is very sensitive to antimicrobial agents, which are readily accessible and well tolerated (9). Many studies have shown that a delay in appropriate therapy is associated with higher mortality (10). This case illustrates the need for an increased awareness of the prevalence of the disease in our environment. Physicians should use the new diagnostic techniques for the identification of *Legionella* whenever the clinical scenario of severe bronchopneumonia with acute respiratory distress is present.

Resumen

La enfermedad de los Legionarios se identificó por primera vez en 1976 en una convención de miembros de la Legión Americana en la ciudad de Philadelphia. Es causada

por la *Legionella pneumophila*, una bacteria gram negativa que produce en los humanos una bronconeumonía severa y en ocasiones mortal. Su habitat normal son los lagos, quebradas, suelo húmedo y se transmite por vía aeróbica. Este organismo se ha encontrado frecuentemente en los sistemas de enfriamiento de agua, condensadores de agua evaporada y hasta en el agua corriente. Se ha reportado como agente causal en 6% de las bronconeumonías en los Estados Unidos. En Puerto Rico no hay data disponible sobre la prevalencia de esta enfermedad. Presentamos un caso de esta enfermedad diagnosticada en nuestra institución, alertando que su incidencia en los procesos broncopulmonares en nuestra isla puede ser mayor de lo pensado y hacer esfuerzos por lograr identificar la bacteria en estos pacientes.

References

1. Fraser DW, Tsai TR, Orenstein W, et al. Legionnaires' disease: description of an epidemic of pneumonia. *N Engl J Med* 1977;297:1189-97
2. Fang GD, Fine M, Orloff J, et al. New and emerging etiologies for community acquired pneumonia with implications for therapy: a prospective, multicenter study of 359 cases. *Medicine* 1990;86:7-13
3. Torres A, Serra-Batles J, Ferrer A, et al. Severe community-acquired pneumonia: epidemiology and prognostic factors. *Am Rev Respir Dis* 1991;144:312-18
4. Rello J, Quintana E, Ausina V, et al. A three year study of severe community-acquired pneumonia with emphasis on outcome. *Chest* 1993;103:232-35
5. WHO: Epidemiology, prevention and control of Legionellosis: Memorandum from a WHO meeting. *Bull World Health Organ* 1990;68:155-64
6. Ortiz-Roque CM, Hazen TC. Abundance and distribution of *Legionellaceae* in Puerto Rican Waters. *Appl Environ Microbiol* 1978;53(9):2231-2236
7. Fliermans CB, Soracco RS, Pope DH. Measure of *Legionella pneumophila* activity in situ. *Curr Microbiol* 1981;6:89-94
8. Meyer RD. *Legionella* infections: a review of five years of research. *Rev Infect Dis* 1983;5:258-78
9. Klein NC, Cunha BA. Treatment of Legionnaires' disease. *Sem Respir Infect* 1998;13(2):140-6
10. Heath CH, Grove DI, Looke DF. Delay in appropriate therapy of *Legionella* pneumonia associated with increased mortality. *Eur J Clin Microbiol Infect Dis* 1996;15(4):286-90