

## • CASE REPORT •

# Sporadic Creutzfeldt-Jakob Disease in a Native Puerto Rican Patient

Esteban A. Del Pilar-Morales, MD\*; Ignazio Cali, MSc†‡; Javier Chapas, MD§; Jorge Bertrán-Pasarell, MD\*; Gianfranco Puoti, MD, PhD\*\*, Pierluigi Gambetti, MD†; Ulises Nobo, MD††

The diagnosis of Creutzfeldt-Jakob disease (CJD) is often a challenge for most physicians given its extremely low incidence and different clinico-pathological presentations. We report the case of a 56-year old patient native to Puerto Rico suspected of sporadic Creutzfeldt-Jakob disease (sCJD). The symptoms at onset were notorious for bilateral cortical blindness followed by rapidly progressive cognitive decline, visual deficit, increased levels of CSF 14-3-3 and tau along with positive brain MRI and EEG, are highly indicative of CJD. The definite diagnosis was confirmed by the National Prion Disease Pathology Surveillance Center (NPDPS), in Cleveland, Ohio, USA. Lack of genetic mutations in the prion protein (PrP) gene, widespread histopathological changes and the accumulation of scrapie PrP (PrP<sup>Sc</sup>) in the brain confirmed the diagnosis of sCJD. The patient, admitted to our institution in 2011, represents the first detailed report of sCJD in a native Puerto Rican patient living in Puerto Rico. [*PR Health Sci J* 2015;34:40-43]

*Key words: Creutzfeldt-Jakob Disease, Prion disease, Rapidly progressive dementia, CSF protein tau, CSF protein 14-3-3*

Prion diseases are transmissible neurodegenerative disorders with different etiologies as they can be sporadic, genetic or acquired by infection (1,2). Sporadic Creutzfeldt-Jakob disease (sCJD) is the most common form of the sporadic human prion diseases. Despite this fact, sCJD remains a rare condition as it affects ~ 1 per 1 million cases per year worldwide (3). In sCJD and other human prion diseases, the codon 129 of the prion protein (PrP) gene, the site of a common methionine (M)/valine (V) polymorphism, and the two different types of the scrapie prion protein (PrP<sup>Sc</sup>), are considered modifiers of the disease phenotype (1). Combinations of the codon 129 genotype (129MM, 129MV and 129VV) and PrP<sup>Sc</sup> type (either type 1 or type 2) have been used to classify sCJD into five different subtypes<sup>4</sup>. The sCJDMM1 (e.g. 129MM and PrP<sup>Sc</sup> type 1) is the most common subtype and accounts for 55-70% of all sporadic prion diseases (3,4).

### Case Report

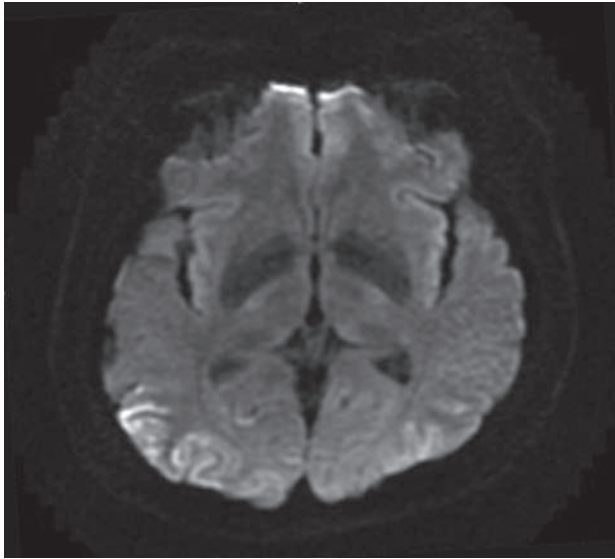
A 56 year-old woman with hypertension began experiencing headaches and episodes of spatial disorientation. Evaluated by her primary care physician, she underwent a head CT scan and general blood tests which resulted unremarkable. She was treated for tension headache. Within the following two months, visual difficulty was reported and the disorientation became more constant into the context of a global rapidly progressive cognitive decline. Evaluation of cerebrospinal fluid (CSF) did

not reveal any abnormalities, whereas 14-3-3 and tau protein tested positive. Upon admission to our institution, the patient was found poorly responsive, responding almost exclusively to pain, unable to eat and in mild respiratory distress due to aspiration pneumonia. Patient presented also with an acute kidney injury, likely secondary to severe dehydration. Further work-up with brain magnetic resonance imaging (MRI) revealed restricted diffusion signal over the periventricular areas and over occipital lobes bilaterally, more prominent over the right (Figure 1) which are consistent with the typical “cortical ribbon sign” seen in almost more than 90% of sCJD patients; electroencephalography (EEG) showed disease-typical generalized periodic sharp wave complexes (GPSWC) at a frequency of 1 Hz, which typically occur in about 50% or two-thirds of the patients with sCJD (3) during the sub acute

\*Infectious Disease Section, Internal Medicine Department, University of Puerto Rico Medical Sciences Campus, San Juan, Puerto Rico; †National Prion Disease Pathology Surveillance Center (NPDPS), Case Western Reserve University, School of Medicine, Cleveland, OH; ‡PhD Program in Experimental Physiopathology and Neuroscience - Second University of Naples, Italy; §Neurology Department, University of Puerto Rico Medical Sciences Campus, San Juan, Puerto Rico; \*\*Division of Neurology, Department of Clinical and Experimental Medicine, Second University of Naples, Italy; ††Neurology Section, HIMA Hospital, Caguas, Puerto Rico

*The authors have no conflict of interest to disclose.*

**Address correspondence to:** Jorge Bertrán-Pasarell, MD, FACP, Infectious Diseases Program, Department of Medicine, University of Puerto Rico Medical Sciences Campus, PO BOX 5067 San Juan PR 00936-5067. Email address: jbertrandm@hotmail.com



**Figure 1.** Brain MRI (DWI). "Cortical Ribboning" - Restricted diffusion signal over periventricular areas and right occipital lobe consistent with patient's visual symptoms. This findings are typical of the Heidenhain variant of sCJD.

period of the condition. The history of the patient failed to reveal travels outside of the country, any possible exposure to bovine spongiform encephalitis agents, or the receipt of any transplanted organs. She had a blood transfusion at the age of 41 years due to blood loss following a hysterectomy. Based on this data, sporadic CJD was highly suspected.

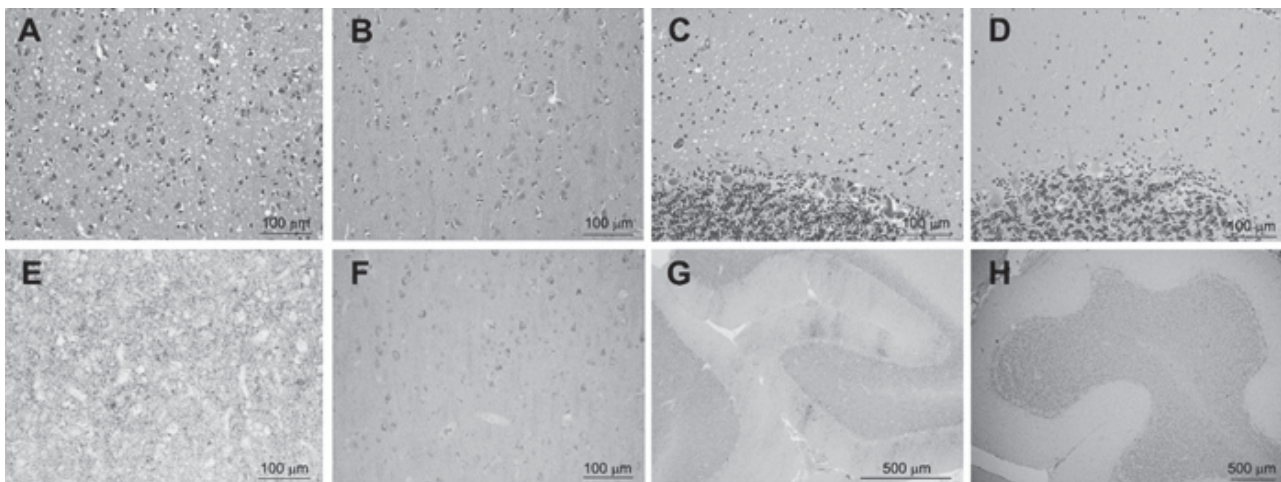
With treatment, the patient's pneumonia resolved along with her acute kidney injury, but her neurologic status worsened and the patient became more obtunded. Currently there is no available treatment for CJD. Condition and prognosis

(sporadic CJD is invariably fatal) were explained to the family, who decided to issue a Do Not Resuscitate/ Do Not Intubate (DNR/DNI) order. The patient died 2 months after the onset of the symptoms. The patient's family agreed to have autopsy examination to confirm the diagnosis of sCJD. However, the pathologists at Puerto Rico's Health Department expressed their lack in expertise and training to perform this type of procedure. The National Prion Disease Pathology Surveillance Center (NPDPS) in Cleveland, Ohio, USA, was contacted and agreed to fly to Puerto Rico to perform the autopsy. At the NPDPS, genetic examination of the PrP gene revealed the presence of methionine (M) homozygosity at codon 129 and no mutations. Histopathology showed widespread small vacuoles spongiform degeneration and gliosis throughout the brain as well as diffuse PrP immunostaining (Figure 2). Western blot examination disclosed the presence of proteinase-K (PK)-resistant PrP<sup>Sc</sup> (PrP<sup>res</sup>) co-migrating with PrP<sup>res</sup> type 1 of sCJDMM1 (Figure 3).

## Discussion

After reviewing the literature, the present case represents the first detailed report of a sCJD patient native to Puerto Rico. The clinical and histopathological features of this case fit well with those of the sCJDMM1 subtype, as confirmed by the genetic and molecular data carried out by the NPDPS.

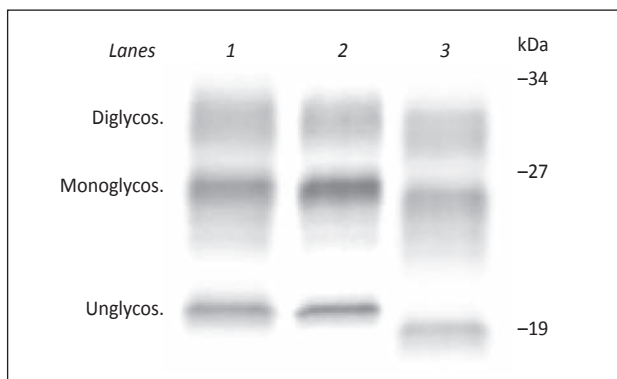
Two more sCJD cases of patients native and resident to Puerto Rico were listed in the NPDPS data bank. These two cases had genotype 129MM (age at disease onset: 63 years; disease duration: 8 months) or 129MV (age at disease onset: 66 years; disease duration: 8 months) and both carried PrP<sup>res</sup> type 1. Thus, the three sCJD cases native to Puerto Rico belong to the sCJDMM(MV)1 subtype (4).



**Figure 2.** Histological and immunohistochemical examinations. Typical spongiform degeneration (SD) with small vacuoles affecting the frontal cortex (A) and cerebellum (C) of the present case. The same brain regions are not affected in a non-CJD brain (B, D). Diffuse or "synaptic" pattern of PrP deposition in the frontal cortex (E) and cerebellar molecular layer (G), and negative PrP staining in a non-CJD brain (F, H). Antibody: 3F4. B, F: Frontal cortex; D, H: cerebellum.

Several diagnostic criteria have been proposed for a “probable” sCJD, diagnosis (5-7). The Center for Disease Control and Prevention (CDC) outlines all the criteria for probable sCJD ([http://www.cdc.gov/ncidod/dvrd/cjd/diagnostic\\_criteria.html](http://www.cdc.gov/ncidod/dvrd/cjd/diagnostic_criteria.html)) (Table 1).

There was concern that the patient could have developed sCJD due to a blood transfusion received several years before the onset of the disease. Nevertheless, epidemiologic studies, although limited, have not provided evidence of transmission of sCJD by blood transfusion to date (8-9). Thus, in this native Puerto Rican patient, the potential risk of having acquired the disease via blood transfusion is unlikely.



**Figure 3.** Western blot analysis. After proteinase-K (PK) digestion, the unglycosylated PK-resistant PrP<sup>Sc</sup> (PrP<sup>res</sup>) of the present case (lane 2) migrates to ~20 kDa, matching PrP<sup>res</sup> type 1 of sCJDMM1 (lane 1). In sCJDMM2 (lane 3) the unglycosylated PrP<sup>res</sup> type 2 migrates ~ 1 kDa faster to ~ 19 kDa. Diglycos.: diglycosylated; Monoglycos.: monoglycosylated; Unglyc.: unglycosylated. Antibody: 3F4.

Another concern was whether the patient needed to be isolated. Review of the literature shows that physical contact with CJD patients entails no risk of transmission, and special precautions are not required in their care. Normal social and clinical contact and non-invasive clinical investigations (e.g. X-ray imaging procedures) with CJD patients do not present a risk to healthcare workers, relatives, or the community. Based on current knowledge, isolation of patients is not necessary; they can be nursed in the open ward using Standard Precautions (10). However, special precautions are required in handling of CSF and other brain-related tissues; all materials and instruments used must be disposable or adequately decontaminated according to established protocols since routine sterilization is not sufficient for CJD (11-12).

In summary, we analyzed the case of a woman presenting rapidly progressive dementia without other identifiable pathologies that could explain her clinical symptoms. After thorough inspection of the patient’s history and examination, CJD was suspected. Subsequently, a lumbar puncture was performed. The puncture tested positive for 14-3-3 and tau, which made CJD a very probable diagnosis at that time (13).

The diagnosis was later confirmed by brain autopsy at the NPDPS. This report represents the first detailed description of sCJD in a Puerto Rican family.

### Resumen

El diagnóstico de la enfermedad de Creutzfeldt-Jakob disease (CJD por sus siglas en inglés) es un reto para la mayoría de los médicos debido a su muy baja incidencia y variadas presentaciones. Aquí reportamos el caso de una mujer de 56 años de edad, original de Puerto Rico con sospecha de CJD esporádico (sCJD). En el momento de la presentación, los síntomas más notables fueron ceguera cortical bilateral seguido de un rápido y progresivo deterioro cognoscitivo, aumento en los niveles en el líquido cefalorraquídeo de las proteínas 14-3-3 y tau en conjunto con una imagen de resonancia magnética y electroencefalograma altamente indicativos de CJD. El diagnóstico definitivo fue obtenido por el Centro Nacional de Patología Para la Vigilancia de Enfermedades por Prion (NPDPS por sus siglas en inglés), en Cleveland, Ohio, Estados Unidos. Carencia de mutación de genes en la proteína de Prion (PrP), cambios difusos histopatológicos, y acumulación de scrapie PrP (PrP<sup>Sc</sup>) en tejido del cerebro confirma el diagnóstico de sCJD. La paciente fue admitida a nuestra institución en el 2011 y representa el primer reporte detallado de un paciente con sCJD oriundo de Puerto Rico sin viajes al exterior.

**Table 1.** The Centers for Disease Control and Prevention criteria for probable sporadic CJD:

Progressive dementia
Two of the following neurologic symptoms: myoclonus, visual or cerebellar disturbances, pyramidal/extrapyramidal dysfunction, or akinetic mutism
Atypical electroencephalogram during illness duration
Positive 14-3-3 CSF assay
Less than 2 years from presentation to death
MRI with high signal abnormalities in caudate or putamen on DWI or FLAIR
Routine investigations discards alternative diagnosis

CDC criteria for the identification of probable case of sCJD pending pathological diagnosis

### References

- Gambetti P, Kong Q, Zou W, et al. Sporadic and familial CJD: classification and characterisation. *Br Med Bull* 2003;66:213-239.
- Gambetti P, Cali I, Notari S, et al. Molecular biology and pathology of prion strains in sporadic human prion diseases. *Acta Neuropathol* 2011;121:79-90
- Puoti G, Bizzi A, Forloni G, et al. Sporadic human prion diseases: molecular insights and diagnosis. *Lancet Neurol* 2012;11:618-628
- Parchi P, Giese A, Capellari S, et al. Classification of sporadic Creutzfeldt-Jakob disease based on molecular and phenotypic analysis of 300 subjects. *Ann Neurol* 1999;46:224-233.

5. Ladogana A, Puopolo M, Croes EA, et al. Mortality from Creutzfeldt-Jakob disease and related disorders in Europe, Australia, and Canada. *Neurology* 2005;64:1586.
  6. Brandel JP, Delasnerie-Lauprêtre N, Laplanche JL, et al. Diagnosis of Creutzfeldt-Jakob disease: effect of clinical criteria on incidence estimates. *Neurology* 2000;54:1095.
  7. Zerr I, Kallenberg K, Summers DM, Romero C, Updated clinical diagnostic criteria for sporadic Creutzfeldt-Jakob disease. *Brain* 2009;132:2659–2668.
  8. Hewitt PE, Llewelyn CA, Mackenzie J, Will RG. Creutzfeldt-Jakob disease and blood transfusion: results of the UK Transfusion Medicine Epidemiological Review study. *Vox Sang* 2006;9:221-230
  9. Chohan G, Llewelyn C, Mackenzie J, et al. Variant Creutzfeldt-Jakob disease in a transfusion recipient: coincidence or cause?. *Transfusion* 2010;50:1003-1006.
  10. WHO Infection Control Guidelines for Transmissible Spongiform Encephalopathies. Report of a WHO consultation. Geneva, Switzerland, 23-26 March 1999
  11. Taylor DM. Preventing accidental transmission of human transmissible spongiform encephalopathies. *Br Med Bull* 2003;66:293.
  12. Blättler T. Implications of prion diseases for neurosurgery. *Neurosurg Rev* 2002;25:195.
  13. Hamlin C, Puoti G, Berri S, et al. A comparison of tau and 14-3-3 protein in the diagnosis of Creutzfeldt-Jakob disease. *Neurology* 2012;79:547-552.
-