

## Refractory dissecting Cellulitis of the Scalp Successfully controlled with Adalimumab

Rafael F. Martín-García, MD, FAAD\*; Jennifer M. Rullán, MD, FAAD†

**Dissecting cellulitis of the scalp (DCS) is an uncommon inflammatory disease that often results in scarring alopecia. Numerous therapies have either proved ineffective or only temporarily effective in the management of this condition. Recent reports show adequate responses to tumor necrosis factor (TNF) inhibitors in cases of DCS. We report a case of severe recalcitrant DCS successfully treated with adalimumab. [P R Health Sci J 2015;34:102-104]**

*Key words: Scarring alopecia, Hair disorders, Biologics, TNF $\alpha$ -inhibitors*

**D**issecting cellulitis of the scalp (DCS) is an uncommon chronic and relapsing inflammatory disease predominantly occurring in the scalp of young black or Hispanic men. The pathophysiology of DCS has been linked to the other disorders of the follicular occlusion triad (1). Secondary bacterial infection can occur in DCS but is not a primary event (2). Early clinical findings include the presence of follicular-centered erythematous papules and pustules that will later evolve into fluctuating nodules with interconnecting sinuses, due to abnormally increased follicular keratinization leading to follicular obstruction, dilatation, and rupture. Expulsed follicular contents attract inflammatory molecules with eventual formation of foreign-body-like granulomas. In time, this chronic inflammation will lead to sinus tracts, follicular destruction, and disfiguring scarring alopecia.

DCS has proven to be persistent or recurrent to different therapies. These include topical, intralesional, and systemic steroids, incision and drainage, antibiotics (3), zinc sulfate (4), isotretinoin (5), dapsone (6), wide surgical excision with split-thickness grafting (7), and laser surgery including photoepilation (8).

Successful treatment of pathophysiologically-associated diseases such as hidradenitis suppurativa (HS) with tumor necrosis factor (TNF) inhibitors have been reported previously, although responses are not consistent (9). Recent reports document successful management of patients with DCS with TNF inhibitors (2, 10-12). We report a patient with recalcitrant DCS who was successfully treated with adalimumab.

### Case Report

A 30-year-old Hispanic man with a fifteen-year history of DCS presented with scattered tender fluctuant nodules on the scalp with associated overlying alopecia (Figure 1.A). Previous treatments included intralesional corticosteroids, antibiotics, and several courses of isotretinoin. He reported that isotretinoin was very helpful in controlling the condition but the disease returned after discontinuation of treatment.

The patient was started on doxycycline 100 mg twice a day for two months without improvement and was then switched to ciprofloxacin 500 mg twice a day, along with incision, drainage, and intralesional triamcinolone injections with minimal improvement after three months.

After obtaining a negative skin culture, purified protein derivative, chest x-ray, hemogram, chemistry panel, and hepatitis B and C serologies, adalimumab (80 mg on day 0, 40 mg on day 7, 40 mg every other week thereafter) was started. After one month the patient reported a significant decrease in pain and swelling of the lesions, which progressively improved. At seven months of therapy, the patient was completely clear of inflammatory lesions (Figure 1.B). The treatment has been well tolerated by the patient for more than two years without adverse events. He continues on adalimumab 40 mg every other week.

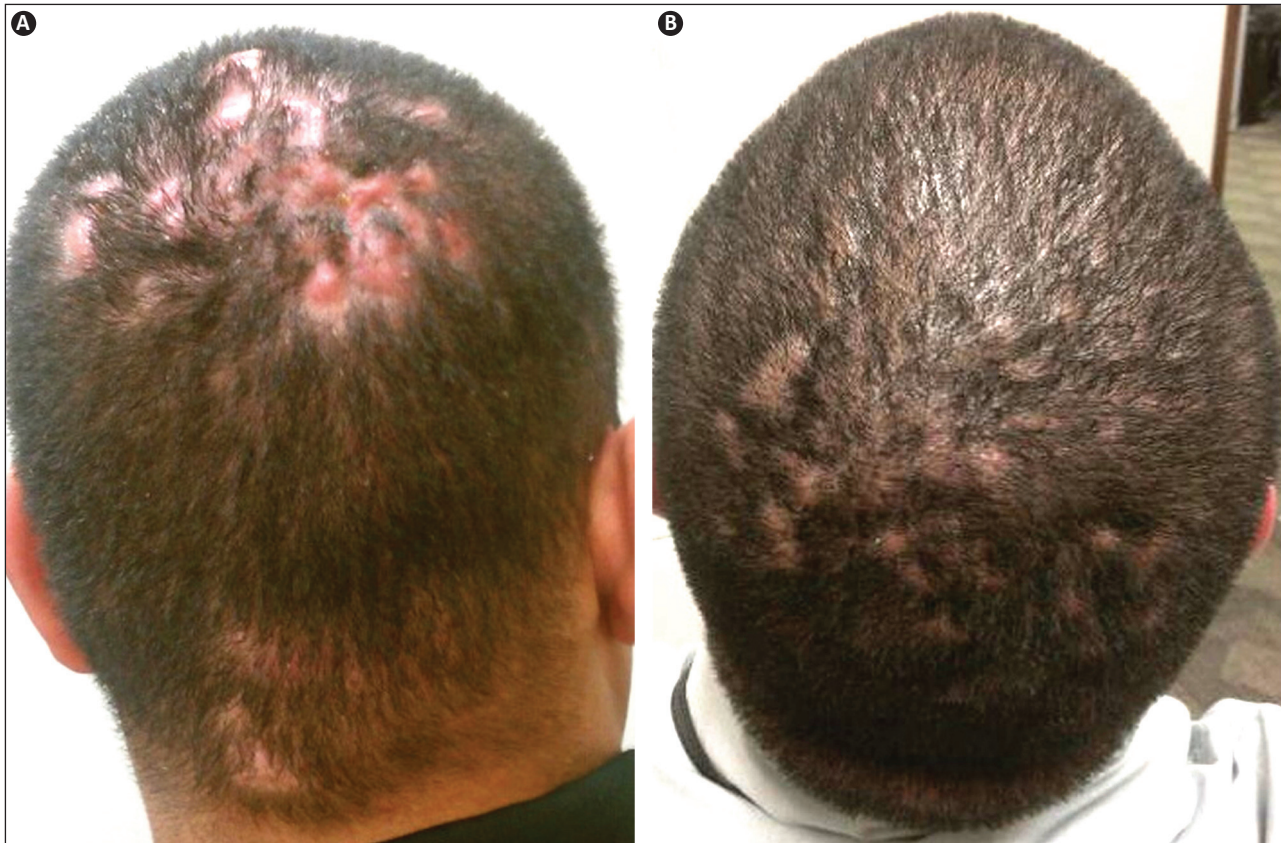
### Discussion

Encouraged by recent reports of successful treatment of hidradenitis suppurativa (HS) with TNF inhibitors, Sukhatme et. al. (11) first reported the use of adalimumab in a 39-year old male with refractory DCS. His condition also failed antibiotics, intralesional steroids, and oral isotretinoin. The condition then recurred after surgical excision. One month after starting adalimumab the patient experienced a significant reduction in suppuration and pain. After two months of therapy there was complete resolution of erythema and suppuration and by five months of therapy the patient achieved clearance with hair regrowth. More recently, Navarini et. al. (2) reported

\*Board Certified Dermatologist, Program Director of the University of Puerto Rico, Associate Professor of the University of Puerto Rico; †Board Certified Dermatologist, Private practice San Diego, California

*The authors have no conflicts of interest to disclose.*

Address correspondence to: Rafael F. Martín-García, MD, Department of Dermatology, University of Puerto Rico Medical Sciences Campus, PO BOX 365067, San Juan, PR 00936-5067. Email: rafaelfmartin@gmail.com



**Figure 1.** Refractory dissecting cellulitis. A, Before treatment: tender fluctuant nodules with overlying alopecia. B, After seven months of treatment.

the successful use of adalimumab in three young white male patients with disease duration ranging from one to seven years. All patients previously received different antibiotic courses and two patients received isotretinoin “without success” (2). All the patients experienced symptom improvement within eight weeks of therapy, and by three months there was effective reduction in both subjective symptoms and clinical activity. Histopathologic evaluation performed in two patients showed decreased inflammation during adalimumab treatment when compared with pre-treatment biopsies.

To the best of our knowledge, we report the fifth patient (first Hispanic/Puerto Rican) with DCS successfully managed with adalimumab. Our case is similar to previous reports. All were treated with similar doses of adalimumab and all experienced rapid subjective (4-8 weeks) and objective responses with major reduction in inflammation and/or clearance of lesions within three to seven months of therapy. As reported in patient three of Nevarini et. al. (2), we expect that discontinuation of adalimumab will result in recurrence of the disease. Similar to psoriasis, TNF inhibitors are not expected to cure DCS, and continued treatment will be necessary to maintain adequate responses. Although serious adverse events have never been reported in patients with DCS treated with TNF inhibitors, increased vigilance for infections and malignancies is recommended.

Studies evaluating the pathogenesis of DCS are notably absent in the literature but recently reported studies of HS may help to direct future research efforts. An increased expression of TNF-alpha in lesional and perilesional skin as reported in HS by Van der Zee et. al. (13), would explain the positive results obtained with TNF inhibitors. Studies should also explore possible alterations in the innate immune system, possible involvement of interleukin-1 $\beta$ , the inflammasome, and the role of the IL-23/Th-17 pathway in DCS as suggested in recent studies of HS (14-15).

In conclusion, we believe that reports on the successful and safe use of new or established medications for the treatment of DCS should be welcomed. Patients with this morbid and potentially disfiguring condition often present with uncontrollable, persistent, or recurrent disease despite receiving different medical and/or surgical therapies, associated with untoward medical or cosmetic side effects. As mentioned above, immunohistochemical and molecular studies should be undertaken to try to unfold the pathophysiologic mechanisms of DCS in order to directly target the associated processes and eventually discover a cure for the disease. Controlled studies should be performed to adequately evaluate the efficacy and safety of adalimumab in DCS. We recognize the economic burden associated with TNF inhibitor therapy and believe that it should be instituted only in carefully selected patients.

Based on the reports noted above from studies of HS, it would be interesting to investigate a possible role of ustekinumab and anakinra in the management of both diseases. For now, we believe that TNF inhibitors such as adalimumab represent a reasonably effective and safe therapeutic alternative for the treatment of patients with refractory DCS.

### Resumen

Celulitis disecante del cuero cabelludo es una enfermedad inflamatoria crónica poco común que en muchas ocasiones ocasiona alopecia cicatricial. Las terapias disponibles para esta condición potencialmente desfigurante solo brindan alivio temporero. Recientemente algunos reportes han destacado la efectividad de agentes inhibidores del factor de necrosis tumoral en esta enfermedad. Reportamos un paciente con celulitis disecante del cuero cabelludo manejado exitosamente con adalimumab.

### References

- Chicarilli Z. Follicular occlusion triad: hidradenitis suppurativa, acne conglobata, and dissecting cellulitis of the scalp. *Ann Plast Surg* 1987;18:230-237.
- Navarini AA, Trueb RM. 3 Cases of Dissecting Cellulitis of the Scalp Treated With Adalimumab. *Arch Dermatol* 2010;146:517-520.
- Greenblatt DT, Sheth N, Teixeira F. Dissecting cellulitis of the scalp responding to oral quinolones. *Clinical and Experimental Dermatology* 2007;33:97-110.
- Kobayashi H, Aiba S, Tagami H. Successful treatment of dissecting cellulitis and acne conglobata with oral zinc. *Br J Dermatol* 1999;141:1137-1138.
- Bjellerup M, Wallengren J. Familial perifolliculitis capitis abscedens et suffodiens in two brothers successfully treated with isotretinoin. *J Am Acad Dermatol* 1990;23:752-753.
- Bolz S, Jappe U, Hartschuh W. Successful treatment of perifolliculitis capitis abscedens et suffodiens with combined isotretinoin and dapsone. *J Dtsch Dermatol Ges* 2008;6:44-47.
- Bellew SG, Nemerofsky R, Schwartz RA, Granick MS. Successful treatment of recalcitrant dissecting cellulitis of the scalp with complete scalp excision and split-thickness skin graft. *Dermatol Surg* 2003;29:1068-1070.
- Campos VB, Dierickx CC, Farinelli WA, et al. Hair removal with an 800-nm pulsed diode laser. *J Am Acad Dermatol* 2000;43:442-447.
- Van Rappard DC, Limpens J, Mekkes JR. The off-label treatment of severe hidradenitis suppurativa with TNF- $\alpha$  inhibitors: a systematic review. *J Dermatolog Treat* 2013;24:392-404.
- Brandt HR, Malheiros AP, Teixeira MG, Machado MC. Perifolliculitis capitis abscedens et suffodiens successfully controlled with infliximab. *Br J Dermatol* 2008;159:506-507.
- Sukhatme SV, Lenzy YM, Gottlieb AB. Refractory dissecting cellulitis of the scalp treated with adalimumab. *J Drugs Dermatol* 2008;7:981-983.
- Wollina U, Gemmeke A, Koch A. Dissecting Cellulitis of the Scalp Responding to Intravenous Tumor Necrosis Factor-alpha Antagonist. *J Clin Aesthet Dermatol* 2012;5:36-39.
- Van der Zee HH, Laman JD, de Ruiter L, Dik WA, Prens EP. Adalimumab (antitumor necrosis factor- $\alpha$ ) treatment of hidradenitis suppurativa ameliorates skin inflammation: an in situ and ex vivo study. *Br J Dermatol* 2012;166:298-305.
- Schlapbach C, Hanni, Yawalkar N, Hunger RE. Expression of the IL-23/Th17 pathway in lesions of hidradenitis suppurativa. *J Am Acad Dermatol* 2011;65:790-798.
- Dreno B, Khammari A, Brocard A, Mayse D, et al. Hidradenitis Suppurativa: The Role of Deficient Cutaneous Innate Immunity. *Arch Dermatol* 2012;148:182-186.