

Mutilating Purpura Fulminans in an Adult with Meningococcal Sepsis

María Elena Arnáiz-García, MD*; Ana María Arnáiz-García, MD†; Francisco Gutiérrez-Diez, MD‡; Juan Francisco Nistal, PhD‡; Jose María González-Santos, PhD*; Ivana Pulitani, MD‡; Carlos Amado-Diago, MD§; Javier Arnáiz, MD¶

We report a dramatic case of meningococcal sepsis manifesting as purpura fulminans in an elderly diabetic woman. Hemodynamic instability and severe bilateral cutaneous lesions involving her hands and feet developed rapidly. Specific antibiotic therapy and the administration of inotropic and vasopressor drugs were initiated. The severity and extension of the cutaneous lesions (attributed to purpura fulminans) worsened because of the need for vasoconstrictors for the treatment of septic shock. Bilateral transmetatarsal and metacarpal amputations were required to stabilize the patient. [P R Health Sci J 2017;36:179-182]

Key words: Purpura, Fulminans, Meningococemia, Gangrene, Amputation

Case report

A 78-year-old diabetic woman was admitted to our institution presenting fever, diarrhea, vomiting, and abdominal pain. The patient reported the appearance of red and purplish macules over her lower extremities within last 4 hours. At the moment of admission, a physical examination revealed hypotension and tachycardia. Her fever increased and cutaneous lesions evolved to hemorrhages and ecchymosis in both hands and feet. She presented leukocytosis, thrombocytopenia, renal insufficiency, acidosis, and hypoxia. A low concentration of fibrinogen and prolonged partial thromboplastin time were also detected. Blood cultures and a lumbar puncture were done. Chest radiography showed pulmonary edema. Inotropic and vasopressor (noradrenaline and adrenaline) infusions were needed to support the patient. Gram-negative diplococci, later reported as *Neisseria meningitidis*, was isolated from blood and cerebrospinal fluid cultures. The presence of acute pustular eruption rapidly evolving to skin necrosis, suggested a complication known as purpura fulminans. A cefotaxime infusion was started, and the progressive remission of sepsis was observed. However, the cutaneous lesions in the extremities progressed to severe peripheral gangrene and necrosis (Figure 1). Bilateral transmetatarsal and transmetacarpal amputations were necessary to stabilize the patient (Figure 2). After the surgery, the patient recovered but required intense rehabilitation to improve her quality of life and regain her independence.

Discussion

Meningococcal septicemia results from *Neisseria meningitidis* infection and leads to the rapid development of severe septic shock. The population groups most affected are

neonates and young children. However, this condition is extremely uncommon in adults and is usually associated with complications and disastrous evolution (1).

The clinical presentation of meningococcal sepsis is variable for adults and children, and unfortunately it can be hard to recognize at first. The most typical pattern of symptoms consists of an apparently benign infection with nausea, diarrhea or vomiting, joint pain, and discomfort. The symptoms can appear in any order, but high fever is characteristic. Headache, drowsiness, difficulty awakening, or seizures, alone or in combination, can be present. A purpuric rash distributed along the extremities, with mucosal involvement, suggests meningococcal septicemia as the principal etiology. The characteristic cutaneous lesions presented in meningococcal sepsis consist of red to purple macules that do not blanch with pressure. The rash rapidly evolves to pustules, petechiae, and ecchymosis. Finding marks in such pale areas as the conjunctiva, palate, palms of the hands, and soles of the feet can be useful in doubtful cases or in patients with dark skin. The concurrence of these typical skin marks within hours, in association with shock syndrome, suggests this entity.

Purpura fulminans is the cutaneous clinical presentation of a hematological complication that includes tissue necrosis, small

*Department of Cardiovascular Surgery, University Hospital of Salamanca, Salamanca, Spain; †Department of Infectious Diseases, Marqués de Valdecilla University Hospital, Santander, Spain; ‡Department of Cardiovascular Surgery, Marqués de Valdecilla University Hospital, Santander, Spain; §Department of Pneumology, Marqués de Valdecilla University Hospital, Santander, Spain; ¶Department of Radiology, Aspetar-Orthopaedic and Sports Medicine Hospital, Al Buwairda St. Doha, Qatar

The author/s has/have no conflict/s of interest to disclose.

Address correspondence to: María Elena Arnáiz-García, MD, Department of Cardiovascular Surgery, University Hospital of Salamanca, Paseo de San Vicente 58-182, 37007, Salamanca, Spain. Email: elearnaiz@hotmail.com

vessel thrombosis, and disseminated intravascular coagulation (1–2). First, small red or purplish spots and ecchymosis appear along the extremities. In addition, vesicles and cutaneous bullae may emerge. These lesions are usually indurated, painful, and mainly extend symmetrically along the upper and lower extremities. Within hours, petechial rash spreads rapidly in extent and depth into full-thickness skin necrosis (1–2). Moreover, as occurs in the skin, the intravascular disseminated coagulation may progress rapidly to multi-organ failure caused by the systemic thrombotic occlusion of small- and medium-sized blood vessels. Laboratory tests reveal leukocytosis, thrombocytopenia, and disturbances in the coagulation system, such as the consumption of clotting factors.

In a large majority of cases, purpura fulminans manifests as a complication of an infectious process or as sepsis, mainly secondary to gram-negative organisms such as

Neisseria meningitidis. The clinical consequences of *Neisseria meningitidis* colonization and dissemination through the brain and peripheral microvessels are not only a result of the capacity of the survival and multiplication of meningococci in the bloodstream. Recent animal studies have contributed to a better understanding of the pathophysiological mechanisms of *Neisseria meningitidis*. The specific interaction of these mechanisms with endothelial cells can lead to a thrombotic syndrome, which, in severe form, can itself lead to a purpura fulminans. That is the reason that meningococcal infection can therefore be viewed as being an endothelial cell disease (3).

Neisseria meningitidis contains a polysaccharide capsule, which protects meningococci against the host immune system and from serum bactericidal activity. However, *Neisseria meningitidis* also expresses long filamentous appendages, called type IV pili, on its surface. In contrast, microvascular

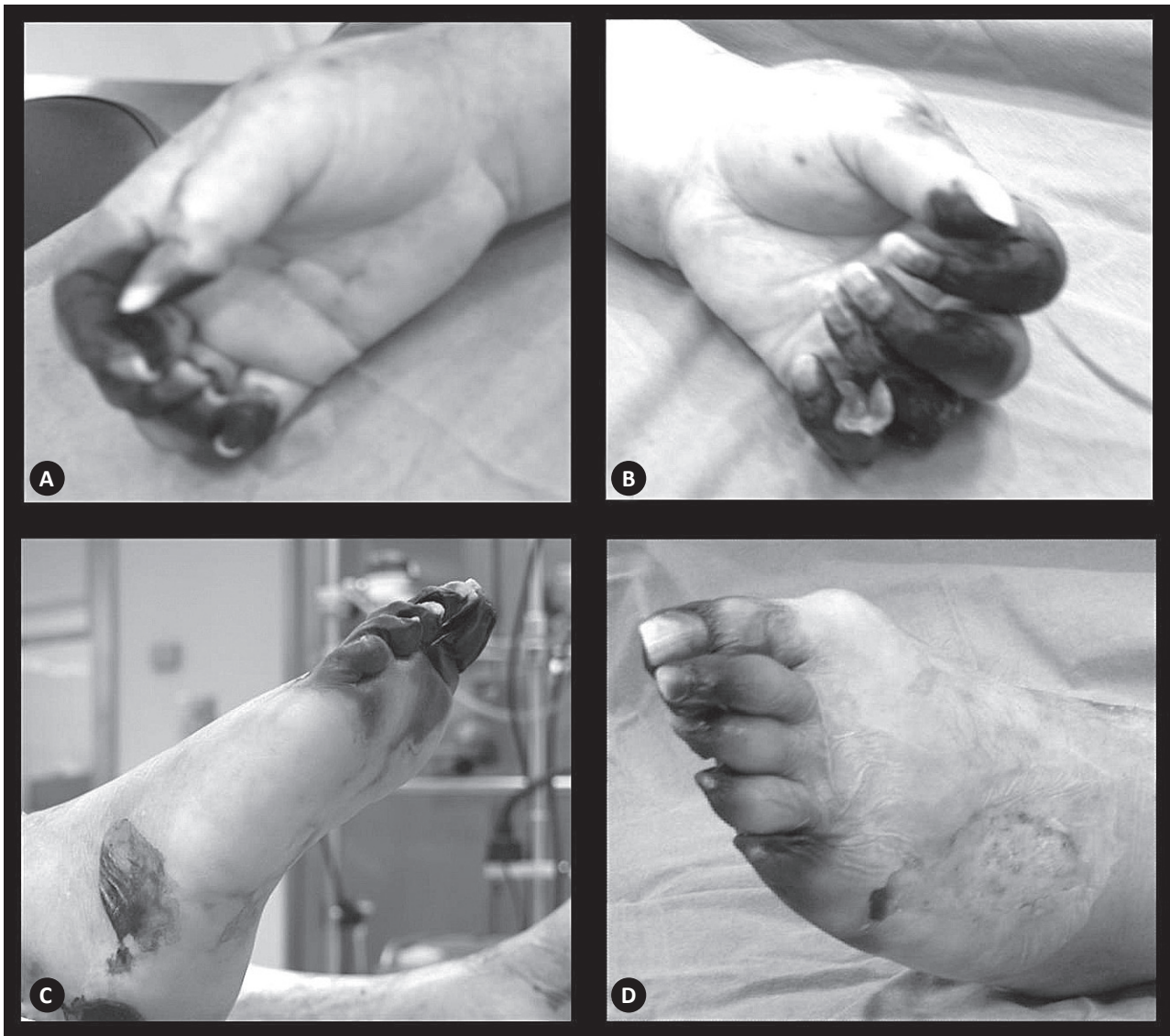

Figure 1. A. Necrotic lesions presented in all the digits of the right hand. B. Extensive necrotic lesions on the left hand. C. Necrotic lesions affecting the ankle, sole, and toes of the right foot. D. Necrosis lesion located on the left foot.

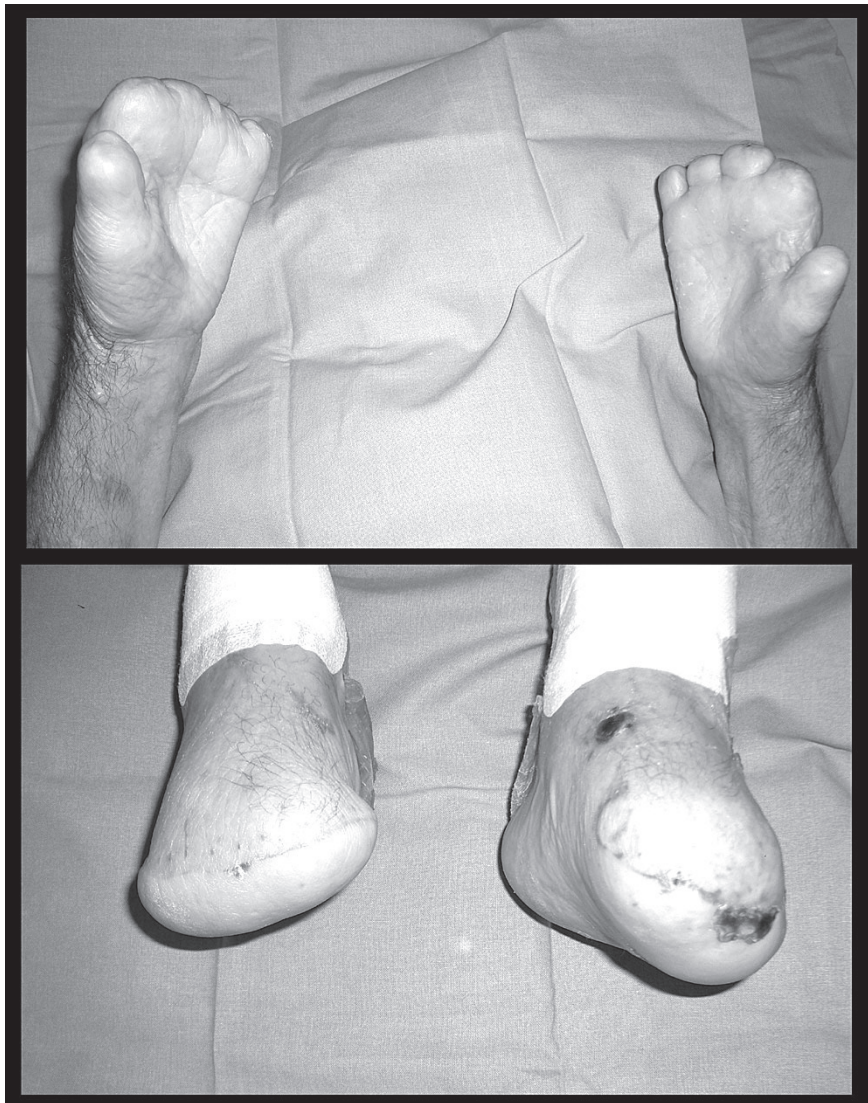


Figure 2. Transmetatarsal and transmetacarpal amputations. Postoperative results 1 month after surgery.

endothelial cells express 2 specific receptors for bacterial type IV pili (CD147 and the B2-adrenoceptor). These 2 cell projections facilitate the adhesion of diplococci to the endothelium and help meningococci to resist the shear stress and blood flow existing in capillaries and microvessels. This characteristic pilus-mediated interaction of *N. meningitidis* with the endothelial cells triggers multiple signaling events and activates transducing proteins that are responsible for the formation of microcolonies throughout the spleen, liver, kidney, brain, or cutaneous peripheral symptoms, and that are observed in invasive meningococcal disease (3).

However, purpura fulminans can also be associated with other bacterial or viral infections, such as *Staphylococcus aureus*, *Haemophilus influenzae*, streptococcus, rubella, varicella, *Escherichia coli*, *Enterobacter*, and others (2,4). Furthermore, an idiopathic form of purpura fulminans exists, and other inherited cases of purpura fulminans related to deficiencies of protein C, protein S, or several components of the coagulation system (5).

The differential diagnosis of purpura fulminans includes such uncommon etiologies as Henoch-Schönlein purpura, thrombotic thrombocytopenic purpura, drug-induced purpura, and post-infectious thrombocytopenic purpura. However, none of the previously mentioned vasculitic skin disorders affect the skin to such a severe degree (in terms of necrosis) as does purpura fulminans secondary to meningococcal sepsis (5).

It is well known that children or adults with certain chronic medical diseases or with any one of several conditions associated with immunosuppression (complement deficiencies, asplenia, HIV-infection, diabetes, tumors) and patients undergoing immunosuppressive treatment (such as corticoids or chemotherapy) have an increased risk for meningococcal disease. Our patient was elderly and diabetic, 2 risk factors that predispose like (elderly and diabetic) patients to infection and can lead to severe meningococcal sepsis (1,2,4-7).

Meningococemia is a life-threatening condition; a health practitioner confronting its symptoms in a patient must make a rapid diagnosis or risk the condition's becoming unmanageable. Timely treatment is essential to prevent complications and reduce mortality. A blood culture and a lumbar puncture with cerebrospinal

fluid analysis must be carried out, and the early initiation of antibiotic treatment is imperative (2,4).

The most important form of prevention is the administration of the vaccine against *Neisseria meningitidis*, which vaccine has sharply reduced the incidence of infection, worldwide. Different countries have different strains of the bacteria and therefore use different vaccines for different population groups. Routine primary immunization in adults is not required by the CDC (8). However, such immunization is recommended for persons with medical conditions or occupations that put them at risk. In this reported case, taking into account the age of patient and the immunosuppression associated with diabetes, the meningococcal vaccine would have been an acceptable way to prevent the infection.

Antibiotic therapy prevents severe illness and reduces its rapid diffusion to contacts and members of high-risk populations. Additionally, the appropriate management of septic shock

is needed. The use of heparin, hemofiltration, and activated protein-C has been proposed to reduce both mortality and the need for amputations (4). The management of septic shock includes fluid replacement and the administration of inotropic and vasopressor drugs to support the patient. However, vasoconstrictors are helpful but not always harmless. In our patient, an elderly woman with a previous history of diabetes and in whom, in all likelihood, a microvessel disease was present, the infusion of vasoconstrictor drugs to support the patient during shock could have caused the peripheral lesions to worsen. For this reason, in critically ill patients and in the presence of the pertinent risk factors, healthcare personnel should try to reduce the patient's exposure to these vasoconstrictors and monitor that patient closely for signs of inadequate skin perfusion (6–7).

In the presence of severe peripheral gangrene, surgical treatment and amputation are necessary but usually lead to mutilating sequelae (2,5–7).

Conclusion

Meningococcal sepsis is a potentially fatal disorder. The presence of fever, vomiting, and discomfort is typical, with these symptoms often mimicking a milder illness. Characteristic petechiae and symmetric rash should alert the practitioner of a hemorrhagic complication known as purpura fulminans. A rapid diagnosis and close vigilance are mandatory, especially in adults, because of the rareness of the disorder. Aggressive resuscitation, antibiotics, and volume expansion are essential. The severity and extension of the ecchymotic lesions of purpura fulminans can increase, caused by peripheral vasoconstriction secondary to any vasopressor drugs that may be used during shock, which was the case with this patient. The prompt excision of necrotic tissue or a fasciotomy may be indicated for survival. Prevention includes vaccination in children and adults and chemoprophylaxis for recent contacts.

Resumen

A continuación exponemos el caso de una paciente de edad avanzada que presentó una sepsis meningocócica manifestada como una púrpura fulminante. La aparición de lesiones cutáneas graves en ambas extremidades inferiores e inestabilidad hemodinámica asociada, hizo necesario el establecimiento de antibioterapia, drogas inotrópicas y vasopresores de forma inmediata con el fin de mantener estable hemodinámicamente a la paciente. La severidad y la extensión de las lesiones atribuidas a la púrpura fulminante se agravaron debido al efecto de los fármacos vasoconstrictores necesariamente utilizados durante el “shock” séptico. El rápido establecimiento de una gangrena periférica y simétrica grave obligó a realizar una amputación en ambas manos y pies.

References

- 1- Tamimi-Mariño I, Hidalgo JJ, Perez A, Mendez LI. Purpura fulminans: functional results in two paediatric patients after suffering multiple amputations [in Spanish]. *Rev Esp Cir Ortop Traumatol* 2012;56:319–322.
- 2- Agarwal MP, Sharma V. Clinical images: Purpura fulminans caused by meningococemia. *CMAJ* 2010;182:e18.
- 3- Coureuil M, Bourdoulous S, Marullo S, Nassif X. Invasive meningococcal disease: a disease of the endothelial cells. *Trends Mol Med* 2014;20:571–578.
- 4- Chalmers E, Cooper P, Forman K, et al. Purpura fulminans: recognition, diagnosis and management. *Arch Dis Child* 2011;96:1066–1071.
- 5- Smith OP, White B, Vaughan D, et al. Use of protein-C concentrate, heparin, and haemodiafiltration in meningococcus-induced purpura fulminans. *Lancet* 1997;350:1590–1593.
- 6- Cho AR, Kim JI, Kim EJ, Son SM. Skin necrosis after high dose vasopressor infusion in septic shock. *Korean J Crit Care Med* 2012;27:182–186.
- 7- Kim SM, Aikat S, Bailey A. Well recognized but still overlooked: norepinephrine extravasation. *BMJ Case Rep* 2012;2012. doi: 10.1136/bcr-2012-006836.
- 8- Centers for Disease Control. Recommended Immunization Schedules for Adults. Available at: [Url: https://www.cdc.gov/vaccines/schedules/hcp/adult.html](https://www.cdc.gov/vaccines/schedules/hcp/adult.html). February 2016.