REVIEW ARTICLE

Early Pathophysiological Alterations in Experimental Cardiomyopathy: the Syrian Cardiomyopathic Hamster

NELSON ESCOBALES, Ph D; MARÍA J. CRESPO, Ph D

The Syrian cardiomyopathic hamster (SCH) is an established animal model for genetic cardiomyopathy. The disease in the hamster develops through similar stages to those observed in humans with this condition. The pathophysiological basis for this condition in the hamster resides in an inherited mutation in the gene encoding for δ-sarcoglycan, a component of the dystrophin complex. Two basic mechanisms contribute to cardiomyopathy in this model: ischemic heart disease by vasospasms of the coronary circulation and cardiomyocyte loss due to intrinsic cell defects. This review focuses on the etiology of vascular dysfunction and its role in the development of heart failure (HF) in this animal model. The data presented suggest that the vascular renin-angiotensin-system (RAS) plays a critical role in the generation of increased coronary reactivity and resistance in young SCH that have not yet developed the clinical manifestations of HF. The increased reactivity of the coronary vasculature results from endothelial dysfunction secondary to Ang II-dependent, oxidative stress. These alterations favor the development of ischemic heart disease and cardiomyopathy in adult animals. Indeed, RAS blockade during early stages of the disease significantly improves the clinical signs of dilated cardiomyopathy in this experimental model. These findings have significant implications for the prevention and treatment of cardiomyopathy in patients with ischemic heart disease, in particular, to those with familial sarcoglycanopathies.

Key words: Syrian cardiomyopathic hamsters, Nitric oxide, Endothelial dysfunction, Coronary circulation, Vascular RAS

Heart failure (HF) is a pathophysiologic state in which the capacity of the heart to pump blood is decreased, leading to a mismatch between cardiac output and the metabolic demands of tissues. As a result, fatigue, generalized vasoconstriction, fluid retention and in severe cases, lung edema develops. The condition results mainly from end stage hypertensive disease, coronary dysfunction and valvular disease. HF is a major health problem in the world today, affecting approximately 1% of the population (1), and its incidence appears to be increasing, despite improvements in mortality rates from predisposing conditions (2). Heart failure leads to greatly increased morbidity and mortality among cardiac patients, with a prognosis little better than cancer (3-4). In the USA, heart failure affects about 2% of the total adult population, and contributes to more than 250,000 deaths per year (5). Therefore, there is a need for studies at the clinical and basic level to develop new therapeutic strategies for the treatment and prevention of this disease.

Department of Physiology, University of Puerto Rico-School of Medicine, PO Box 365067 San Juan, Puerto Rico 00936-5067.

Address correspondence to: N. Escobales, Ph D, Department of Physiology, University of Puerto Rico-School of Medicine, PO Box 365067, San Juan, Puerto Rico 00936-5067. E-mail: nescobales@rcm.upr.edu

The Syrian cardiomyopathic hamster as a model to study HF

The Syrian cardiomyopathic hamster model represents a well-documented (6-11) hereditary cardiomyopathy that is described by the following sequential stages: (*A*) immaturity (<30 days after birth), (*B*) acute focal myolysis of the myocardium (30-60 days), (*C*) fibrosis and calcification of necrotic patches (60-90 days), (*D*) ventricular hypertrophy (BIO 14.6 strain) or dilation (BIO-TO2 strain) from 90-150 days and, (*E*) congestive heart failure (>150 days). The terminal phase begins at about 10 months of age. Therefore, the development of HF in this animal shares many similarities with the progression of the disease in humans. In addition, the acute myocarditis observed in patients who later developed cardiomyopathy has histological similarities to the myocardial changes observed during the development of cardiomyopathy in hamsters (12). Cardiomyocyte abnormalities related to calcium overload, SR Ca^{2+}-channels, genetic defects of membrane structures and functions (13), alterations in β-adrenergic receptors (14), microvascular spasms (15-17), electrophysiological abnormalities (18), and oxidative stress (14, 19-21) are known contributing factors to the development of the disease in this animal model. In recent years, a role for the dystrophin-sarcoglycan

complex (22-25) in the etiology of cardiomyopathy in the hamster has been described. Indeed, a genomic deletion of the 5' region of the δ-sarcoglycan gene is responsible for the cardiomyopathy in the BIO-TO2 (22, 26). Deficiency of δ-sarcoglycan disrupts the dystrophin-associated glycoprotein complex in the plasma membrane of cardiomyocytes, leading to a loss of structural membrane integrity and susceptibility to mechanical damage during the contraction-relaxation cycle. The relevance of the dystrophin-glycoprotein complex in cardiomyopathy has been demonstrated in mouse models of sarcoglycanopathies, in which mutations in the β, δ, or γ sarcoglycan genes produce both muscular dystrophy and dilated cardiomyopathy that reproduce the phenotype of the BIO-TO2 strain. Accordingly, re-expression of the δ-sarcoglycan gene in null SCH, reduces cardiac and skeletal muscle injury and augments life-span (27), confirming the relevance of this gene to the pathophysiology of the disease. It is worth noting that mutations in the δ-sarcoglycan gene have been also reported in patients with idiopathic dilated cardiomyopathy and limb-girdle muscular dystrophy-2F (28-31). The similarities between the disease in the hamster and that in humans make SCH an excellent animal model to study the pathophysiology of the disease and to evaluate new therapeutic strategies.

Coronary spasms occur early during the necrotic phase of cardiomyopathy in SCH

Factor and colleagues (32) were the first to suggest that the infart-like pattern of necrosis (discrete patches) that takes place early in the development of dilated cardiomyopathy in SCH originates from transient coronary vasospasms that cause ischemia with reperfusion injury and focal myolysis. This fact has been long recognized in humans as a critical event in ischemic heart disease (33). Indeed, the calcium channel antagonist and vasodilator verapamil, prevents the occurrence of coronary vasospasms and the histological and functional alterations of the heart in various animal models of cardiomyopathy (15-17, 23, 32, 34). However, due to the fact that verapamil affects voltage-dependent, L-type calcium channels in both vascular smooth muscle (VSM) and cardiomyocytes (35), controversy exists as to whether vasospasms in SCH originate from primary alterations in the vascular wall or from secondary alterations to cardiomyocyte damage. Evidence for a primary role of VSM came from targeted ablation of δ-sarcoglycan gene in mice that leads to disruption of the sarcoglycan complex in VSM cells, together with cardiomyopathy and focal necrosis (36). In mice showing ablation of the α-sarcoglycan gene, which only affects cardiac and skeletal muscle sarcoglycan complex, neither cardiomyopathy or focal necrosis were present. Further evidence for a primary role of VSM δ-sarcoglycan in coronary spasms and cardiomyopathy comes from comparative studies on the effects of verapamil on δ-sarcoglycan-deficient mice and the dystrophin-deficient *mdx* mice (23). Verapamil was effective in ameliorating the cardiomyopathic phenotype in δ-sarcoglycan-deficient mice which demonstrates vascular dysfunction and cardiomyocyte necrosis. No beneficial effect of the calcium antagonist was observed in the dystrophin-deficient *mdx* mice, which showed cardiomyopathy without perturbations of the VSM sarcoglycan complex, or any other vascular dysfunction. These findings have been interpreted to indicate that mutations in the δ-sarcoglycan gene make cardiomyocytes prone to damage by intermittent ischemic events from transient coronary spasms (23). However, recent evidence (34, 37) in γ-sarcoglycan mutant mice model that develop cardiomyopathy with focal degeneration similarly to the hamster, supports the idea that spasms of coronary arteries are derived from a VSM cell extrinsic process (secondary in origin). γ-Sarcoglycan mutant mice with cardiomyocyte perturbations, demonstrate coronary artery vasospasms despite normal sarcoglycan complex in VSM. This finding illustrates that a primary defect in the VSM sarcoglycan complex is not required for the development of spasms and cardiomyopathy. In the γ-sarcoglycan mutant, verapamil reduces vasospasms and ameliorates the progression of the disease (34). These studies with transgenic mice provide support for a VSM cell involvement (vasospasms) secondary to cardiomyocyte damage. However, the δ-sarcoglycan downstream cellular mechanisms leading to vasospasms in SCH have not been established.

Coronary spasms could result from Ang II-induced endothelial dysfunction and hypercontractility of the vascular wall

Studies conducted by our research group (21, 38-40) with the aorta from the BIO-TO2 strain have revealed a significant number of alterations in vascular function in young (2-month-old) animals. These alterations include among others, endothelial dysfunction, increased contractile response to Ang II (38), enhanced vascular ACE activity (39), and enhanced ^{125}I-Ang II binding capacity (40). In addition, we have reported increased Ang II-dependent, NAD(P)H oxidase-dependent, superoxide generation in aortic tissue, and elevated systolic blood pressure (21). Losartan, an AT-1 receptor blocker, abolished the increased oxidase activity and superoxide generation, together with the elevated blood pressure (21). Similar findings were observed following treatment

of animals with the antioxidant *N*-acetylcysteine (NAC). We have also found hyperreactivity to thromboxane (Figure 1A) and impaired bradykinin-dependent relaxation in the coronary circulation of young SCH (Figure 1B). Both of these abnormalities were reversed by treatment with losartan and NAC (unpublished data), demonstrating that Ang II-dependent oxidative stress plays a role in generating endothelial dysfunction in the coronary circulation. These observations in the aorta and coronary vasculature of SCH point to a primary role of local RAS in the development of vascular dysfunction in the initial phases of HF in this animal model. Indeed, the vascular alterations were observed in animals with normal echocardiographic parameters, Heart/BW ratios, and heart rate determinations (21). These findings indicate that heart function is still normal at this early age (2-month-old), despite focal, histological abnormalities present in the heart, and the functional alterations present in the vasculature. The abnormalities present in the vasculature of young hamsters must be distinguished from the vascular dysfunction (systemic and coronary) that characterize patients and animals with overt heart failure, and which are secondary to various neurohumoral compensatory mechanisms aimed at maintaining peripheral vascular tone and tissue perfusion (41-43). Indeed, SCH with overt HF demonstrates impaired nitric oxide (NO) downstream signaling (44), increased aortic and mesenteric artery reactivity (45), and reduced basal coronary perfusion (46-48).

The endothelial dysfunction present in the vasculature of SCH could result from impaired NO or EDHF-dependent activation of $K_{Ca^{2+}}$ and K_{ATP} channels (49-51). In Golden Syrian hamsters (normal hamsters), both basal and acetylcholine-mediated coronary relaxation depend on K^+ channels (52), and there is evidence for inhibition of these structures by reactive oxygen species (ROS) (53-54). ROS has been implied in endothelial dysfunction in isolated coronary arteries from SCH (55). In the transgenic mouse model of dilated cardiomyopathy (Tgalphaq*44 mice), endothelial dysfunction in coronary circulation is associated with excessive ROS generation by cardiac NAD(P)H oxidase (56).

Vascular wall hypercontraction could involve Rho-kinase-dependent inhibition of myosin phosphatase which plays a central role in agonist-induced Ca^{2+} sensitization and hypercontraction of VSM cells (57). It is worth noting that Rho-kinase is involved in the stimulation of NAD(P)H oxidase and endothelial dysfunction that follows long-term treatment of rats with Ang II (58). Therefore, augmented Ang II in the coronary vasculature of SCH could precipitate spasms by inducing endothelial dysfunction and by promoting hypercontraction of the vascular wall. There is one report in rhesus monkeys that acute intracoronary administration of Ang II does not induce spasms (59). To our knowledge similar experiments in humans or in SCH are not available. It is possible that in the setting of endothelial dysfunction, vasospasms are triggered

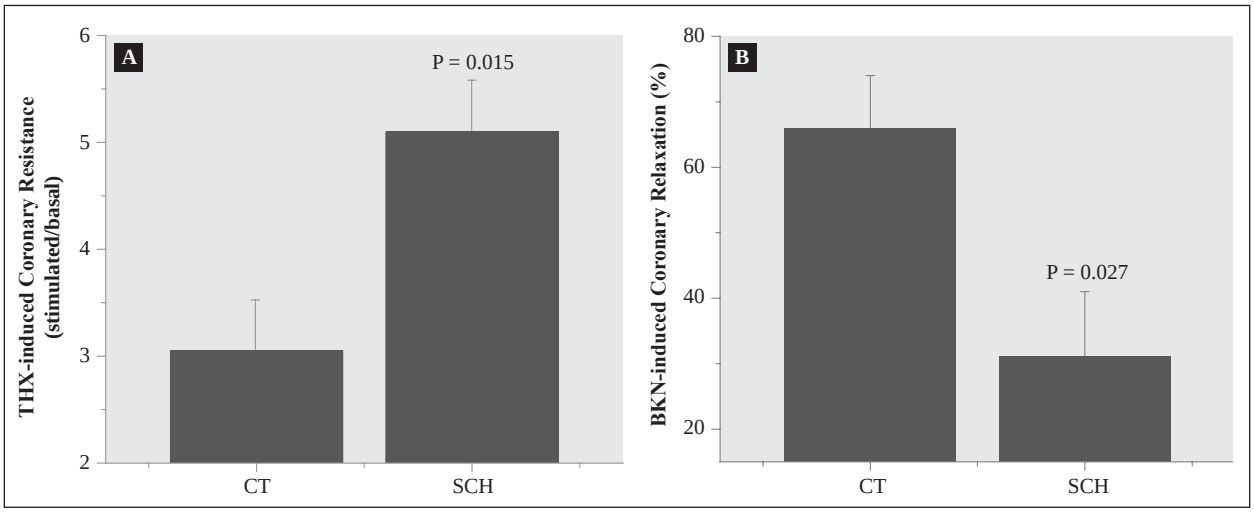

Figure 1. Coronary Hemodynamics in Control (CT) and Cardiomyopathic (SCH) hamsters. The results shown represent the mean ±SEM of 8 hearts per group. Coronary resistance was determined from coronary flow and pressure determinations using a Langendorff heart preparation. Thromboxane (THX) and bradykinin (BKN) were infused into the coronary circulation at 0.1 and 10 µM, respectively. Panel A illustrates the THX-induced increase in coronary resistance in 2-month-old CT and SCH, and panel B the BKN-induced coronary relaxation in THX-precontracted coronaries.

by chronic exposure to Ang II. The latter, however, has not been established.

Vascular angiotensin-converting-enzyme (ACE) activity upregulation in 2-month-old SCH

Our findings indicate that increased vascular ACE activity in young SCH takes place at a critical stage, when early manifestations of cardiomyocyte deterioration are developing. ACE upregulation is neither observed in the heart and plasma of SCH at 2 months (39, 60-61), nor in the aorta from younger (1 month-old, unpublished data) or older (>6 month-old) animals (39). The temporal upregulation of vascular ACE correlates with the release of cardiac troponin-T at 8 weeks of age (62), supporting the notion that cardiac myolisis takes place at a time where RAS is upregulated and there is enhanced responsiveness of the vasculature to Ang II. We believe that our observations concerning ACE upregulation in the aorta are extensive to coronary arteries because Ang II-dependent, endothelial dysfunction and hyper-reactivity to contractlile agonists, are present in both of these structures during the necrotic phase in SCH. In pig's coronary arteries, Ang II induces vasoconstriction, through an AT-1 receptor that elicits superoxide production, impairs NO generation, and inhibits endothelium-dependent relaxation (63). Therefore, vascular ACE upregulation could play a key role in the etiology of coronary dysfunction in young SCH.

Vascular ACE in young SCH could be upregulated by reduced NO bioavailability

ACE is a key component of RAS that converts Ang I to Ang II, and degrades bradykinin. Its activity and/or mRNA expression in the vascular wall has been used as an index of RAS activation in various experimental models (64-66). ACE upregulation in the perivascular area of coronary vasculature in mice correlates with cardiac superoxide production and the formation of microvascular lesions, and both of these alterations are sensitive to blockade with temocapril, (ACE inhibitor) or olmesartan, an AT-1 receptor blocker (68-69). We believe that vascular ACE upregulation in young SCH could be secondary to oxidative stress and/or nitric oxide synthase inhibition, both of which diminish NO bioavailability (70). Indeed, chronic administration of N^{ω}-nitro-L-arginine methyl ester (L-NAME) or asymmetric dimethyl arginine (ADMA), inhibitors of NO synthase, increases arterial ACE activity in rats (71-72) and hamsters (Figure 2A) and in coronary arteries of rats and mice (68-69, 73). By contrast, SNP (an NO releaser) inhibits ACE activity in the aorta of the hamster (Figure 2B). High ADMA levels are associated with ACE upregulation and secondary pathological alterations in coronary and cardiac tissues in mice (74). These effects were not observed in transgenic mice overexpressing dimethylarginine dimethylaminohydrolase-2, the enzyme responsible for ADMA degradation. The regulation of ACE expression

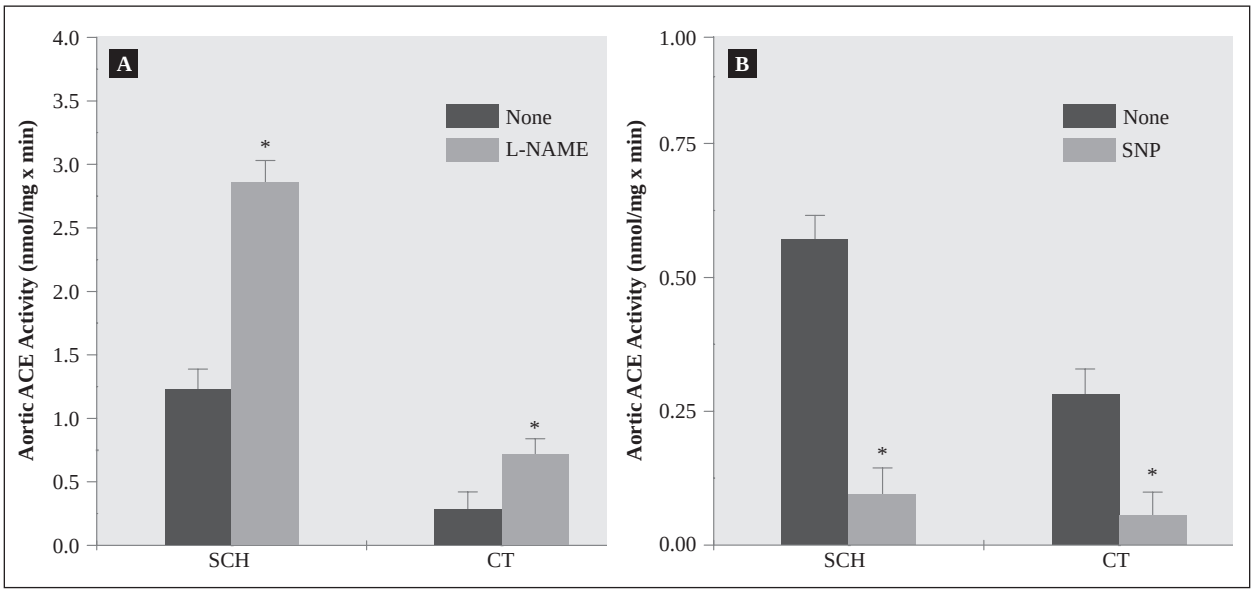

Figure 2. Effect of L-NAME on vascular ACE activity in 2-month-old CT and SCH. Aortic tissue homogenates were treated with L-NAME 1 mM (Panel A) or SNP 1 μM (Panel B) for 6 hours, after which ACE activity was determined using fluorometric assay (Cushman DW, Cheung HS. Biochem Biophys Acta 1991;250:261-265). The values shown are the means ± SEM of 8 experiments. (*): P<0.05 when compared with untreated group.

appears to be mediated by p38 MAPK (74), a kinase that could be modulated by the NO-cGMP/PkG cascade (75-76). p38 MAPK is also a redox-sensitive target and has been implicated in cardiovascular pathology (77-78). It has been proposed that ADMA regulates p38 MAPK independently of NO, because ACE activation is observed in eNOS-KO mice (68-69). Nevertheless, our studies with SNP (Figure 2 B) support the contention that NO regulates ACE expression and/or activity. Therefore, alterations that reduce NO should promote p38 MAPK-dependent ACE activity and hence, vascular RAS upregulation.

Clinical significance of vascular RAS-upregulation and dysfunction to HF

Vascular RAS upregulation could accelerate the development and progression of HF by its effect on coronary hyper reactivity. One of the hallmarks of HF is an early endothelium-dependent (ED) dilation of the coronary circulation that compensates for an increased cardiac workload (43). If the vascular wall is hyper reactive by tissue RAS upregulation, the ED dilation of the coronary circulation may be impaired, leading to cardiac decompensation. Indeed, in patients with cardiomyopathy, the degree of coronary microvascular dysfunction is an independent predictor of cardiac events, increased progression of heart failure and relative risks of death (79).

Early therapeutic intervention in dilated cardiomyopathy

The data presented here supports the idea that the development of cardiomyopathy in the hamster, involves early vascular RAS upregulation. This phenomenon could induce hyper reactivity of the vascular wall and coronary vasospasms that are considered fundamental in the development of dilated cardiomyopathy. To evaluate the early involvement of RAS in the development of cardiomyopathy in the hamster, we examined (80) whether a combination of enalapril (25 mg/kg/day) and losartan (10 mg/kg/day) administered from 1 to 5 months of age protects against the development of dilated cardiomyopathy. Indeed, RAS blockade in SCH significantly improved cardiac output index 53%, left-ventricular-end diastolic volume 30% and left-ventricular-end-systolic volume (LVESV) by 62%, and increased ejection fraction by 48% ($P<0.05$). By contrast, treatment with the β-blocker carvedilol (1 mg/kg/day) for the same period of time only reduced LVESV by 28% and increased EF by 15%. These results indicate that RAS plays a fundamental role in early stages of dilated cardiomyopathy in SCH, to the extent that a combination of enalapril and losartan is more effective than carvedilol in reducing the development of the disease, despite the hypotensive effect of the adrenergic antagonist. These studies could be criticized on the basis of the timing of drug administration (pre-heart failure stage), combined drug treatment vs. monotherapy, and doses used. Nevertheless, they have significant therapeutic implications when extrapolated to patients prone to cardiomyopathy. In particular, they suggest that early blockade of RAS could be beneficial in subjects with familial sarcoglycanopathies, or with ischemic cardiomyopathy even in the absence of manifested heart disease. Further studies are necessary to confirm the link between vascular RAS and coronary spasms in ischemic heart disease.

Conclusions

We hypothesize that upregulation of vascular RAS with its secondary oxidative stress leads to dysfunction of coronary vasculature (Diagram 1) promoting vasospasms early in the life of these animals. These alterations could facilitate the appearance of lesions in the myocardium by inducing transient ischemic events that affect susceptible cardiomyocytes. Once ACE is upregulated, a positive feedback cycle comes into play by the reduction in NO bioavailability due to activation of vascular NAD(P) H oxidase by Ang II. We can only speculate that ACE upregulation in the early stages of the disease in SCH, could result from alterations in NO bioavailability and/or ROS generation secondary to the δ-sarcoglycan genetic abnormalility of the hamster.

Resumen

El hámster cardiomiopático sirio (SCH) es un modelo animal establecido de cardiomiopatía genética. La enfermedad se desarrolla en el hámster a través de etapas similares a las que se observan en pacientes con esta condición. Las bases patofisiológicas para el desarrollo del fallo cardiaco en el hámster radican en una mutación heredada en el gen que codifica para el δ-sarcoglicano, que es un componente del complejo de distrofina. Existen dos mecanismos básicos que contribuyen al desarrollo de la cardiomiopatía en este modelo: la enfermedad isquémica causada por vasospasmos de la circulación coronaria, y la pérdida de cardiomiocitos debido a defectos intrínsecos. Esta revisión de literatura está enfocada en la etiología de la disfunción vascular y su posible rol en el desarrollo de fallo cardiaco en este modelo animal. Los resultados presentados sugieren que el sistema renina-angiotensina (RAS) vascular juega un papel crítico en el aumento de la reactividad y la resistencia coronaria observada en SCH jóvenes que aun no presentan las manifestaciones clínicas del fallo cardiaco. La reactividad aumentada de la vasculatura coronaria surge

como consecuencia de la disfunción endotelial secundaria al estrés oxidativo dependiente de angiotensina II. Estas condiciones favorecen el desarrollo de la enfermedad isquémica y la cardiomiopatía en animales adultos. De hecho, el bloqueo del RAS en una etapa temprana del desarrollo de la condición, mejora significativamente los síntomas clínicos de la cardiomiopatía dilatada en este modelo experimental. Estos hallazgos tienen implicaciones significativas en la prevención y tratamiento de la cardiomiopatía en pacientes con enfermedad isquémica, y en particular, en aquellos con sarcoglicanopatia familiar.

Acknowledgements

The work presented in this article was supported in part by grants from the NIH SCORE Program (NIH 2 S06-GM-08224).

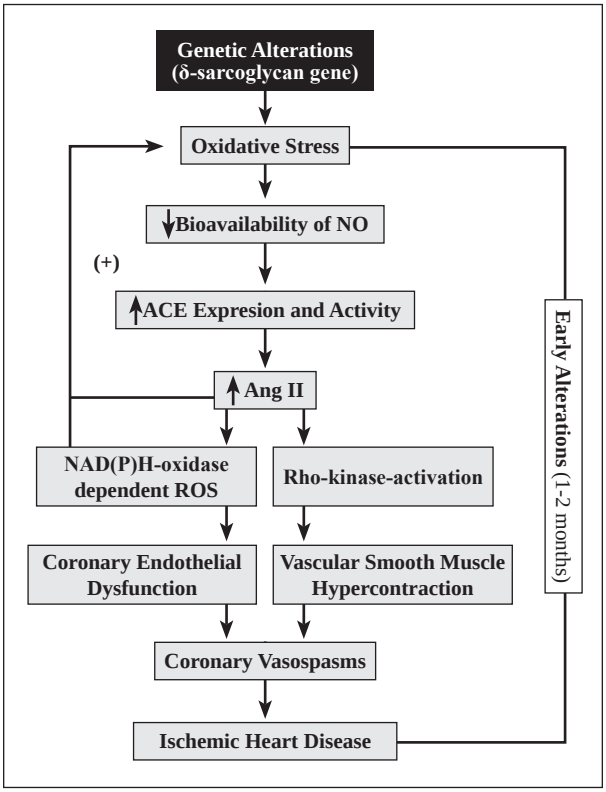

Diagram 1. We propose that oxidative stress decreases the bioavailability of NO in coronary vessels (Early Alterations), leading to vascular ACE upregulation and high levels of Ang II in tissues. These actions induce a self-sustaining cycle that promotes oxidative stress by stimulating NAD(P) H oxidase activity. Increased superoxide anions aggravate NO bioavailability at the vascular wall and together with the activation of Rho-kinase by Ang II, impair endothelial function, leading to coronary vasospasms and ischemic lesions in the heart of young Syrian Cardiomyopathic hamsters.

References

1. Kannel WB, Ho K, Thom T. Changing epidemiological features of cardiac failure. Br Heart J 1994;72:S3-S9.
2. Kannel WB. Incidence and Epidemiology of Heart Failure. Heart Fail Rev 2000;5:167-173.
3. Francis GS, Goldsmith SR, Levine TB, Olivari MT, Cohn JN. The neurohumoral axis in congestive heart failure. Ann Intern Med 1984;101:370-377.
4. Trupp RJ, Abraham WT, Lamba S. Future therapies for heart failure. Crit Care Nurs Clin North Am 2003;15:525-530.
5. Ho KK, Pinsky JL, Kannel WB, Levy D. The epidemiology of heart failure: the Framingham Study. J Am Coll Cardiol 1993;22(4 Suppl A):6A-13A.
6. Gertz EW. Cardiomyopathic Syrian hamster: A possible model of human disease. Prog Exp Tumor Res 1972;16:242-260.
7. Forman R, Parmley WW, Sonneblick EH. Myocardial contractility in relation to hypertrophy and failure in myopathic Syrian hamster. J Mol Cell Cardiol 1972;4:203-211.
8. Strobeck JE, Factor SM, Bhan A, Sole M, Liew CC, Fein F, Sonnenblick EH. Hereditary and acquired cardiomyopathies in experimental animals; mechanical, biochemical and structural features. Ann NY Acad Sci 1979;317:58-88.
9. Chien KR. Stress Pathways and Heart Failure 1999;98:555-558.
10. Kawada T, Nakatsuru Y, Sakamoto A, Koizumi T, Shin WS, Okai-Matsuo Y, Suzuki J, Uehara Y, Nakazawa M, Sato H, Ishikawa T, Toyo-oka T. Strain- and age-dependent loss of sarcoglycan complex in Cardiomyopathic hamster hearts and its re-expression by delta-sarcoglycan gene transfer in vivo. FEBS Lett 1999;458:405-408.
11. Kawada T, Nakazawa M, Nakauchi S, Yamazaki K, Shimamoto R, Urabe M, Nakata J, Hemmi C, Masui F, Nakajima T, Suzuki J, Monahan J, Sato H, Masaki T, Ozawa K, Toyo-Oka T. Rescue of hereditary form of dilated cardiomyopathy by rAAV-mediated somatic gene therapy: amelioration of morphological findings, sarcolemmal permeability, cardiac performances, and the prognosis of TO-2 hamsters. Proc Natl Acad Sci U S A 2002;99:901-906.
12. Strain JE, Grose RM, Factor SM. Results of endomyocardial biopsy in patients with spontaneous ventricular tachycardia but without apparent structural heart disease. Circulation 1983;68: 1171-1181.
13. Ikeda Y, Martone M, Gu Y, Hoshijima M, Thor A, Oh SS, Peterson KL, Ross J. Altered membrane proteins and permeability correlate with cardiac dysfunction in cardiomyopathic hamsters. Am J Physiol Heart Circ Physiol 2000;278:H1362-H1370.
14. Nishizawa T, Iwase M, Kanazawa H, Ichihara S, Ichihara G, Nagata K, Obata K,Kitaichi K, Yokoi T, Watanabe M, Tsunematsu T, Ishikawa Y, Murohara T, Yokota M. Serial alterations of beta-adrenergic signaling in dilated Cardiomyopathic hamsters: possible role of myocardial oxidative stress. Circ J 2004;68:1051-1060.
15. Rouleau JL, Chuck LHS, Hollosi G, Kidd P, Sievers RE, Wikman-Coffelt J, Parmley WW. Verapamil preserves myocardial contractility in the hereditary cardiomyopathy of the hamster. Circ Res 1982;50:405-412.
16. Sonnenblick EH, Fein F, Capasso JM, Factor SM. Microvascular spasm as a cause of cardiomyopathies and the calcium blocking-agent verapamil as potential primary therapy. Am J Cardiol 1985;55:179B-184B.
17. Ueyama T, Ohkusa T, Hisamatsu Y, Nakamura Y, Yamamoto T, Yano M, Matsuzaki M. Alterations in cardiac SR $Ca2^{+}$ -release channels during development of heart failure in cardiomyopathic hamsters Am J Physiol 1998;274:H1-H7.
18. De Mello WC, Crespo MJ. Correlation between changes in morphology, electrical properties and angiotensin converting enzyme activity in the failing heart. Eur J Pharmacol 1999;378:187-194.

19. Fukuchi T, Kobayashi A, Kaneko M, Ichiyama A, Yamazaki N. Possible involvement of free radicals and antioxidants in the early stages of the development of cardiomyopathy in BIO 14.6 Syrian hamster. Jpn Heart J 1991;32:655-666.
20. Gutiérrez JA, Clark SG, Giulumian AD, Fuchs LC. Superoxide anions contribute to impaired regulation of blood pressure by nitric oxide during the development of cardiomyopathy. J Pharmacol Exp Ther 1997;282:1643-1649.
21. Escobales N, Crespo MJ. Angiotensin II-dependent Vascular Alterations in Young Cardiomyopathic Hamsters: Role of Oxidative Stress. Vasc Pharmacol 2006;44:22-28.
22. Sakamoto A, Ono K, Abe M, Jasmin G, Eki T, Murakami Y, Masaki T, Toyo-oka T, Hanaoka F. Both hypertrophic and dilated cardiomyopathies are caused by mutation of the same gene, delta-sarcoglycan, in hamster: an animal model of disrupted dystrophin-associated glycoprotein complex. Proc Natl Acad Sci U S A 1997;94:13873-13878.
23. Cohn RD, Durbeej M, Moore SA, Coral-Vázquez R, Prouty S, Campbell KP. Prevention of cardiomyopathy in mouse models lacking the smooth muscle sarcoglycan-sarcospan complex. J Clin Invest 2001;107:R1-R7.
24. McNally E, Allikian M, Wheeler MT, Mislow JM, Heydemann A. Cytoskeletal defects in cardiomyopathy. J Mol Cell Cardiol 2003;35:231-241.
25. Lapidos KA, Kakkar R, McNally EM. The dystrophin glycoprotein complex. Signaling strength and integrity for the sarcolemma. Circ Res 2004;94:1023-1031.
26. Sakamoto A. Electrical and ionic abnormalities in the heart of Cardiomyopathic hamsters: In quest of a new paradigm for cardiac failure and lethal arrhythmia. Mol Cell Biochem 2004;259: 183-187.
27. Zhu T, Zhou L, Mori S, Wang Z, McTiernan CF, Qiao C, Chen C, Wang DW, Li J, Xiao X. Sustained whole-body functional rescue in congestive heart failure and muscular dystrophy hamsters by systemic gene transfer. Circulation 2005;112:2650-2659.
28. Nigro V, de Sá Moreira E, Piluso G, Vainzof M, Belsito A, Politano L, Puca AA, Passos-Bueno MR, Zatz M. Autosomal recessive limb-girdle muscular dystrophy, LGMD2F, is caused by a mutation in the delta-sarcoglycan gene. Nat Genet 1996;14:195-198.
29. Tsubata S, Bowles KR, Vatta M, Zintz C, Titus J, Muhonen L, Bowles NE, Towbin JA. Mutations in the human delta-sarcoglycan gene in familial and sporadic dilated cardiomyopathy. J Clin Invest 2000;106:655-662.
30. Politano L, Nigro V, Passamano L, Petretta V, Comi LI, Papparella S, Nigro G, Rambaldi PF, Raia P, Pini A, Mora M, Giugliano MA, Esposito MG, Nigro G. Evaluation of cardiac and respiratory involvement in sarcoglycanopathies. Neuromuscul Disord 2001;11: 178-185.
31. Moore SA, Shilling CJ, Westra S, Wall C, Wicklund MP, Stolle C, Brown CA, Michele DE, Piccolo F, Winder TL, Stence A, Barresi R, King N, King W, Florence J, Campbell KP, Fenichel GM, Stedman HH, Kissel JT, Griggs RC, Pandya S, Mathews KD, Pestronk A, Serrano C, Darvish D, Mendell JR. Limb-girdle muscular dystrophy in the United States. J Neuropathol Exp Neurol 2006;65:995-1003.
32. Factor SM, Minase T, Cho S, Dominitz R, Sonnenblick EH. Microvascular spasm in the cardiomyopathic Syrian hamster: a preventable cause of focal myocardial necrosis. Circulation 1982;66: 342-354.
33. Kawano H, Ogawa H. Endothelial function and coronary spastic angina. Intern Med 2005;44:91-99.
34. Wheeler MT, Korcarz CE, Collins KA, Lapidos KA, Hack AA, Lyons MR, Zarnegar S, Earley JU, Lang RM, McNally EM. Second coronary artery vasospasm promotes cardiomyopathy progression. Am J Pathol 2004;1063-1071.
35. Frishman W, Sica DA. Calcium Channel Blockers. In "Cardiovascular Pharmacotherapeutics" Ed. By WH Frishman, EH Sonnenblick, and Sica DA. Vol. 1, Ch 9, 2003: p. 105-130.
36. Coral-Vázquez R, Cohn R, Moore SA, Hill JA, Weiss RM, Davisson RL, Straub V, Barresi R, Bansai D, Hrstka RF, Williamson R, Campbell KP. Disruption of sarcoglycan-sarcospan complex in vascular smooth muscle: A novel mechanism for cardiomyopathy and muscular dystrophy. Cell 1999;98:465-474.
37. Wheeler MT, Allikian MJ, Heydemann A, McNally EM. The sarcoglycan complex in striated and vascular smooth muscle. Cold Spring Harb Symp Quant Biol 2002;67:389-397.
38. Crespo MJ, Escobales N, Altieri PI. Altered Vascular Function in Early Stages of Heart Failure in Hamsters. J Card Fail 1997;3: 311-318.
39. Crespo MJ. Vascular Alterations During the Development and Progression of Experimental Heart Failure. J Card Fail 1999;5:55-63.
40. Crespo MJ, Altieri PI, Escobales N. Enhanced Contractility of Ang II in the Aorta of Cardiomyopathic Hamsters is Mediated by an Increased Ang II-Binding Capacity and Release of ET-1. Vasc Pharmacol 2006;44:247-252.
41. Francis GS, Benedict C, Johnstone DE, Kirlin PC, Nicklas J, Liang CS, Kubo SH, Rudin-Toretsky E, Yusuf S. Comparison of neuroendocrine activation in patients with left ventricular dysfunction with and without congestive heart failure. A sub study of the Studies of Left Ventricular Dysfunction (SOLVD). Circulation 1990;82:1724-1729.
42. Swedberg K, Eneroth P, Kjekshus J, Wilhelmesen L, for the CONSENSUS trial study Group. Hormones regulating cardiovascular function in patients with sever congestive heart failure and their relation to mortality. Circulation 1990;82:1730-1736.
43. Hintze TH, Wang J, Seyedi N, Wolin MS. Role of EDRF/NO in chronic high coronary blood flow states during myocardial dysfunction and failure. In "Flow-dependent Regulation of Vascular Function", Edited by JA Bevan, G Kaley, and GM Rubanyi, Oxford University Press, Ch 15, 1995: p. 320-337.
44. Mollnau H, Oelze M, August M, Wendt M, Daiber A, Schulz E, Baldus S, Kleschyov AL, Materne A, Wenzel P, Hink U, Nickenig G, Fleming I, Munzel T. Mechanisms of increased vascular superoxide production in an experimental model of idiopathic dilated cardiomyopathy. Arterioscler Thromb Vasc Biol 2005;25:2554-2559.
45. Noll G, Tschudi MR, Novosel D, Luscher TF. Activity of the L-arginine/nitric oxide pathway and endothelin-1 in experimental heart failure. J Cardiovasc Pharmacol 1994;23:916-921.
46. Buser PT, Camacho SA, Wu ST, Higgins CB, Jasmin G, Parmley WW, Wikman-Coffelt J. The effect of dobutamine on myocardial performance and high-energy phosphate metabolism at different stages of heart failure in Cardiomyopathic hamsters: a 31P MRS study. Am Heart J 1989;118:86-91.
47. Tanguay M, Jasmin G, Blaise G, Dumont L. Resistance of the failing dystrophic hamster heart to the cardioprotective effects of diltiazem and clentiazem: evidence of coronary vascular dysfunctions. Can J Physiol Pharmacol 1995;73:1108-1117.
48. Véronneau M, Tanguay M, Fontaine E, Jasmin G, Dumont L. Reactivity to endothelium-dependent and -independent vasoactive substances is maintained in coronary resistance vessels of the failing hamster heart. Cardiovasc Res 1997;33:623-630.
49. Brayden JE, Nelson MT. Regulation of arterial tone by activation of calcium-dependent potassium channels. Science 1992;256:532-535.
50. Cowan CL, Palacino JJ, Najibi S, Cohen RA. Potassium channel-mediated relaxation to acetylcholine in rabbit arteries. J Pharmacol Exp Ther 1993;266:1482-1489.
51. Mombouli JV, Vanhoutte PM. Endothelial dysfunction: from physiology to therapy. J Mol Cell Cardiol 1999;31:61-74.
52. Clark SG, Fuchs LC. Role of nitric oxide and Ca^{++}-dependent K^{+} channels in mediating heterogeneous microvascular responses

to acetylcholine in different vascular beds. J Pharm Exptl Ther 1997;282:1473-1479.
53. Soto MA, González C, Lissi E, Vergarra C, Latorre R. $Ca2^+$ -activated K^+-channel inhibition by reactive oxygen species. Am J Physiol Cell Physiol 2002;282:C461-C471.
54. Au AL, Seto SW, Chan SW, Chan MS, Kwan YW. Modulation by homocysteine of the iberiotoxin-sensitive, $Ca2^+$ -activated K^+ channels of porcine coronary artery smooth muscle cells. Eur J Pharmacol 2006;546:109-119.
55. Fuchs LC. Superoxide anions contribute to impaired endothelium-dependent relaxation in coronary arteries of young Cardiomyopathic hamsters. Endothelium 1996;4:141-149.
56. Drelicharz L, Kozlovski V, Skorka T, Heinze-Paluchowska S, Jasinski A, Gebska A, Guzik T, Olszanecki R, Wojnar L, Mende U, Csanyi G, Chlopicki S. NO and PGI_2 in coronary endothelial dysfunction in transgenic mice with dilated cardiomyopathy. Basic Res Cardiol 2008;103:417-430.
57. Shimokawa H, Takeshita A. Rho-kinase is an important therapeutic target in cardiovascular medicine. Arterioscler Thromb Vasc Biol 2005;25:1767-1775.
58. Higashi M, Shimokawa H, Hattori T, Hiroki J, Mukai Y, Morikawa K, Ichiki T, Takahashi S, Takeshita A. Long-term inhibition of Rho-kinase suppresses angiotensin II-induced cardiovascular hypertrophy in rats in vivo: effect on endothelial NAD(P)H oxidase system. Circ Res 2003;93:767-775.
59. Hermsmeyer K, Miyagawa K, Kelley ST, Rösch J, Hall AS, Axthelm MK, Greenberg B. Reactivity-based coronary vasospasm independent of atherosclerosis in rhesus monkeys. J Am Coll Cardiol 1997;29:671-680.
60. Hirsch A, Talsness C, Schunkert H, Paul M, Dzau V. Tissue-specific activation of cardiac angiotensin converting enzyme in experimental heart failure. Circ Res 1991;69:475-482.
61. Nakamura F, Nagano M, Kobayashi R, Higaki J, Mikami H, Kawaguchi N, Onishi S, Ogihara T. Chronic administration of angiotensin II receptor antagonist TCV-116 in cardiomyopathic hamsters. Am J Physiol 1994;267:H2297-H2304.
62. Kato Y, Iwase M, Takagi K, Nishizawa T, Kanazawa H, Matsushita A, Umeda H, Izawa H, Noda A, Koike Y, Nagata K, Yokota M Differential myolysis of myocardium and skeletal muscle in hamsters with dilated cardiomyopathy: beneficial protective effect of diltiazem. Circ J 2006;70:1497-1502.
63. Zhang C, Hein TW, Wang W, Kuo L. Divergent roles of angiotensin II AT1 and AT2 receptors in modulating coronary microvascular function. Circ Res 2003;92:322-329.
64. Dzau VJ. Tissue angiotensin and pathobiology of vascular disease: a unifying hypothesis. Hypertension 2001;37:1047-1052.
65. Dzau VJ, Gibbons GH, Pratt RE. Molecular mechanisms of vascular renin-angiotensin system in myointimal hyperplasia. Hypertension 1991;18(4 Suppl):II100-II105.
66. Ohishi M, Ueda M, Rakugi H, Okamura A, Naruko T, Becker AE, Hiwada K, Kamitani A, Kamide K, Higaki J, Ogihara T. Upregulation of Angiotensin-Converting Enzyme During the Healing Process After Injury at the Site of Percutaneous Transluminal Coronary Angioplasty in Humans. Circulation 1997;96:3328-3337.
67. Fukuhara M, Geary RL, Diz DI, Gallagher PE, Wilson JA, Glazier SS, Dean RH, Ferrario CM. Angiotensin-converting enzyme expression in human carotid artery atherosclerosis. Hypertension 2000;35:353-359.
68. Suda O, Tsutsui M, Morishita T, Tanimoto A, Horiuchi M, Tasaki H, Huang PL, Sasaguri Y, Yanagihara N, Nakashima Y. Long-term treatment with N^{ω}-nitro-L-arginine methyl ester causes arteriosclerotic coronary lesions in endotelial nitric oxide synthase-deficient mice. Circulation 2002;106:1729-1735.
69. Suda O, Tsutsui M, Morishita T, Tasaki H, Ueno S, Nakata S, Tsujimoto T, Toyohira Y, Hayashida Y, Sasaguri Y, Ueta Y, Nakashima Y, Yanagihara N. Asymmetric dimethylarginine produces vascular lesions in endothelial nitric oxide synthase-deficient mice: involvement of renin-angiotensin system and oxidative stress. Arterioscler Thromb Vasc Biol 2004;24:1682-1688.
70. Landmesser U, Drexler H. Oxidative stress, the renin-angiotensin system and atherosclerosis. Eur Heart J Supplements 2003;5(Suppl A):A3-A7.
71. Kubo-Inoue M, Egashira K, Usui M, Takemoto M, Ohtani K, Katoh M, Shimokawa H, Takeshita A. Long-term inhibition of nitric oxide synthesis increases arterial thrombogenecity in rat carotid artery. Am J Physiol Heart Circ Physiol 2002;282: H1478-H1484.
72. Lee J, Kim S, Oh Y, Ryu SY, Kim SW. Upregulation of vascular renin-angiotensin and endothelin systems in rats inhibited of nitric oxide synthesis. Pharmacol Res 2002;46:383-387.
73. Takemoto M, Egashira K,Usui M, Numaguchi K, Tomita H, Tsutsui H, Shimokawa H, Sueishi K, Takeshita A. Important role of tissue angiotensin-converting enzyme activity in the pathogenesis of coronary vascular and myocardial structural changes induced by long-term blockade of nitric oxide synthesis in rats. J Clin Invest 1997;99:278-287.
74. Hasegawa K, Wakino S, Tatematsu S, Yoshioka K, Homma K, Sugano N, Kimoto M, Hayashi K, Itoh H. Role of asymmetric dimethylarginine in vascular injury in transgenic mice overexpressing dimethylarginine dimethylaminohydrolase 2. Circ Res 2007;101:e2-e10.
75. Wang H, Wang Z, Chen J, Wu J. Apoptosis induced by NO via phosphorylation of p38 MAPK that stimulates NF-kappaB, p53 and caspase-3 activation in rabbit articular chondrocytes. Cell Biol Int 2007;31:1027-1035.
76. Moniwa N, Agatha J, Hagiwara M, Ura N, Shimamoto K. The role of bradykinin B1 receptor on cardiac remodeling in stroke-prone spontaneously hypertensive rats (SHR-SP). Biol Chem 2006;387:203-209.
77. Escobales N, Crespo MJ. Oxidative-nitrosative Stress in Hypertension. Curr Vasc Pharmacol 2005;3:231-246.
78. Kyoi S, Otani H, Matsuhisa S, Akita Y, Tatsumi K, Enoki C, Fujiwara H, Imamura H, Kamihata H, Iwasaka T Opposing effect of p38 MAP kinase and JNK inhibitors on the development of heart failure in the cardiomyopathic hamster. Cardiovasc Res 2006;69:888-898.
79. Camisi PG, Crea, F. Coronary Microvascular Dysfunction. N Engl J Med 2007;356:830-840.
80. Crespo MJ, Cruz N, Altieri PI, Escobales N. Enalapril and losartan are more effective than carvedilol in preventing dilated cardiomyopathy in the Syrian cardiomyopathic hamster. J Cardiovasc Pharmacol Ther 2008;13:199-206.