

Rapidly Progressive and Almost Lethal Pneumonia

Juancarlo Martínez-González, MD; Carlos Robles-Arias, MD;
William Rodríguez-Cintrón, MD, MACP

We herein describe the case of a 65-year-old male patient who presented with Osler's triad, which is the combination of endocarditis, pneumonia, and meningitis. This report is even more unusual since the pathogen isolated was the invasive and virulent strain of *Streptococcus pneumoniae* serotype 3. The clinical entity described is also called Austrian syndrome. Even though rare in this antibiotic era, the syndrome remains one of high morbidity and mortality. This particular case is of paramount importance for the clinician reader. First, it documents the clinical features associated with invasive pneumococcal disease and the Austrian syndrome. Second, and equally important, it highlights why following the Surviving Sepsis Campaign guidelines saves lives. For this case, the following steps were taken: 1. As a surrogate for perfusion, early and aggressive fluid resuscitation therapy (guided by lactic acid levels) was instituted; 2. also early in the treatment, broad spectrum antibiotics were administered; 3. to guide antibiotic therapy, microbiological cultures were obtained. The patient subsequently improved and was transferred to the internal medicine ward to complete 4 weeks of antibiotic therapy. [*PR Health Sci J* 2017;36:41-43]

Key words: Pneumonia, *Streptococcus pneumoniae*, Septic shock, Austrian syndrome, Antibiotics

A 65-year-old man arrived at the emergency room, his chief complaints being a cough, dizziness, and shortness of breath of 2 days' duration. His past medical history was significant for coronary artery disease, bioprosthetic aortic valve replacement, chronic liver disease secondary to hepatitis C, and IV drug use on remission. On evaluation at the ER, he was initially found with blood pressure of 89/45 mmHg, a heart rate of 110 bpm, and temperature of 97.1° F. He was acutely ill with bibasilar ronchi. A chest radiograph was significant for right lower base consolidation. Admission labs showed leukocytosis (21,700 cells/mm³) with a left shift and increase in band cells to 33%. acute renal failure (creatinine, 2.02 mg/dl), lactic acidosis (LA) (lactic acid, 11 mg/dl), and Howell-Jolly bodies on peripheral smear. He was admitted to the internal medicine ward with the diagnostic impression of sepsis secondary to community-acquired pneumonia. Empirical antibiotic therapy was started with ceftriaxone and azithromycin.

His clinical state deteriorated drastically in less than 24 hours. He required aggressive IV fluid resuscitation, with over 5 liters of normal saline, due to hypotension. Subsequently the patient developed tachypnea (25 rpm) with positive jugular venous distention and sinus tachycardia (140 bpm). New chest imaging done within 24 hours of arrival (Figure 1) showed worsening bibasilar consolidation. The patient was started on non-invasive positive-pressure ventilation and transferred to the intensive care unit (ICU) for further management. At that point, antibiotic therapy was broadened to include vancomycin and cefepime, since preliminary blood cultures were reported with gram-positive cocci in pairs. After therapy optimization, his clinical

scenario greatly improved, with a significant decrease of lactic acid (2 mg/dl) and resolution of hypotension (120/60 mmHg) on arrival at the ICU.

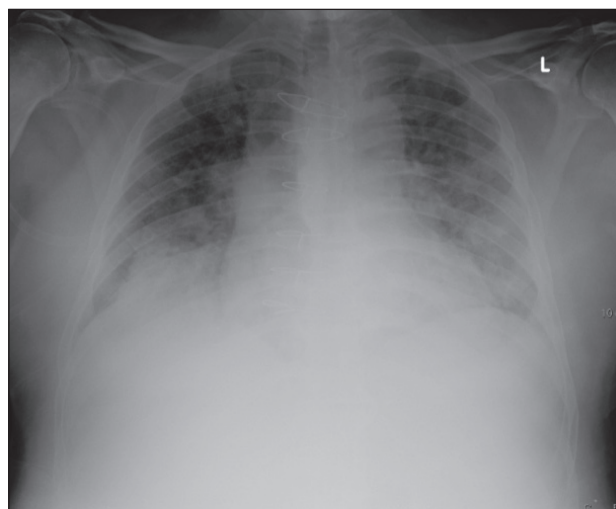


Figure 1. Follow-up chest radiograph of right basilar infiltrate and interval development of the left peri-hilar and basilar infiltrate.

Pulmonary/Critical Care Medicine, VA Caribbean Healthcare System, San Juan, PR

The author/s has/have no conflict/s of interest to disclose.

Address correspondence to: William Rodríguez-Cintrón, MD, Pulmonary/Critical Care Medicine (111-E), VA Caribbean Healthcare System, 10 Casia Street, San Juan, PR 00921. Email: William.Rodriguez@va.gov

While at the ICU, microbiology personnel reported the growth of an unusual pathogen characterized by a mucoid capsule with high polysaccharide content, suggestive of *Streptococcus pneumoniae* type 3 (Figure 2). Because of the patient's increasingly confused state and the evidence of meningeal signs upon further physical examination, the decision was made to add high-dose ceftriaxone to the vancomycin to ensure adequate central nervous system (CNS) coverage. A lumbar puncture was attempted but was unsuccessful due to lack of patient cooperation. Because of the associated comorbidities, a transesophageal echocardiogram was done, which test showed a 0.4 cm mitral valve vegetation (Figure 3).

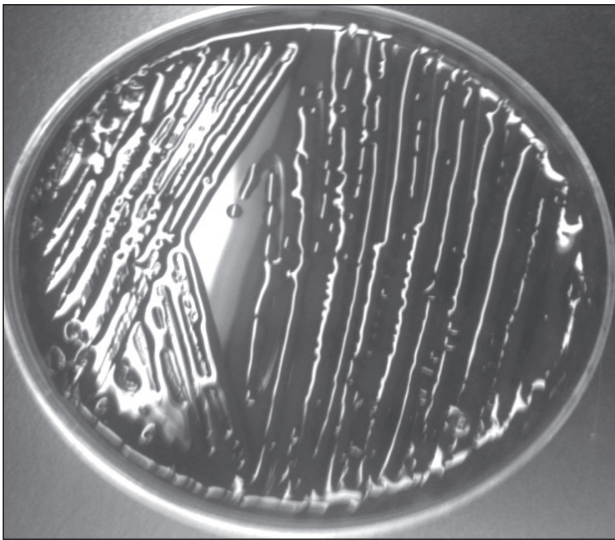


Figure 2. Almost pure growth of an α -hemolytic mucoid colony.

On the fifth day of hospitalization, blood cultures were confirmed to be positive for *Streptococcus pneumoniae* serotype 3 (which was susceptible to ceftriaxone). The patient continued showing clinical improvement and eventually was transferred

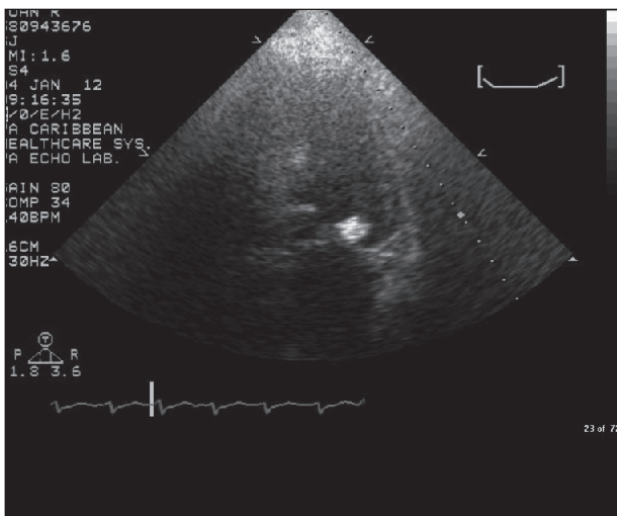


Figure 3. Two-dimensional echocardiography image showing a 4-mm mobile mitral valve vegetation.

to the internal medicine ward to complete 4 weeks (a total of 28 days) of antibiotic therapy. Follow-up cultures showed no growth. The patient was discharged home without further complications.

Discussion

Despite advances in the practice of medicine, including the wise use of antibiotics and preventive vaccination, *Streptococcus pneumoniae* remains one of the most common organisms leading to hospitalization in all age groups (1). Estimates of the incidence of pneumococcal disease from 2007 in USA indicate that there were around 40,000 cases, of which more than 4,400 died from invasive pneumococcal disease (IPD). Even though incidence has decreased considerably compared to that of the pre-antibiotic era, IPD remains of great concern because of its high morbidity and mortality (2). Nowadays, despite appropriate antimicrobial treatment, pneumococcal meningitis has a mortality rate of 20 to 30% (3). Its rapid progression and fatal complications make imperative its early recognition by physicians so that they might tailor an appropriate antibiotic therapy and diagnostic evaluation.

There are numerous recognized predisposing factors for invasive pneumococcal infection, including alcoholism, splenectomy, diabetes mellitus, and immunosuppression, among others (4). Viral respiratory illnesses, such as influenza, have also been described (5). The risk of invasive disease also appears to be closely related to certain serotypes. At present, at least 90 immunologically distinct serotypes, differing in the chemical compositions of their polysaccharide capsules, are known to exist (6–7). Of them, serotypes 1, 6, 14, 19, 23, and 3 are the ones most commonly associated with invasive disease, both in pediatric and adult populations, with the further qualification that serotype 3 tends to predominate in older children and adults (8).

Interestingly, serotype 3 has been found to be independently associated with septic shock as well as with high mortality rates in terms of bacteremic pneumococcal pneumonia (9). Serotype 3's high virulence seems to be associated with its increased content of capsular polysaccharide. This feature increases the resistance to phagocytosis as well as to wall components and toxins, which have a synergistic role in the inflammatory response. To our knowledge, only one manuscript addressing the incidence of *Streptococcus pneumoniae* in Puerto Rico has been published. Most of the serotypes mentioned in that manuscript are addressed by the 23-valent conjugate vaccine (78%) for patients above 60 years. Almost half of the isolates showed resistance to cephalosporin and macrolides. In that population, the most frequent factors and predisposing conditions associated with invasive disease in adult patients were diabetes mellitus, cardiovascular disease, cigarette smoking, and asthma (10).

In addition to the pneumococcal capsule, other gene products also contribute to the pathogenic potential, as is the case of

other encapsulated bacteria such as *Nisseria meningitidis*. This argument has been found less valid after multiple studies have shown that the invasiveness among strains was associated more with the identity of the capsular serotype than it was with specific genotype. It is from there that the justification for using the serotype as the unit of analysis develops. (11–12). Unfortunately what is beyond doubt is that the resistance of pneumococci to a variety of antimicrobial agents has become a worldwide health problem (13). However beta-lactam resistance is largely dose-dependent; as a result, it can be overcome by appropriate dosing. Here lies the importance of appropriate dose selection, which, as seen in our patient, may have made the difference between his living and dying (14).

Last, but not least, this case illustrates the importance of early goal-directed therapy provided in severe sepsis and septic shock, which has proven to save lives (15). And although the previous statement has been questioned in recent studies, this case serves as evidence that the most important elements in the management of sepsis are the timely collection of blood cultures, the early administration of antibiotics, and early adequate volume resuscitation. All these variables, fitting within the framework of high clinical suspicion, led in this case of invasive pneumococcal disease, to a survival outcome.

Resumen

Describimos el caso de un paciente masculino de 65 años de edad, que presentó la tríada de Osler, que es la combinación de la endocarditis, neumonía y meningitis. Este reporte es aún más inusual ya que el patógeno aislado fue la cepa invasiva y virulenta de *Streptococcus pneumoniae* serotipo 3. La entidad clínica descrita también se llama síndrome de Austrian. Aunque raro en la actual era de antibióticos, sigue siendo uno de alta tasa de morbilidad y mortalidad. Este caso en particular es de gran importancia para el lector clínico. Primero, documenta las características clínicas asociadas con enfermedad invasiva neumococcica y el síndrome de Austrian. Segundo, y de igual importancia, es que destaca porque el seguir las guías de la Campaña de Supervivencia de Sepsis. Terapia temprana agresiva de resuscitación de fluidos guiada por niveles de ácido láctico como marcador de perfusión, administración temprana de antibióticos de amplio espectro y obtención de cultivos

microbiológicos que subsecuentemente guiaron terapia de antibióticos fueron utilizados. El paciente ulteriormente mejoró y fue transferido al piso de medicina general para completar 4 semanas de antibioterapia.

References

1. Marrie TJ, Durant H, Yates L. Community-acquired pneumonia requiring hospitalization: 5-year prospective study. *Rev Infect Dis* 1989;11:586–599.
2. Centers for Disease Control and Prevention (CDC). Defining the public health impact of drug-resistant *Streptococcus pneumoniae*: report of a working group. *MMWR Recomm Rep* 1996;45(RR-1 Suppl):1–20.
3. Feikin DR, Schuchat A, Kolczak M, et al. Mortality from invasive pneumococcal pneumonia in the era of antibiotic resistance, 1995–1997. *Am J Public Health* 2000;90:223–229.
4. Centers for Disease Control and Prevention (CDC). Use of 13-valent pneumococcal conjugate vaccine and 23-valent pneumococcal polysaccharide vaccine for adults with immunocompromising conditions: recommendations of the Advisory Committee on Immunization Practices (ACIP). *MMWR Morb Mortal Wkly Rep* 2012;61:816–819.
5. McCullers JA. Insights into the interaction between influenza virus and pneumococcus. *Clin Microbiol Rev* 2006;19:571–582.
6. Henrichsen J. Six newly recognized types of *Streptococcus pneumoniae*. *J Clin Microbiol* 1995;33:2759–2762.
7. Kamerling JP. Pneumococcal polysaccharides: a chemical view. In: Tomasz A, ed. *Streptococcus pneumoniae. molecular biology and mechanism of disease*. New York, NY: Mary Ann Leibert; 2000:269–275.
8. Hausdorff WP, Feikin DR, Klugman KP. Epidemiological differences among pneumococcal serotypes. *Lancet Infect Dis* 2005;5:83–93.
9. Garcia-Vidal C, Ardanuy C, Tubau F, Viasus D, Dorca J, Linares J, Gudiol F, Carratalà J. Pneumococcal pneumonia presenting with septic shock: host- and pathogen-related factors and outcomes. *Thorax* 2010;65:77–81. doi:10.1136/thx.2009.123612.
10. Rivera-Matos IRI, Rios-Olivares E. A multicenter hospital surveillance of invasive *Streptococcus pneumoniae*, Puerto Rico, 2001. *P R Health Sci J* 2005;24:185–189.
11. Hollingshead SK, Briles DE. *Streptococcus pneumoniae*: new tools for an old pathogen. *Curr Opin Microbiol* 2001;4:71–77.
12. Taha MK, Deghmane AE, Antignac A, Zarantonelli MI, Larribe M, Alonso JM. The duality of virulence and transmissibility in *Neisseria meningitidis*. *Trends Microbiol* 2002;10:376–382.
13. Visalli MA, Jacobs MR, Appelbaum PC. Susceptibility of twenty penicillin-susceptible and -resistant pneumococci to levofloxacin, ciprofloxacin, ofloxacin, erythromycin, azithromycin, and clarithromycin by MIC and time-kill. *Diagn Microbiol Infect Dis* 1997;28:131–137.
14. Song JH, Jung SI, Ko KS, et al. High prevalence of antimicrobial resistance among clinical *Streptococcus pneumoniae* isolates in Asia (an ANSORP study). *Antimicrob Agents Chemother* 2004;48:2101–2107.
15. Rivers E, Nguyen B, Havstad S, et al; Early Goal-Directed Therapy Collaborative Group. Early goal-directed therapy in the treatment of severe sepsis and septic shock. *N Engl J Med* 2001;345:1368–1377.