

## Hindfoot Fusion Nail with Adjuvant Hybrid External Fixation used as Limb-Salvage Procedure after Failed Open Reduction Internal Fixation of Ankle Fracture in a Charcot Joint: A Case Report

Román G. Guerrero-Maestre, MD; David Beaton-Comulada, MD;  
Roberto Colon-Miranda, MD; Pedro Reyes-Martinez, MD

The failure of the internal fixation of an ankle fracture due to Charcot joint/neuroarthropathy is rare; such occurred in the case of a 52-year-old woman with uncontrolled diabetes who sustained a right ankle fracture after falling from standing height. The patient was treated with the internal fixation of both malleoli, which procedure failed as the patient progressed, until she eventually was diagnosed with Charcot arthropathy. The post-operative images were reviewed and showed a catastrophic fixation failure with a diagnosis of Charcot neuroarthropathy. At that point, we decided to treat the problem presented with salvage arthrodesis, combining hindfoot fusion nail with adjuvant external fixation. This treatment was selected to augment stability and achieve stable fixation. The post-operative visits showed wound healing without complications and painless weight bearing. The follow-up radiographs showed tibiotalar fusion with painless union of the subtalar joint at 48 weeks. [*PR Health Sci J* 2018;37:235-238]

*Key words: Hindfoot nail, Charcot joint, Fixation failure, Arthrodesis*

The public health burden of caring for diabetic patients with ankle fractures is substantial and increasing (1–2). Complications and poor outcomes are more commonly expected in these patients than they are in non-diabetic patients (1–3). Long-standing hyperglycemia accounts for how this condition disrupts tissue properties. Poor soft-tissue oxygenation, the high incidence of infection, and delayed bone- and wound-healing capacity are all known causes of complications in diabetic patients (1, 4). Charcot joint is a peripheral neuropathic arthropathy which causes destruction via a non-infectious, periarticular process that creates devastating consequences (1, 5). The incidence of Charcot neuroarthropathy in persons with diabetes is estimated to be 0.12% (6).

The pathogenesis of Charcot neuroarthropathy has been attributed to multiple mechanisms, including an exaggerated overuse injury of an insensate joint subjected to microtrauma (7); the patient's abnormal sensorium prevents him or her from adopting normal protective behavior. Neurovascular theory accounts for the autonomic dysfunction that leads to increased arteriovenous shunting, which in turn results in aggressive bone resorption and weakening (8). Bone density analysis has showned that patient with this condition tend to have marked osteopenia, which increases the risk of fracture (9). The presence of inflammatory cytokines has been confirmed in pathological specimens of patients with Charcot neuroarthropathy, implicating these proteins in the pathogenesis of the disease (7).

After a thorough review of the literature, no case that used a treatment similar to our own was found. We present the case of a 52-year-old female patient with uncontrolled diabetes mellitus type 2 who suffered a bimalleolar fracture of the right ankle and developed a Charcot arthropathy. The patient was treated with salvage surgery using an intramedullary hindfoot nail and added hybrid external fixation, achieving promising results with regard to this complication.

### Case Report

The patient was a 52-year-old woman with a past medical history of uncontrolled diabetes mellitus type 2 who sustained a right ankle bimalleolar fracture after falling from standing height. The patient was treated acutely with open reduction internal fixation of both malleoli. After three uneventful post-operative visits, the patient presented (2 months after the index procedure) with serial radiographs showing catastrophic failure of fixation, even after conservative no-weight-bearing instructions and immobilization for the

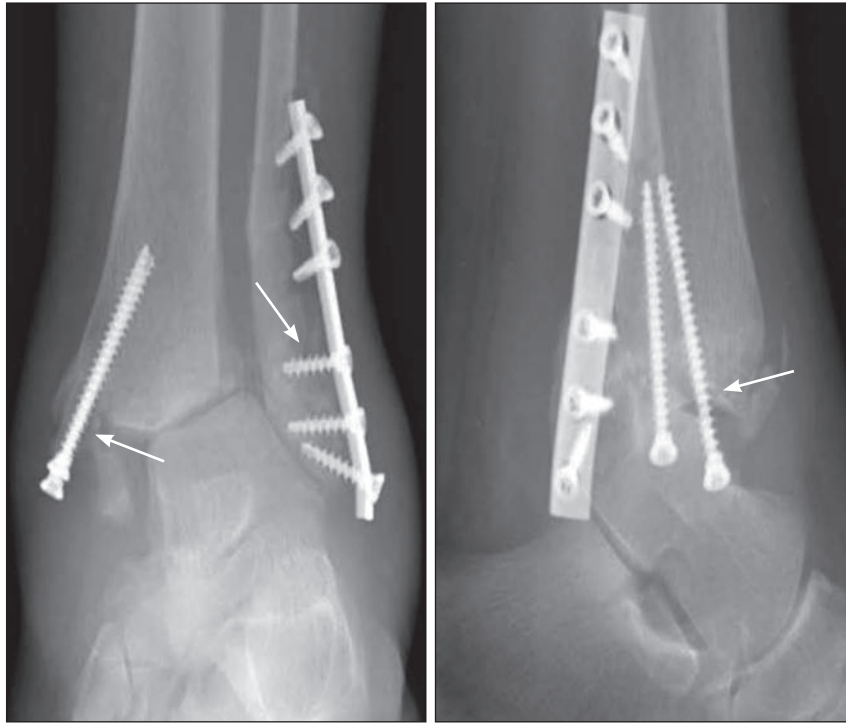
Department of Orthopedic Surgery, School of Medicine, University of Puerto Rico Medical Sciences Campus, San Juan, PR

*The author/s has/have no conflict/s of interest to disclose.*

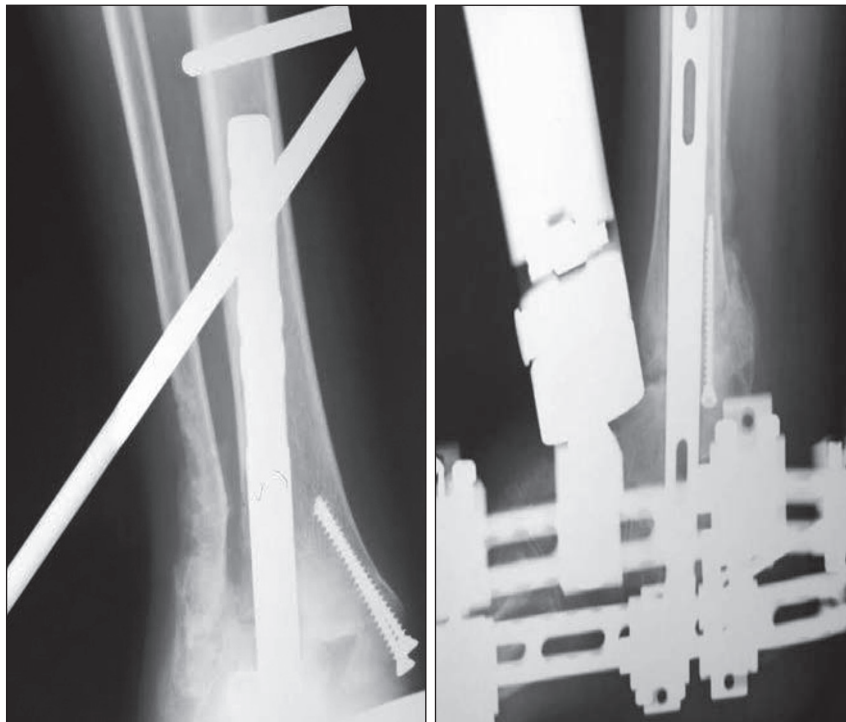
Address correspondence to: Román G. Guerrero-Maestre, MD, University of Puerto Rico, Medical Sciences Campus, Department of Surgery-Orthopedics, PO Box 365067, San Juan, PR 00936-5067. Email: roman.guerreromaestre@upr.edu

ongoing post-operative period. The patient presented with no gross signs of infection. No draining sinuses or purulent confluences in soft tissue were observed. Superficial findings in Charcot neuroarthropathy can be easily misdiagnosed as

an ongoing deep infection. Pain, high skin temperature, and swollen ankles are common findings in both. Nonetheless, Charcot neuroarthropathy often follows a predictable clinical and radiographic pattern.



**Figures 1a and 1b.** AP and lateral radiographs of catastrophic failure of internal fixation, as seen in post-operative visit. Red arrows in both views demonstrate areas of nonunion.



**Figures 2a and 2b.** AP and lateral radiographs after hindfoot nail and hybrid external fixation, as seen in post-operative week 4.

Warmth and swelling were assessed on physical examination; orthogonal radiographs of the affected ankle were reviewed at the 2-month follow-up, which showed catastrophic fixation failure, osteopenia, periarticular fragmentation, and dislocation of the ankle joint (Figures 1a & 1b). This myriad of findings suggested the fragmentation stage of Charcot neuroarthropathy.

The patient was oriented about prognosis and treatment options. A consensual decision was made to treat the fixation failure (fracture non-union and neuroarthropathy) with expedited limb-salvage surgical arthrodesis. Instead of a normal arthrodesis consisting of bone and cartilage exposure through a larger incision, we combined a retrograde hindfoot nail with adjuvant hybrid external fixation to increase stability in the joint and decrease soft-tissue insult (Figures 2a & 2b). No specific article was found in the literature in which the failure of ankle open reduction internal fixation with concomitant ankle Charcot neuroarthropathy has been treated with a process similar to our own.

In the visit after the salvage procedure, the patient was observed to be experiencing rapid soft tissue healing without any superficial wound complications. We felt that hybrid external fixation provided rigid immobilization so that the patient could be permitted early weight bearing. Follow-up radiographs showed tibiotalar fusion with painless union of the subtalar joint. Pseudoarthrosis was not visible in the imaging studies done during the follow-up period. The hybrid external fixator was removed at 24 weeks. A subsequent encounter with the patient at 48 weeks post-op revealed a stable, healed tibio-talo-calcaneal fusion, at which point she was able to bear her full weight and wear shoes (Figures 3a & 3b).

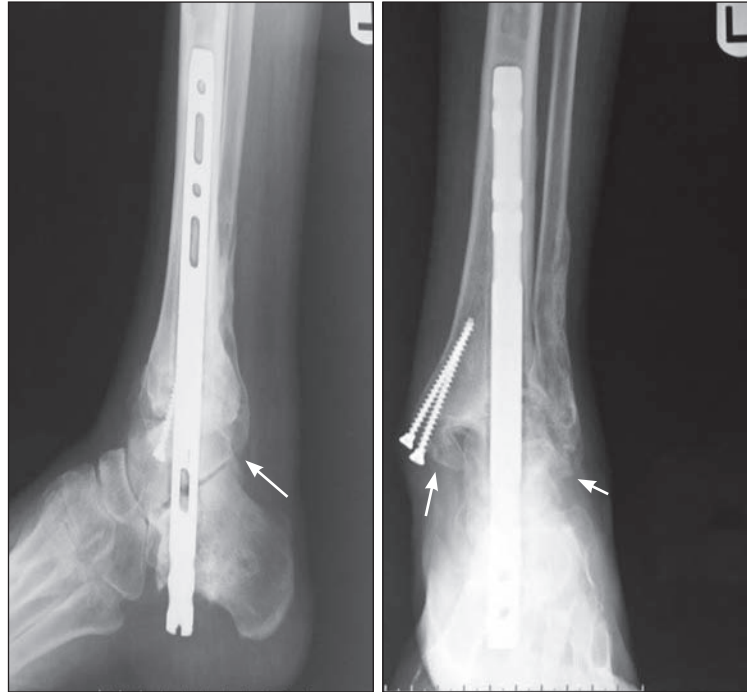
## Discussion

Infection, hardware malposition, ulceration, and fracture are the most common complications seen after arthrodesis (10–11). One case series involving 29 Charcot arthropathy patients undergoing ankle arthrodesis reported complication rates as high as 66% (12). Because of the high risk of complications, our patient was managed with minimal surgical insult to the soft tissue. Hindfoot intramedullary nail and/or external fixation have been described as options for deformities such as the one seen in our patient (13–14). Ettinger et al (13), in a retrospective study involving 58 cases of Charcot arthropathy treated with intramedullary hindfoot nail and external fixator, reported a success rate of 100% and 84%, respectively, for ankle fusion. Siebachmeyer et al recently reported excellent outcomes in 20 patients using hindfoot nail as a 1-stage correction procedure; limb salvage was achieved in all of them (15). Our treatment using external fixation simultaneously with hindfoot nail proved to lower complications related to skin infections and was successful in achieving stable ankle fusion without the need for proper arthrodesis to be performed.

Failure of ankle open reduction internal fixation after acute fracture, regardless of patient comorbidities, can be a catastrophic finding for any orthopedic surgeon. Few limb-salvage procedures are available that can adequately address such a failure, especially when it has occurred simultaneously with such a destructive process as Charcot neuroarthropathy. After a thorough investigation of the options, the decision to combine hindfoot intramedullary tibiotalocalcaneal fusion nail with a hybrid external fixation system to augment joint stability and achieve stable fusion was taken. We understood that this option provided both the least amount of soft-tissue compromise and the rigid stability needed to counteract neuroarthropathy pathogenesis. As the imaging shows, the results were favorable; bony and painless fibrous union was achieved. No minor or major complication was identified, and at the 10-month follow-up, the patient's external fixator had been removed, her wounds had healed, and she was able to walk without pain while wearing shoes

## Resumen

El fallo de una fijación de tobillo a causa de neuroartropatía de Charcot no es un hallazgo común en la ortopedia. Presentamos el caso de una paciente de 52 años con diabetes mellitus descontrolada que sufrió una fractura de tobillo. Paciente fue tratada inicialmente con fijación interna de ambos maléolos. Tratamiento falló luego del desarrollo de neuroartropatía de Charcot en la articulación de su tobillo. Imágenes post-operatorias fueron evaluadas y demostraron



**Figures 3a and 3b.** AP and lateral radiographs showing bony and fibrous union after removing external fixator in post-operative week 44. Red arrows show areas of bone and fibrous healing.

un fallo catastrófico de la fijación con hallazgos clínicos y radiográficos de la etapa de fragmentación de la neuroartropatía de Charcot. En ese momento, decidimos manejar el fracaso del procedimiento combinando un clavo tibiotalocalcaneal con un fijador externo. Imágenes de seguimiento demostraron fusión indolora de las articulaciones del retropié. Presentamos un método de rescate donde combinamos un clavo de fusión tibiotalocalcaneal y fijación externa con el cual obtuvimos buenos resultados.

## References

1. Kannus P, Palvanen M, Niemi S, Parkkari J, Jarvinen M. Increasing number and incidence of low-trauma ankle fractures in elderly people: Finnish statistics during 1970-2000 and projections for the future. *Bone* 2002;31:430-433.
2. Egol KA, Tejwani NC, Walsh MG, Capla EL, Koval KJ. Predictors of short-term functional outcome following ankle fracture surgery. *J Bone Joint Surg Am* 2006;88:974-979.
3. Ganesh SP, Pietrobon R, Cecilio WA, Pan D, Lightdale N, Nunley JA. The impact of diabetes on patient outcomes after ankle fracture. *J Bone Joint Surg Am* 2005;87:1712-1718.
4. Macey LR, Kana SM, Jingushi S, Terek RM, Borretos J, Bolander ME. Defects of early fracture-healing in experimental diabetes. *J Bone Joint Surg Am* 1989;71:722-733.
5. Connolly JF, Csencsitz TA. Limb threatening neuropathic complications from ankle fractures in patients with diabetes. *Clin Orthop Relat Res* 1998(348):212-219.
6. Stuck RM, Sohn MW, Budiman-Mak E, Lee TA, Weiss KB. Charcot arthropathy risk elevation in the obese diabetic population. *Am J Med* 2008;121:1008-1014.
7. Trieb K. The Charcot foot: pathophysiology, diagnosis and classification. *Bone Joint J* 2016;98-b:1155-1159.

8. Edmonds ME, Roberts VC, Watkins PJ. Blood flow in the diabetic neuropathic foot. *Diabetologia* 1982;22:9–15.
  9. Jirkovska A, Kasalicky P, Boucek P, Hosova J, Skibova J. Calcaneal ultrasonometry in patients with Charcot osteoarthropathy and its relationship with densitometry in the lumbar spine and femoral neck and with markers of bone turnover. *Diabet Med* 2001;18:495–500.
  10. Stone NC, Daniels TR. Midfoot and hindfoot arthrodeses in diabetic Charcot arthropathy. *Can J Surg* 2000;43:449–455.
  11. Dalla Paola L, Volpe A, Varotto D, Postorino A, Brocco E, Senesi A, et al. Use of a retrograde nail for ankle arthrodesis in Charcot neuroarthropathy: a limb salvage procedure. *Foot Ankle Int* 2007;28:967–970.
  12. Papa J, Myerson M, Girard P. Salvage, with arthrodesis, in intractable diabetic neuropathic arthropathy of the foot and ankle. *J Bone Joint Surg Am* 1993;75:1056–1066.
  13. Ettinger S, Plaass C, Claassen L, Stukenborg-Colsman C, Yao D, Daniilidis K. Surgical Management of Charcot Deformity for the Foot and Ankle—Radiologic Outcome After Internal/External Fixation. *J Foot Ankle Surg* 2016;55:522–528. American College of Foot and Ankle Surgeons 2017;56:802–804.
  14. Sundararajan SR, Srikanth KP, Nagaraja HS, Rajasekaran S. Effectiveness of Hindfoot Arthrodesis by Stable Internal Fixation in Various Eichenholtz Stages of Neuropathic Ankle Arthropathy. *J Foot Ankle Surg* 2017;56:282–286.
  15. Siebachmeyer M, Boddu K, Bilal A, Hester TW, Hardwick T, Fox TP, et al. Outcome of one-stage correction of deformities of the ankle and hindfoot and fusion in Charcot neuroarthropathy using a retrograde intramedullary hindfoot arthrodesis nail. *Bone Joint J* 2015;97-b: 76–82.
-