
Acquired Intrathoracic Kidney

SAMUEL SUÁREZ, MD; YOHANA DE JESÚS, MD

ABSTRACT. A 63 year old female with neurofibromatosis was referred to the Pulmonary Clinic of the University Hospital for evaluation of a right thoracic mass. Physical examination revealed subcutaneous nodules over the trunk area, *café au lait* spots, and dullness to percussion with decreased breath sounds at the right lung base. The chest X ray showed a 4 cm mass at the right lung base. Computerized tomography of the chest demonstrated a right posterior diaphragmatic hernia with displacement of the liver and kidney into the thoracic cavity. Renal scan confirmed the location of the kidney in the right hemithorax showing normal renal cortical function.

Intrathoracic kidney is a very rare finding, most are found in males and are asymptomatic. They are usually found in the left hemithorax and associated to a normal diaphragm. Only 0.25% are associated with a diaphragmatic hernia. In our patient, there was a history of mild trauma five years earlier, but this did not clearly explain how the kidney became ectopic. Acquired intrathoracic kidney should be considered in the differential diagnosis of a lung mass to avoid an unnecessary thoracotomy and nephrectomy. *Key words:* Intrathoracic kidney, Neurofibromatosis, Diaphragmatic hernia.

Ectopia of the kidneys is found in about 1% of autopsies (1). Its occurrence inside the thoracic cavity accounts for about 5% of all renalectopia (2,3), with a prevalence of less than 1/ 10000 persons. Since 1922 there have been about 180 cases reported in the medical literature (4). Most patients are males (60%), in 2/3 of cases they are found in the left hemithorax, only 2% are bilateral and they are usually asymptomatic (4). The fact that previous chest films were normal, make this an unusual case.

Case Report

A 63 year old nonsmoker female with neurofibromatosis was referred to the Pulmonary Clinic for evaluation of a right thoracic mass found during the

evaluation of a respiratory tract infection. She complained of a mild non productive cough, but denied dyspnea or chest pain. The physical exam revealed decreased breath sounds and dullness to percussion at the right lung base, *café au lait* spots and subcutaneous nodules over the trunk area. The trachea was in the midline, and no abdominal tenderness or masses were present. The chest film revealed a 4 cm mass in the right lung base (Fig. 1). Computerized

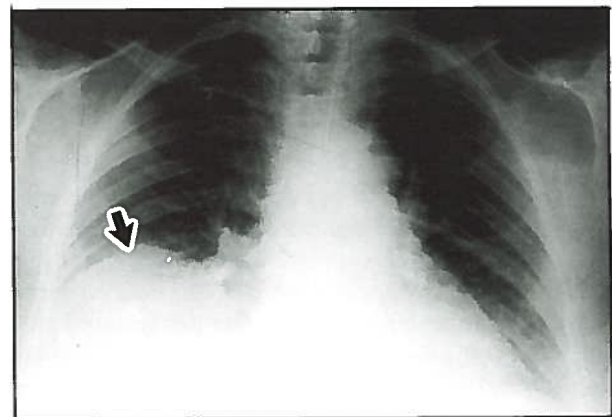


Figure 1. Chest film showing a 4cm. right lung base mass (arrow).

From the Department of Medicine, Pulmonary Diseases Section, Medical Sciences Campus, University of Puerto Rico, San Juan, Puerto Rico.

Address for correspondence: Samuel Suárez MD, Department of Medicine, University of Puerto Rico Medical School, PO Box 365067, San Juan, PR. 00936-5067.

tomography of the chest demonstrated a right posterior diaphragmatic hernia with displacement of the right liver lobe and the right kidney into the thoracic cavity (Fig. 2).

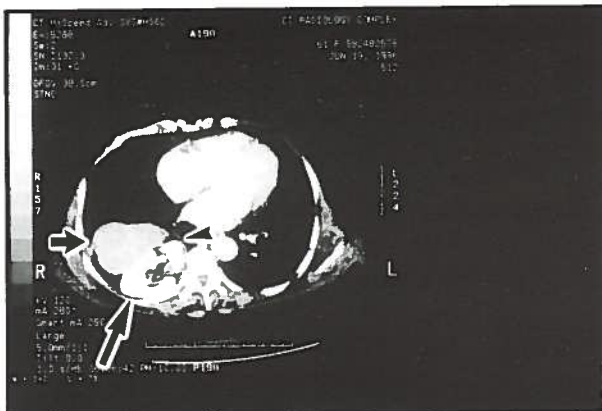


Figure 2. Computerized tomography of the chest demonstrating a right posterior diaphragmatic hernia (arrow head) with displacement into the thoracic cavity of the right liver lobe (short arrow) and right kidney (long arrow).

Renal scan showed preserved bilateral cortical function and a slightly dilated right pelvocalyceal system (Fig. 3). A chest film obtained seven years before was reported as negative. There was history of frequent body contusions

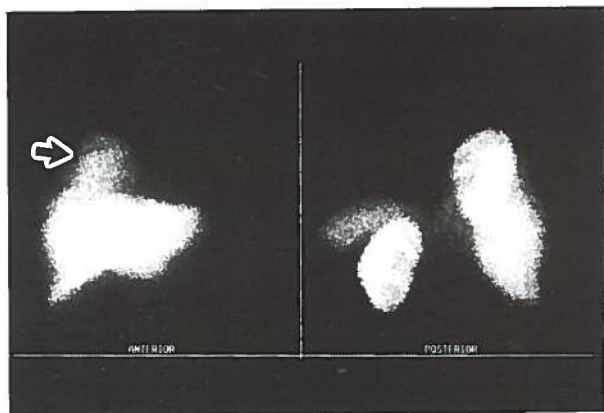


Figure 3. Renal scan. Anterior view of the right kidney (arrow) superior to the liver. The posterior view shows the position of both kidneys.

after seizures five years before, no further body trauma was reported. Due to the absence of symptoms and normal renal function, surgery was not recommended. A year after initial evaluation she was admitted to the hospital due to an unrelated intrabdominal infection that resolved after antibiotics. She was lost to follow up 18 months after our last evaluation and until that moment no deterioration in renal function was detected.

Discussion

The kidneys and the rest of the urinary system develop from a specialized part of the mesoderm called the urogenital ridge (5). Their development involves ascension from a pelvic position and ventral rotation, so the renal pelvis will be facing the spine. While ascending, their blood supply changes, first from caudal branches of the aorta and then from the adult renal artery at a more cranial position (5,6).

This complex embryological development predisposes to ectopic locations where pelvic kidneys are more common than intrathoracic. A possible explanation for a higher or intrathoracic position might be a retained ingrowth of the ureter into the metanephros, or the kidney at the start of the fetal period. This will result in a decreased stimulus to the metanephros (4). The kidneys, having a delay in differentiation, will have a prolongation of their ascension, resulting in the high ectopic position and the abnormally long ureters (4). The development of the adrenal gland is independent, accounting for their finding either above, alongside, or below the kidneys.

There are four kinds of intrathoracic kidneys: 1) true thoracic ectopia associated with a normal dorsal diaphragm, 2) eventration of the diaphragm, 3) diaphragmatic hernia (Bochdaleck's), either a congenital defect or an acquired herniation, and 4) traumatic diaphragmatic rupture with renal ectopia (4,7-14). Of all these, only 0.25% are associated with a Bochdaleck's hernia(15), as was the case of we report. These intrathoracic kidneys might have a deformed shape, nonrotated pelvis, and a long, normal ureter, although they are fully functional (4). Their present blood supply is derived from upper branches of the aorta, with involution of the previous branches.

Pulmonary manifestations of neurofibromatosis include interstitial lung disease, thoracic neuromas, vagal nerve neuromas, meningocele and kyphoscoliosis (16). No reports associating neurofibromatosis with defects in diaphragmatic development or ectopic kidneys were found.

Although there was history of repeated physical trauma during seizures, there was no reported history of blunt or severe abdominal trauma to explain the intrathoracic location of the kidney through the diaphragmatic hernia. Due to the absence of symptoms, an arteriogram to evaluate the position of the renal artery was deferred. Though asymptomatic, intrathoracic kidney should be considered in the differential diagnosis of a lung mass to avoid an unnecessary thoracotomy and nephrectomy.

References

1. Kelalis PP, Malek RS, Segura JW. Observations on renal ectopia and fusion in children. *J Urol* 1973;110:588.
 2. Summer TE, Volberg FM, Smolen PM. Intrathoracic kidney-diagnosis by ultrasound. *Ped Rad* 1982;12:78.
 3. Akman D, Klein RC, Labrosky DM. Intrathoracic kidney. *J Louisiana State Med Soc* 1980; 132: 82-83.
 4. Donat SM, Donat PE. Intrathoracic kidney: a case report with a review of the world literature. *J Urol* 1988;140:131-133.
 5. Van De Graaff KM, Fox SI. Urinary system, fluid and electrolyte balance. In: *Concepts of Human Anatomy and Physiology*. Dubuque: WMC Brown, 1989;799.
 6. Maizels M. Normal development of the urinary tract. In: Walsh PC, Petrin AB, Stamey TA, Vaughan ED: *Campbell's Urology*. Philadelphia: WB Saunders, 1992; 1301-1317.
 7. Baurys W, Servoss S. Eventration of the diaphragm: report of a case involving the kidney. *Urol Cutan Rev* 1949;53:535.
 8. Spillane RJ, Prather GC. Right diaphragmatic eventration with renal displacement: case report. *J Urol* 1952;68:804.
 9. Fleischner FC, Robins SA, Abrahams M. Renal ectopia and congenital diaphragmatic hernia. *Radiology* 1950;55:24.
 10. Von Mikulicz-Radecki F. Ein Beitrag zur Kongenitalen, intrathorakalen Nierendystopie. *Z Gynak* 1922; 46:1718.
 11. Williams RG, Tillinghast AC. Diaphragmatic herniation of the kidney. *Radiology* 1949;53:566.
 12. Barret NR. Right retroperitoneal diaphragmatic hernia. *Brit J Surg* 1945;32:421.
 13. Bell JC, Heublein GW, Hammer HJ. The roentgen examination of the urinary tract. *Amer J Roentgen* 1945;53:527.
 14. Budgen WF. Two cases of intrathoracic kidney. *Dis Chest* 1950;17:357.
 15. Khan AB. Renal thoracic ectopia: a case report. *Scand J Urol Nephrol* 1994;28:413-414.
 16. Schwarz MI, Cherniack RM, King TE. Diffuse alveolar hemorrhage and other rare infiltrative disorders. In: Murray JF, Nadel JA: *Textbook of Respiratory Medicine*. Philadelphia: WB Saunders, 1994; 1904.
-