

Circumferential Stabilization of the Thoracolumbar Junction Via Posterior-Only Approach for the Management of Burst Fractures

Juan C. Vicenty, MD; Fanor M. Saavedra, MD; Juan A. Vigo, MD; Emil A. Pastrana, MD

Objective: The management of thoracolumbar burst fractures often includes combined anterior/posterior approaches with prolonged operative time and complications. The transpedicular approach offers a posterior-only approach with circumferential reconstruction and decompression. We aim to present the experience of a single center in the management of thoracolumbar burst fractures using a posterior-only approach for circumferential stabilization and report on this technique's effectiveness in restoring the alignment of the thoracolumbar junction.

Methods: A case review of the medical records of patients admitted to the adult neurosurgery service (from January 2011 through June 2014) with traumatic non-pathological thoracolumbar burst fractures and subsequently treated with a transpedicular corpectomy (including the placement of an expandable cage) was performed, retrospectively.

Results: A total of 20 patients underwent a posterior transpedicular corpectomy consisting of anterior column reconstruction using an expandable cage with supplementary posterior fixation within 72 hours of injury. The average pre-operative canal compromise was 69%. The average pre-operative kyphotic angle was 21.6°. The average post-operative kyphotic angle was 5.15°, with an average correction of 16.45°. There were 11 patients with pre-operative neurological compromises, of which patients, 8 experienced variable degrees of recovery. The average operating time was 410.5 minutes (range, 240–550 min). The average blood loss was 880 mL (range, 650–1500). Three patients experienced complications during surgery; 1 patient died.

Conclusion: The transpedicular approach for circumferential reconstruction and stabilization provides an alternative technique for the management of thoracolumbar fractures, having an acceptable risk and the associated lower morbidity of a posterior-only approach. [*P R Health Sci J* 2018;37:224-229]

Key words: Transpedicular, Corpectomy, Thoracolumbar, Burst

The thoracolumbar junction anatomy presents a junctional point between the thoracic kyphosis and the lumbar lordosis. This junction lacks the protection from the rib cage proximally and the pelvis distally making it vulnerable to axial compression.

This anatomical region represents the most common site for burst fractures in the adult population (1–2). Due to the high-energy mechanisms associated with this traumatic pathology, there is a 20% incidence of spinal cord injury, along with associated non-spinal pathologies such as visceral and vascular injuries (2). Thoracolumbar burst fractures with spinal cord injury present a biomechanically complex scenario, with a disruption of the anterior column with spinal cord compression and posterior element involvement in a transitional area that is subject to high biomechanical stress (3–6).

The management of these fractures often entails combined approaches to restore the anterior column, along with supplemental posterior instrumentation and spinal cord

decompression (7-8). The ability to directly decompress the spinal canal upon the occurrence of a neural insult is one of the advantages of anterior surgery, as is decreasing the chances of the development of progressive kyphosis by correcting the deficiency of the anterior column. However, the more involved approach is one of the disadvantages of this surgery, as are the fact that many spinal surgeons are not familiar with it and that the potential not only for thoracotomy pain but also for pulmonary and vascular complications exists.

Department of Surgery, Neurosurgery Section, University of Puerto Rico Medical Sciences Campus, San Juan, Puerto Rico

The author/s has/have no conflict/s of interest to disclose.

Address correspondence to: Emil A. Pastrana, MD, Department of Surgery, Neurosurgery Section, University of Puerto Rico Medical Sciences Campus, PO Box 365067, San Juan, PR 00936. Email: emilapastrana@gmail.com

Hunt et al described a technique for a combined anterior and posterior reconstruction through a single posterior approach, eliminating the need for the anterior approach. (9). Posterior approaches are attractive due their avoidance of anteriorly located visceral and vascular structures, which can often be compromised in thoracolumbar fractures. However due to the anterior column disruption, there remains a concern that posterior approaches result in suboptimal reconstruction. It is our desire to explore our experience with the transpedicular approach as an alternative for the management of traumatic non-pathological thoracolumbar burst fractures with spinal cord compression.

Methods

The medical records of patients admitted to the adult neurosurgery service with traumatic non-pathological thoracolumbar burst fractures from January 2011 through June 2014 were reviewed retrospectively. A total of 75 patients with thoracolumbar burst fractures were identified. After all the treatment options were explained, 20 (of the 75) patients with severe canal compromise anterior column disruption and posterior ligamentous complex (PLC) disruption were selected to undergo surgery using a posterior-only approach consisting of a transpedicular corpectomy with anterior column reconstruction via expandable-cage placement and posterior instrumentation and fusion. All the patients were assessed pre-operatively with computed tomography of the complete spine to identify and classify the fracture and to obtain radiological parameters detailing the extent of the spinal canal compromise and the kyphotic angle. Magnetic resonance imaging (MRI) was obtained in all the patients to identify both cord contusion and damage to the posterior ligamentous complex. Indications for surgery were decided per the *Thoracolumbar Injury Classification and Severity (TLICS)* scale (10–11). The analysis included the following factors: estimated blood loss, operative time, potential complications, pre-operative and post-operative neurological status, pre-operative and post-operative kyphotic angle, spinal canal compromise, time to discharge, and neurological recovery. Patients were followed up in clinics at 3, 6, and 12 months. Neurological function and recovery were evaluated using the *American Spinal Cord Injury Association (ASIA) Impairment Scale (AIS)*. The AIS scores were assessed on admission and at discharge (Table 1). Institutional review board approval was obtained to perform this study at the University of Puerto Rico.

Description of procedure

The patient with a thoracolumbar burst fracture (Figure 1) is positioned prone on a radiolucent spine table. Pre-operative antibiotics were administered within 1 hour of the incision, every 4 hours, intraoperatively, and for 24 hours, post-operatively. The posterior elements are exposed via a midline approach, and pedicle screws are inserted in the 2 levels above and 2 levels below the involved vertebral segment. A complete

laminectomy is performed at the level of the fracture and 1 level above. The inferior articular process of the level above the fracture is resected along with the superior and inferior articular processes, pars interarticularis, and pedicles of the affected level. This permits adequate visualization of the disc spaces and the exiting nerve roots. Radical discectomies are performed and the endplates are prepared for graft placement. Before starting the corpectomy, a temporary rod is placed contralateral to the side on which the corpectomy is to be performed to prevent translation of the vertebral column and cord compression.

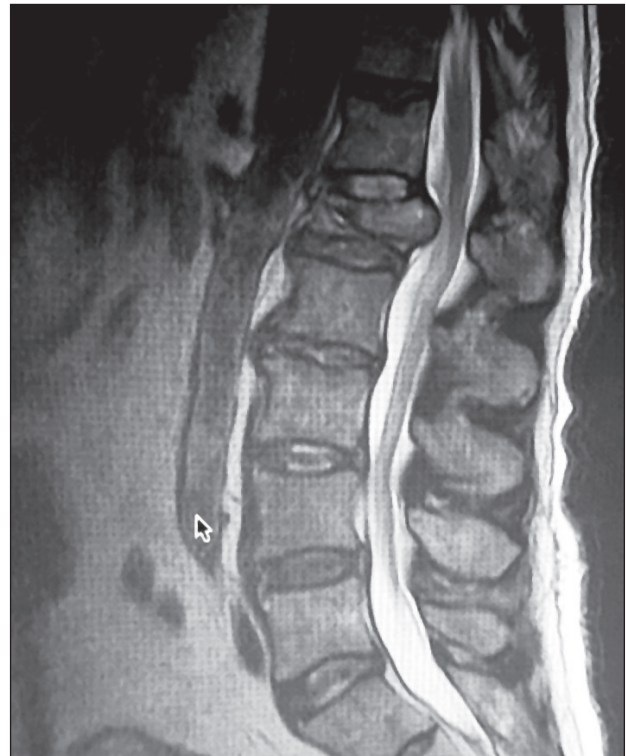

Figure 1. L1 thoracolumbar burst fracture with retropulsion and spinal cord compression.

The corpectomy is then performed via the window between the exiting nerve roots, using a high-speed drill, large curettes, and Kerrison and pituitary rongeurs, while paying special attention not to injure the dura mater. A fully compressed expandable titanium cage is packed with autograft bone and demineralized bone matrix and inserted between the neural elements parallel to the exiting nerve roots. After the cage is inserted into the anterior column, it is rotated to the proper position (Figure 2). Fluoroscopy is used to assess and confirm adequate cage positioning. The cage is then expanded to obtain maximal contact with the endplates (Figure 2). The posterior pedicle screw instrumentation is finalized and posterolateral arthrodesis performed with the decortication of all the bone surfaces and the placement of the autograft and demineralized bone matrix (mixed with 1 gram (g) of powdered vancomycin); the incision is then closed in the standard fashion. A subfascial drain is left in the patient for a period of 24 hours.

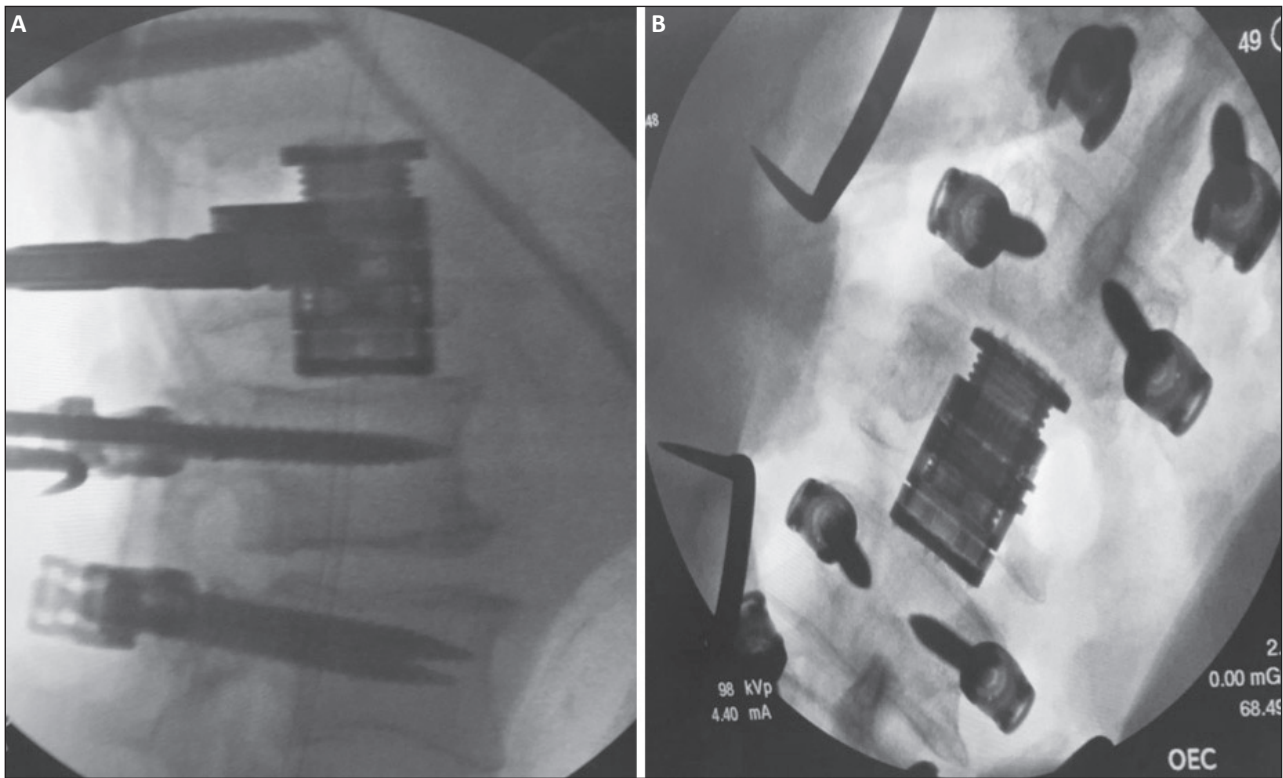


Figure 2. Reconstruction of the anterior column of the thoracolumbar spine with an expandable cage: A. lateral x-ray; B. anterior/posterior x-ray.

Results

A total of 20 patients underwent a posterior transpedicular corpectomy consisting of anterior column reconstruction using an expandable cage with supplementary posterior fixation within 72 hours of injury. For all patients the etiology involved a high-energy mechanism. All the patients underwent circumferential decompression of the spinal cord. All patients were instrumented with pedicle screws 2 levels above and 2 levels below the pathology, arthrodesis was performed, using a combination of an autograft and a demineralized bone matrix scaffold to achieve fusion. The cohort consisted of 17 males and 3 females, with an average age of 49.2 years (range, 18–83 years). All patients had a TLICS score of 5 or above, indicating the need for surgical intervention.

Mechanism of injury

Regarding the injury mechanisms of the 20 patients in the study, 13 had been involved in falls from a height greater than 15 feet, 4 had been involved in motor vehicle accidents, and 3 had been involved in all-terrain vehicles accidents.

Radiological parameters

The mean pre-operative canal compromise was 69%, with the range being 46 to 90%, the median, 69%, and the standard deviation (SD), 15. The mean pre-operative kyphotic angle was 21.6°, with the range being 15° to 25°, the median, 23°, and the SD, 3°. The average post-operative kyphotic angle was 5.15°

with the range being 2° to 8°, the median, 5°, and the SD, 2°. The mean correction obtained was 16.45°, with the range being 10° to 21°, the median, 18°, and the SD, 1°.

Neurological compromise

There were 11 patients with pre-operative neurological compromise. The AIS score distribution consisted of 4 patients with a score of A, 2 with a score of B, 3 with a score of C, 2 with a score of D, and 9 with a score of E. In the post-operative period, 8 patients with neurological deficits experienced recovery, as evidenced by improvements in their AIS scores (Table 1). The 3 patients who did not show any improvements in their neurological statuses had MRI findings of extensive hematomyelia with extensive tissue disruption. No patient developed any post-operative neurological deficits (Table 1).

Surgery

The average operating time was 410.5 minutes (min) (range, 240–550 min). The average blood loss was 880 milliliters (mL) (range, 650–1500 mL).

Complications

There was 1 patient with an anterior dural tear that occurred during bone decompression. As this repair tends to be difficult, it was managed with a sling graft technique, consisting of a patch of synthetic dural substitute was passed anteriorly, from side to side, wrapped posteriorly, and sutured with braided nylon 4-0

Table 1. Demographics, Radiological Parameters, Operative Parameters, Complications, Neurological Outcomes

Age	Sex	Diagnosis	Comorbidity	TLCIS	AIS		Canal compression	Kyphotic Angle		OR Time	EBL	Complication	Time to discharge
					Pre-op	Post-Op		Pre-Op	Post-Op				
65	M	L1 burst	HTN	7	A	B	80%	25°	5°	480 min	650 ml	None	8 days
83	M	L1 burst	Afib, HTN	5	E	E	56%	20°	7°	360 min	650 ml	Pneumonia/Death	-----
25	M	L1 burst	IVDA	8	D	D	60%	24°	5°	420 min	800 ml	None	12 days
67	M	L2 burst	HTN	5	E	E	70%	23°	7°	480 min	2500 ml	None	14 days
54	F	L2 burst	None	5	E	E	51%	25°	6°	460 min	1100 ml	Wound infection	31 days
40	M	L1 burst	None	8	B	C	90%	23°	4°	460 min	800 ml	None	12 days
41	M	T11 burst	None	7	A	C	90%	22°	5°	260 min	1000 ml	None	18 days
18	M	T11 burst	None	8	B	D	87%	23°	6°	560 min	750 ml	None	7 days
29	M	T11 burst	None	5	E	E	68%	24°	7°	240 min	750 ml	None	9 days
71	F	T11 burst	DM, HTN	8	C	E	56%	19°	5°	240 min	850 ml	None	21 days
55	M	L1 burst	None	5	E	E	65%	21°	5°	360 min	900 ml	None	19 days
71	M	T11 burst	None	5	E	E	70%	18°	3°	360 min	1100 ml	DVT	8 days
57	F	T12 burst	None	7	A	A	90%	23°	7°	420 min	500 ml	None	15 days
43	M	L1 burst	None	7	A	A	90%	21°	3°	360 min	950 ml	None	8 days
60	M	L1 burst	None	5	E	E	50%	24°	3°	480 min	950 ml	None	9 days
49	M	T12 burst	None	8	C	D	50%	20°	5°	500 min	950 ml	None	11 days
49	M	L1 burst	None	5	E	E	70%	20°	5°	440 min	700 ml	None	7 days
44	M	L2 burst	None	8	C	E	46%	23°	3°	360 min	1000 ml	None	14 days
35	M	L1 burst	None	5	E	E	60%	19°	2°	550 min	750 ml	None	7 days
27	M	L1 burst	None	8	D	E	75%	15°	5°	420 min	950 ml	None	10 days

Explanatory note: This table presents the demographics, radiological parameters, operative parameters, complications, and neurological outcomes.

stitches. Multiple valsalva maneuvers were done to confirm adequate dural enhancement and closure.

Post-operative complications were seen in 3 patients and consisted of the following: 1 case of wound infection with *Acinetobacter Baumannii* that needed aggressive debridement and 6 weeks of intravenous antibiotics and which subsequently resolved, 1 case of a deep venous thrombosis, and 1 case of pneumonia, which resulted in death.

The patient who expired was an 80-year-old male with atrial fibrillation and hypertension who developed pneumonia complicated with sepsis and shock and died from multi-organ failure.

Follow-Up

There were no patients lost to follow-up at the 3-, 6-, or 12-month intervals. All the patients maintained the AIS scores that were seen at discharge. Solid fusion (as evidenced by computed tomography) was obtained in 18 patients. The average sagittal alignment loss was less than 5° in all the patients. Two patients showed radiographic evidence of pseudarthrosis, though without clinical symptoms, and it was decided that they should be followed clinically.

Discussion

In this study we describe an institutional case series describing the use of the transpedicular approach for circumferential reconstruction and decompression of patients with traumatic non-pathological thoracolumbar burst fractures. The transpedicular approach is an alternative to a

combined anterior/posterior approach for the management of complex fractures.

The combined anterior/posterior approach uses a retroperitoneal corridor for the reconstruction of the anterior column and subsequent placement of posterior instrumentation. The anterior approach possesses significant risks: the aorta, inferior vena cava, and lymphatic system chain are in close proximity; the neural elements are encountered at a late stage; and the procedure necessitates a prolonged operative time and involves dual incisions, all of which must be taken into account when contemplating the use of this approach (12–13).

Lu et al examined the complication rates associated with both an anterior approach and an anterior/posterior approach for single-level corpectomies in the thoracolumbar region. In the anterior approach, the mean estimated blood loss (EBL) was 1288, the mean operative time (MOP) was 432 minutes, and the complication rate (CR) was 31%. In the anterior/posterior approach, the mean estimated blood loss was 3540 mL, the mean operative time was 934 minutes, and the complication rate was 40% (13).

Similarly, Wiggins et al reported on a series of thoracolumbar fractures treated with either an anterior or a posterior approach. The mean EBL was 1878 mL in the anterior group and 2541 mL in the posterior group. The MOP was 438 minutes in the anterior group and 569 minutes in the posterior group. The complication rate was not described (14).

Nonetheless, the transpedicular (posterolateral) approach is a not a panacea. It is a technically demanding procedure with a narrow and constrained path that, if done improperly, could

cause injury to neural structures, significant blood loss, and a poor outcome. Therefore adequate 3-dimensional visualization of the operative corridor is of utmost importance. The ability to place an expandable cage using this technique makes it attractive as a way to restore adequate alignment and reconstruct the anterior column (15–17).

Our results demonstrate that the transpedicular approach is a viable alternative to current techniques for treating thoracolumbar fractures, having both an acceptable risk and manageable to negligible complications. Our average blood loss was 880 mL, and the average operative time was 6.8 hours. Another important variable that was addressed was the ability to correct such deformities as occurred at the thoracolumbar junction. The average pre-operative kyphotic angle was 21.6°; the average correction was 16.45°, resulting in an average post-operative kyphotic angle of 5.15°. This represents a robust correction to re-establish the normal anatomical environment in the thoracolumbar junction. Our complication rate was 15%, and we had 1 death. However, reliable morbidity and mortality statistics cannot be deduced because of the small sample size. It is always important to carefully select which patients might benefit from this approach; if a less invasive approach is feasible, it should be undertaken, to minimize complication in patients that are not healthy enough to undergo this complicated procedure. Our series had 1 mortality, an 80-year-old patient with atrial fibrillation and with a Karnofsky score of 90. This patient's advanced age and comorbid condition signify that he may have fared better with a less invasive procedure. Nonetheless age should not be a factor, and complications may arise even in low-risk procedures that require a stepwise post-operative mobilization regimen.

Neurological compromise was observed in 11 patients in our cohort 8 of whom demonstrated increases in their AIS scores (for a 72% total improvement). Compared to those of Hoffstetter et al, whose patients showed a 69% improvement, our outcomes are within the expected results (17). Improvements in the neurological state of a patient with a thoracolumbar fracture are dependent on the extent of spinal cord damage present at the moment of intervention. In our cohort, patients that did not improve had evidence of significant spinal cord damage, as confirmed by MRI.

In regards to comparison with other techniques, it cannot be stated that 1 procedure is superior to the others, due to the absence of other series comparing 1 technique to another. However the transpedicular approach offers a single-stage circumferential technique for dealing with a common pathological entity using a posterior-only that is familiar to spine surgeons and that shows a trend towards superiority.

Conclusion

The transpedicular approach for circumferential reconstruction and stabilization provides an alternative technique for the management of thoracolumbar fractures,

having an acceptable risk and the associated lower morbidity of a posterior-only approach. The results presented demonstrate the transpedicular approach to be a robust technique for restoring adequate alignment at the thoracolumbar junction while at the same time reducing the inherent risks of the double-stage anterior/posterior approach.

Resumen

Objetivo. El manejo de fracturas toracolumbares del tipo “burst” incluye comúnmente abordajes quirúrgicos combinados de forma anterior/posterior con un tiempo operatorio prolongado y asociado a complicaciones. El abordaje transpedicular ofrece una vía de manejo solo posterior para obtener una descompresión y reconstrucción circumferencial. Presentamos la experiencia de un centro de trauma en el manejo de fracturas toracolumbares tipo “burst” utilizando la vía transpedicular. **Métodos.** Se realizó un estudio retrospectivo de los expedientes médicos de pacientes admitidos al servicio de neurocirugía con fracturas toracolumbares traumáticas tipo “burst” que fueron manejadas con corpectomias transpediculares y reconstrucción en el periodo de enero 2011 a junio 2014. **Resultados.** Un total de 20 pacientes fueron tratados con corpectomias transpediculares con reconstrucción de la columna anterior con cajas expandible y fijación posterior suplementaria. El por ciento promedio de estreches del canal espinal era de 69%. El ángulo cifótico pre-operatorio era de 21.6° El promedio del ángulo cifótico post-operatorio era de 5.15°, con un promedio de corrección de 16.45°. Hubo un total de 11 pacientes con déficit neurológico pre-operatorio, de los cuales 8 tuvieron mejoría en su estado neurológico. El tiempo promedio de cirugía fue de 410.5 minutos (rango de 240 – 550 minutos). El promedio de pérdida de sangre fue de 880 mL (rango de 650 – 1550 mL). **Ocurrieron complicaciones en 3 pacientes, 1 paciente falleció.** **Conclusión.** El abordaje transpedicular ofrece una opción alternativa de reconstrucción circumferencial para el manejo de fracturas toracolumbares con un riesgo aceptado de baja morbilidad y mortalidad.

References

1. Bradford DS, Akbarnia BA, Winter RB, Seljeskog EL. Surgical stabilization of fracture and fracture dislocations of the thoracic spine. *Spine (Phila Pa 1976)* 1977;2:185–196.
2. McCulloch PT, France J, Jones DL, et al. Helical computed tomography alone compared with plain radiographs with adjunct computed tomography to evaluate the cervical spine after high-energy trauma. *J Bone Joint Surg Am* 2005;87:2388–2394.
3. Denis F. The three column spine and its significance in the classification of acute thoracolumbar spinal injuries. *Spine (Phila Pa 1976)* 1983;8:817–831.
4. Magerl F, Aebi M, Gertzbein SD, Harms J, Nazarian S. A comprehensive classification of thoracic and lumbar injuries. *Eur Spine J* 1994;3: 184–201.
5. Bohlman HH. Treatment of fractures and dislocations of the thoracic and lumbar spine. *J Bone Joint Surg Am* 1985;67:165–169.

6. Flanders AE. Thoracolumbar trauma imaging overview. *Inst Course Lect* 1999;48:429–431.
 7. Schnee CL, Ansell LV. Selection criteria and outcome of operative approaches for thoracolumbar burst fractures with and without neurological deficit. *J Neurosurg* 1997;86:48–55.
 8. Oskouian RJ Jr, Shaffrey CI, Whitehill R, et al. Anterior stabilization of three-column thoracolumbar spinal trauma. *J Neurosurg Spine* 2006;5:18–25.
 9. Hunt T, Shen FH, Arlet V. Expandable cage placement via a posterolateral approach in lumbar spine reconstructions. Technical note. *J Neurosurg Spine* 2006;5:271–274.
 10. Lee JY, Vaccaro AR, Lim MR, et al. Thoracolumbar injury classification and severity score: a new paradigm for the treatment of thoracolumbar spine trauma. *J Orthop Sci* 2005;10:671–675.
 11. Rihn JA, Anderson DT, Harris E, et al. A review of the TLICS system: a novel, user-friendly thoracolumbar trauma classification system. *Acta Orthop* 2008;79:461–466.
 12. Oskouian RJ Jr, Johnson JP. Vascular complications in anterior thoracolumbar spinal reconstruction. *J Neurosurg* 2002;96:1–5.
 13. Lu DC, Lau D, Lee JG, Chou D. The transpedicular approach compared with the anterior approach: an analysis of 80 thoracolumbar corpectomies. *J Neurosurg Spine* 2010;12:583–591.
 14. Wiggins GC, Rauzzino MJ, Shaffrey CI, et al. A new technique for the surgical management of unstable thoracolumbar burst fractures: a modification of the anterior approach and an outcome comparison to traditional methods. *Neurosurg Focus* 1999 Jul 15;7:e3.
 15. Hussain NS, Hanscom D, Oskouian RJ Jr. Chyloretroperitoneum following anterior spinal surgery. *J Neurosurg Spine* 2012;17:415–421.
 16. Jandial R, Kelly B, Chen MY. Posterior-only approach for lumbar vertebral column resection and expandable cage reconstruction for spinal metastases. *J Neurosurg Spine* 2013;19:27–33.
 17. Hofstetter CP, Chou D, Newman CB, Aryan HE, Girardi FP, Härtl R. Posterior approach for thoracolumbar corpectomies with expandable cage placement and circumferential arthrodesis: a multicenter case series of 67 patients. *J Neurosurg Spine* 2011;14:388–397.
-