

## An Unexpected Cause of Sepsis: Keep Pursuing the Source of Infection

Javier Ramos-Rossy, MD; Yomayra Otero-Domínguez, MD;  
Jossette Axtmayer, MD; José Torres-Palacios, MD;  
Onix Cantres, MD; William Rodríguez-Cintrón, MD, MACP

**An 86-year-old man was found with altered mental status, fever and aphasia. His physical exam revealed nuchal rigidity but no other meningeal signs. Because the patient's mental status was declining, he was intubated and placed in mechanical ventilation. His head CT scan was unremarkable, without evidence of mass effect. A lumbar puncture yielded cerebrospinal fluid that was remarkable for the presence of gram-positive cocci in pairs. His blood cultures showed gram-negative bacilli. Given the presence of these organisms, a polymicrobial infection was suspected. An abdomino-pelvic CT scan showed a multi-septated abscess within the right hepatic lobe. CT-guided percutaneous drainage was performed and a specimen for culture obtained, which grew *Klebsiella pneumoniae*. After receiving intravenous antibiotics and supportive care, the patient showed clinical improvement. In this patient, there was a central nervous system infection secondary to bacteremia in the setting of an intrabdominal infection. The inquiring clinician should take note that whenever a polymicrobial infection is evidenced, more than one site of infection should be considered in the differential diagnosis. [P R Health Sci J 2019;38:118-119]**

*Key words: Sepsis, Meningitis, Polymicrobial infection, Bacteremia*

**M**eningitis is an inflammatory disease characterized by the bacterial invasion to the subarachnoid space (1). It is one of the 10 most common causes of death in the world (2). It is estimated that 1.2 billion cases of meningitis occur annually, resulting in approximately 135,000 deaths (2). Thus, diagnosis and early treatment are paramount in order to prevent fatal outcomes.

### Case Report

An 86-year-old man with a medical history of diabetes mellitus type II, hypertension, hyperlipidemia, and cerebrovascular accident and who (until 3 days prior to admission) independently managed his activities of daily living was found to have an altered mental status, aphasia, and a quantified fever (40°C). He did not have involuntary relaxation of sphincters or involuntary movements. During the physical examination, his neurological evaluation showed him to have normal motor tone and strength, preserved sensation, intact cranial nerves, a Glasgow Coma Scale score of 10 (of 15), nuchal rigidity, negative Brudzinski's sign, and negative Kernig's sign. Laboratory studies were consistent with diabetic ketoacidosis, sepsis, and acute kidney injury. Due to his worsening neurological status, the patient required endotracheal intubation and mechanical ventilatory support. A head computed tomography (CT) scan without contrast was unremarkable, with no mass effect. The patient was admitted to the medical intensive care unit, where empiric broad spectrum intravenous (IV) antibiotics (vancomycin, ceftriaxone, and ampicillin), steroids, and vasopressor therapy

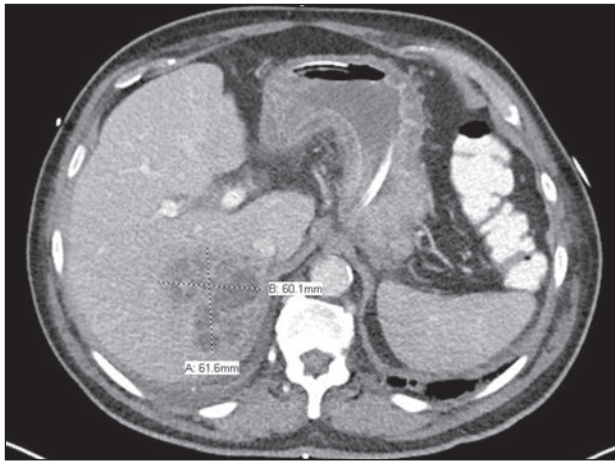
with norepinephrine were started. A lumbar puncture obtained after the initiation of antibiotic therapy was remarkable for a white blood cell count of 2,144 per cmm (normal range 0–10 per cmm), with 98% neutrophils and 2% lymphocytes, a protein level of 188 mg/dL (normal range: 15–45 mg/dL), a glucose level of 118 mg/dL (normal 50–80 mg/dL), and gram-positive cocci in pairs. Four blood culture bottles were reported positive for gram-negative bacilli. In view of the presence of multiple organisms (which, as mentioned previously, had been cultured in sterile fluids), a polymicrobial infection (such as an abscess) was suspected. An abdominal–pelvic CT scan was performed; it showed a multi-septated macroabscess in the right hepatic lobe (6.0 cm x 6.2 cm x 6.2 cm), as well as a small stone lodged in the neck of the gallbladder. CT-guided percutaneous drainage of the abscess isolated a pansensitive *Klebsiella pneumoniae*.

The patient experienced clinical improvement, after which (on day 3), a successful extubation was performed, with no neurological sequelae. He was discharged home after undergoing IV antibiotics therapy for 2 weeks. In this case, the presence of bacteremia and meningitis (with multiple etiologies) were most likely secondary to the finding of a multi-septated macroabscess

VA Caribbean Healthcare System, San Juan, PR

*The author/s has/have no conflict/s of interest to disclose.*

**Address correspondence to:** William Rodríguez-Cintrón, MD, MACP, Pulmonary and Critical Care (111-E), VA Caribbean Healthcare System, 10 Casia St., San Juan, PR 00921-3201. Email: william@prmail.net



**Figure 1.** Right hepatic lobe with multiseptated macroabscess

in the right hepatic lobe. As can be seen, then, it is important to always search for a polymicrobial infectious process such as an abscess when multiple bacteria (having been cultured in different normally sterile fluids) are present; appropriate drainage and intravenous antibiotics are imperative if there is to be an effective clinical response.

### Discussion

Acute bacterial meningitis is recognizable by its triad of symptoms: an elevated temperature, a stiff neck, and changes in mental status. The white blood cell count is usually elevated. Positive blood cultures are seen in 50 to 90% of the patients who have bacterial meningitis. Approximately 50 to 90% of patients with bacterial meningitis have positive blood cultures. Samples of cerebrospinal fluid (CSF) from patients with bacterial meningitis show elevated white blood cell counts (more than 500 cells/ $\mu$ l) with high neutrophil levels, elevated protein levels (more than 1 g/l), and a glucose CSF/blood ratio of less than 0.4 (1). Early initiation of empirical antibiotic therapy is recommended considering the possible pathogen causing the infection (1,3). Common bacterial pathogens among adults over 50 years of age are: *Streptococcus pneumoniae*, *Neisseria meningitidis*, and *Listeria monocytogenes* (3). Immunocompetent adults over 50 years of age with normal renal function should be empirically treated with the following regimen (until culture and susceptibility data are available): ceftriaxone, 2 grams, IV, every 12 hours (or cefotaxime, 2 grams, IV, every 4 to 6 hours), plus vancomycin, 15 to 20 mg/kg, IV, every 8 to 12 hours, plus ampicillin, 2 grams, IV, every 4 hours (3). Adjunctive dexamethasone (10 mg every 6 hours for 4 days) should be administered shortly before or at the same time as the first dose of antibiotics (3). The neurologic complications of bacterial meningitis include impaired mental status, seizures, focal neurologic deficits, cerebrovascular abnormalities, sensorineural hearing loss, and neurocognitive impairment (4). Early recognition is important since appropriate management can reduce mortality. Identifying

the cause of meningeal infection is also indispensable so that patients with this fatal disease can be treated and cured. If there is concomitant bacteremia, but with different organisms, a polymicrobial infectious process such as an abscess should be considered and sought. In our case, a hepatic abscess (HA) was identified as being the etiology of the bacteremia and meningitis. HA is an encapsulated collection of purulent material localized within the liver as consequence of an infectious process. (5). Biliary tract disease is the most common cause of HA nowadays; it is responsible for 30 to 50% of cases in United States (5). In our patient, a small stone at the neck of the gallbladder (and which caused acute/subacute cholecystitis) was the most likely originator of the abscess. Mortality was previously around 80% but has decreased to 10 to 40% with current treatment options, which include IV antibiotics and interventional procedures (5). Thus, as was the case with our patient, abscess drainage and IV antibiotics are essential for the appropriate treatment and potential cure of this disease.

### Resumen

Un hombre de 86 años de edad fue encontrado con estado mental alterado, fiebre y afasia. Su examen físico mostraba rigidez nuchal sin otros signos meníngeos. Debido al deterioro del estado mental, el paciente fue intubado y colocado en ventilación mecánica. Una tomografía computadorizada (CT, por sus siglas en inglés) de cabeza no demostró anomalías agudas y ni efecto de masa. La punción lumbar demostró cocos gram positivos en pares en el líquido cefalorraquídeo. Los cultivos de sangre demostraron bacilos gram negativos. En vista de los múltiples organismos cultivados en diferentes fuentes estériles se sospechaba una infección polimicrobiana. Un CT abdominopélvico demostró un absceso multiseptado en el lóbulo hepático derecho que resultó positivo para *Klebsiella pneumoniae* luego de ser drenado. El paciente tuvo mejoría clínica al recibir antibióticos y terapia de sostén. Este paciente tuvo una infección del sistema nervioso central secundaria a bacteremia por una infección intrabdominal. El clínico inquisitivo debe de estar consciente de que cuando se evidencie que esté ocurriendo una infección polimicrobiana, más de un sitio de infección se debe considerar en el diagnóstico diferencial.

### References

- Hoffman O, Weber RJ. Pathophysiology and Treatment of Bacterial Meningitis. *Ther Adv Neurol Disord* 2009;2:1-7.
- Scheld WM, Koedel U, Nathan B, Pfister HW. Pathophysiology of Bacterial Meningitis: Mechanism(s) of Neuronal Injury. *J Infect Dis* 2002;186(S2):S225-S233.
- Tunkel AR, Hartman BJ, Kaplan SL, et al. Practice Guidelines for the Management of Bacterial Meningitis. *Clin Infect Dis* 2004;39:1267-1284.
- Fernandes D, Gonçalves-Pereira J, Janeiro S, et al. Acute bacterial meningitis in the intensive care unit and risk factors for adverse clinical outcomes: retrospective study. *Journal of Critical Care* 2014;29:347-350.
- Mavilia MG, Molina M, Wu GY. The Evolving Nature of Hepatic Abscess: A Review. *J Clin Transl Hepatol* 2016;4:158-168.