

# Small Bowel Bleeding: A Challenging Diagnosis

Fernando Baez-Corujo, MD; Walisbeth Class-Vázquez, MD;  
Jaime Martinez-Souss, MD

**The small intestine is an uncommon site for acute gastrointestinal (GI) bleeding. However, it is responsible for most cases in which the etiology of bleeding is not identified through endoscopy or colonoscopy. Despite great advances in technology, small bowel bleeding (SBB) is often a challenging diagnosis, requiring multiple blood transfusions, diagnostic procedures, and re-admissions. Consequently, it increases comorbidities, complications, and costs to the health care system. The presentation of SBB is diverse, and the etiology is dependent on the patient's age. It may require aggressive resuscitation and immediate bleeding-site localization for proper and successful care. The management is based on the etiology, the available technology, and physician expertise. We present a case of SBB in which multiple imaging and endoscopic procedures were required to identify the culprit lesion. Additionally, we review the most common etiologies, radiologic modalities, and endoscopic procedures available. [P R Health Sci J 2019;38:122-124]**

*Key words: Small bowel bleeding, Overt small bowel bleeding, enteroscopy, enterography, angiography*

**S**mall bowel bleeding (SBB) is a challenging diagnosis, despite use of advanced technology and proper endoscopic workup. Only 5 to 10% of gastrointestinal (GI) bleeding derives from a small bowel source, and the differential diagnosis is broad. Management is based on the etiology, available technology, and physician expertise.

## Case Report

A 67-year-old male with a history of complicated open prostatectomy requiring enterectomy with anastomosis presented with profuse black tarry stools. Denied abdominal pain, previous episodes and use of aspirin or non-steroidal anti-inflammatory drugs (NSAIDs). Laboratory results showed a drop in hemoglobin, from 12 g/dL to 9 g/dL. Platelet count, coagulation studies, liver and renal function tests were normal. Upper endoscopy was normal. Colonoscopy showed multiple blood clots, with blood coming from the small bowel. During ileoscopy, no bleeding site was identified. Further evaluation by push enteroscopy (up to proximal jejunum) failed to reveal the bleeding etiology. Capsule endoscopy (PillCam, Given Imaging) showed a segment with engorged mucosa and evidence of blood throughout the distal small bowel. A second-look colonoscopy with ileal intubation failed to identify the bleeding site. In view of the presence of overt SBB and patient's clinical stability, an abdominal CT angiography (CTA) was performed; it showed multiple, large, and engorged mesenteric vessels in the right lower quadrant suggestive of a large angiodysplasia. Therapeutic angiography revealed active bleeding from an arteriovenous malformation; hemostasis was achieved after coil embolization of the ileocolic branch. Although he required multiple

transfusions and procedures during the hospitalization, the patient was successfully discharged and remained symptom free.

## Discussion

SBB is a relatively uncommon clinical entity. Angiodysplasia and NSAID-induced small bowel lesions are the most common etiologies in patients 40 years old or older. Other causes of SBB are described in Table 1. Detailed medical history is fundamental for a proper assessment because a bleeding diathesis, medications, and surgical history may provide clues to diagnosis.

Clinical presentation depends on the etiology and site of the SBB. Intensive care unit admission should be considered in hemodynamically unstable patients requiring monitoring and aggressive resuscitation measures. Blood transfusions must be individualized, but restrictive strategy (when hemoglobin is less than 7 g/dL) has been associated with lower mortality in patients exposed to a therapeutic endoscopic procedure (1).

SBB site is usually inaccessible to endoscopists due to lengthiness and excess mobility. Finding it usually requires multiple diagnostic investigations, hospitalizations, and transfusions, ultimately delaying its conclusive identification. Wide range of diagnostic and therapeutic procedures are available, all of which depend on local expertise and accessible technologies.

---

Department of Medicine, Division of Gastroenterology, VA Caribbean Healthcare System, San Juan, PR

*The author/s has/have no conflict/s of interest to disclose.*

**Address correspondence to:** Walisbeth Class- Vázquez, MD, VA Caribbean Healthcare System, Casia #10, San Juan, PR 00921. Email: walisbeth.class-vazquez@va.gov

Overt SBB is diagnosed when a patient presents with either melena or hematochezia, with the source of bleeding being found in the small intestine. Occult SBB is reserved for those with iron-deficiency anemia, with or without stools positive for occult blood, who are found to be bleeding from the small bowel (2). The term “obscure GI bleeding” should be reserved for those patients in whom the source of bleeding is not known after proper radiographic and endoscopic evaluation, including capsule endoscopy (CE) and/or enteroscopy (2).

**Table 1.** Common and rare causes of small bowel bleeding. Adapted from the ACG Clinical Guideline: Diagnosis and Management of Small Bowel Bleeding (3).

Common Causes		Rare Causes
Under 40 years old	Over 40 years old	Henoch–Schoenlein purpura
Inflammatory bowel disease	Angioectasia	Amyloidosis
Dieulafoy lesions	Dieulafoy lesions syndrome	Osler–Weber–Rendu
Neoplasia	Neoplasia	Hemobilia
Meckel diverticulum	NSAID ulcers	Aortoenteric fistula
Polyposis syndromes (e.g. Peutz–Jeghers Syndrome)		Small bowel varices and/or portal hypertensive enteropathy Hemosuccus pancreaticus

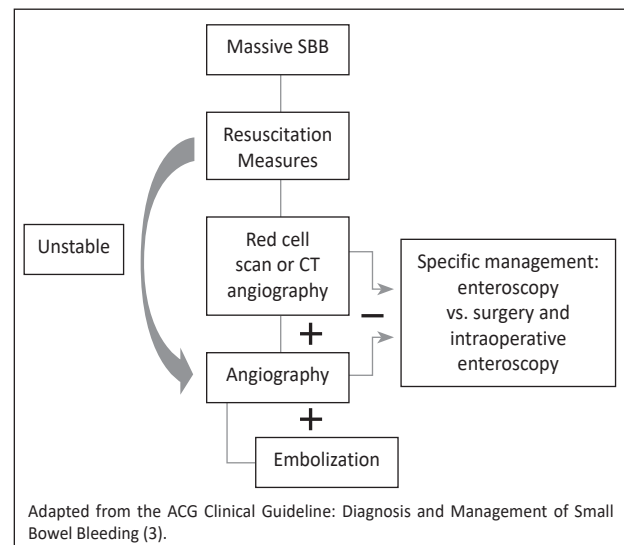
In acute overt massive SBB, angiography is indicated in hemodynamically unstable patients, since it provides the opportunity for therapeutic interventions. Bleeding rate required for adequate site detection is around 0.5 to 1.0 ml/min (3). For hemodynamically stable patients, an endoscopic workup should be the first step. Second-look endoscopic studies are recommended to exclude missed lesions (4). These have a diagnostic yield of 2 to 25% in patients undergoing repeated esophagogastroduodenoscopy and of 6 to 23% on repeated colonoscopy (2). CE is part of the endoscopic toolbox available for hemodynamically stable patients after a negative upper and lower GI evaluation (2). Furthermore, CE findings can provide guidance for subsequent enteroscopy. Push enteroscopy allows evaluation of the small bowel, about 70 cm distal of the ligament of Treitz (5). Single or double balloon, deep and spiral enteroscopy, are additional endoscopic tools in the evaluation of small bowel (2). Intraoperative enteroscopy is typically considered last resource, due to its high morbidity. It is usually reserved for rare cases, in which other modalities failed to establish a diagnosis (6).

Radiology studies are complementary to endoscopic procedures. CT is preferred over magnetic resonance (MR). However, MR can be considered in patients with contraindications for CT or to avoid radiation exposure (2). CTA is performed using intravenous contrast, does not require bowel distention, and can detect bleeding rates as low as 0.3

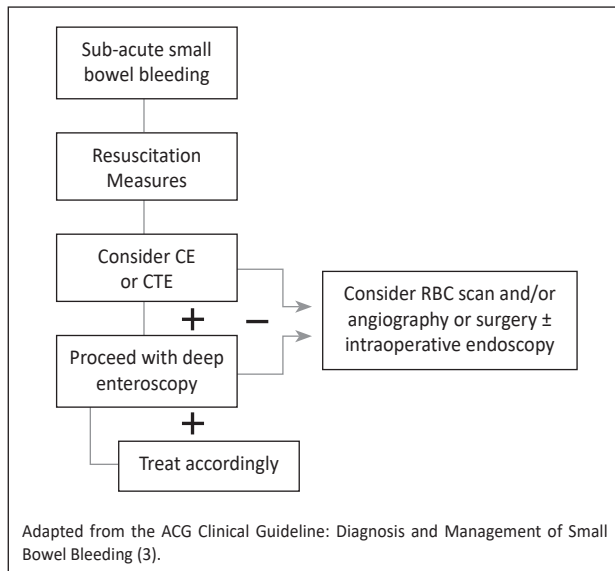
ml/min (7). Furthermore, it helps to identify the possible bleeding site and provide guidance for further management, such as angiography with embolization or surgery. The role of embolization in SBB is limited but considered successful if there is no recurrent bleed or hemodynamic instability within 30 days after the procedure (8).

Radionuclide imaging is performed with  $^{99m}\text{Tc}$ -labelled red blood cells. It detects extravasated, tagged blood within the GI tract at bleeding rates of around 0.1 ml/min; therefore, it is considered the most sensitive radiographic test for GI bleeding (9). CT enterography (CTE) is an alternative diagnostic imaging method used in hemodynamically stable patients. It can accurately localize the site of bleeding, allowing more appropriate triaging of patients for colonoscopy, enteroscopy, or angiography (10). It requires an oral contrast and helps to detect mural-based small-bowel masses. It is principally recommended for suspected SBB and negative CE (11). A  $^{99m}\text{Tc}$ -pertechnetate scan for the detection of Meckel’s diverticulum should be considered in young patients with overt bleeding and a negative evaluation (using other diagnostic modalities) (2). Finally, provocative angiography is rarely used due to the existence of newer, more sensitive methods but may be considered when all other diagnostic techniques have failed (2).

SBB can be a diagnostic challenge for physicians. Therefore, is essential that clinicians recognize this entity to provide prompt and life-saving treatment. Final management is based on the hemodynamic status of the patient, endoscopic expertise, and available imaging modalities. Further endoscopic and imaging algorithms are summarized in Figures 1 and 2. In many cases, multiple diagnostic studies are required. Therefore, we highlight the diagnostic approach based on patient’s hemodynamic status and importance of recognizing and understanding the role of endoscopic and imaging studies in the diagnosis and management of SBB.



**Figure 1.** Algorithm for brisk or massive suspected small bowel bleeding. CT (computed tomography).



**Figure 2.** Algorithm for sub-acute ongoing suspected small bowel bleeding. CTE (computed tomographic enterography); RBC (red blood cell); VCE (video capsule endoscopy).

## Resumen

El sangrado gastrointestinal del intestino delgado es poco común. Sin embargo, es responsable de la mayoría de los sangrados en los que no se identifica etiología luego de endoscopia y colonoscopia. A pesar de los avances tecnológicos, el sangrado del intestino delgado es un diagnóstico desafiante que puede requerir múltiples transfusiones, procedimientos y re-admisiones; aumentando así complicaciones y costos. La presentación es diversa y la etiología depende de la edad del paciente. El sangrado del intestino delgado puede requerir resucitación agresiva y localización inmediata para un cuidado apropiado y exitoso. El manejo se basa en la etiología, disponibilidad de la tecnología y experiencia del médico. Por

tal razón, presentamos el caso de un paciente con sangrado del intestino delgado el cual requirió múltiples imágenes y procedimientos. En adición, repasamos las causas más comunes del sangrado del intestino delgado al igual que las diferentes modalidades radiológicas y los procedimientos endoscópicos disponibles.

## References

1. Villanueva C, Colomo A, Bosch A, et al. Transfusion strategies for acute upper gastrointestinal bleeding. *N Engl J Med* 2013;368:11-21.
2. Gerson LB, Fidler JL, Cave DR, Leighton JA. ACG Clinical Guideline: Diagnosis and Management of Small Bowel Bleeding. *Am J Gastroenterol* 2015;110:1265-1287.
3. Tang SJ, Christodoulou D, Zanati S, et al. Wireless capsule endoscopy for obscure gastrointestinal bleeding: a single-centre, one-year experience. *Canad J Gastroenterol* 2004;18:559-565.
4. Leung WK, Ho SS, Suen BY, et al. Capsule endoscopy or angiography in patients with acute overt obscure gastrointestinal bleeding: a prospective randomized study with long-term follow-up. *Am J Gastroenterol* 2012;107:1370-1376.
5. Foutch PG, Sawyer R, Sanowski RA. Push-enteroscopy for diagnosis of patients with gastrointestinal bleeding of obscure origin. *Gastrointest Endosc* 1990;36:337-341.
6. Ress AM, Benacci JC, Sarr MG. Efficacy of intraoperative enteroscopy in diagnosis and prevention of recurrent, occult gastrointestinal bleeding. *Am J Surg* 1992;163:94-98.
7. Wu LM, Xu JR, Yin Y, Qu XH. Usefulness of CT angiography in diagnosing acute gastrointestinal bleeding: a meta-analysis. *World J Gastroenterol* 2010;16:3957-3963.
8. d'Othée BJ, Surapaneni P, Rabkin D, Nasser I, Clouse M. Microcoil Embolization for Acute Lower Gastrointestinal Bleeding. *Cardiovasc Intervent Radiol*. 2006;29:49-58.
9. Howarth DM, Tang K, Lees W. The clinical utility of nuclear medicine imaging for the detection of occult gastrointestinal haemorrhage. *Nucl Med Commun* 2002;23:591-594.
10. Fidler JL, Goenka AH, Fleming CJ, Andrews JC. Computed tomography enterography, magnetic resonance enterography, angiography, and nuclear medicine. *Gastrointest Endosc Clin N Am* 2017;27:133-152.
11. Huprich JE, Fletcher JG, Fidler JL, et al. Prospective blinded comparison of wireless capsule endoscopy and multiphase CT enterography in obscure gastrointestinal bleeding. *Radiology* 2011;260:744-751.