

R on T Phenomenon and Long QTc Syndrome due to Moxifloxacin in a Healthy Female

Dimitrios Anyfantakis, MD, MSc, PhD*; George Makrakis, MD†

Long QT syndrome is characterized by prolongation of the corrected QT interval and is associated with fatal arrhythmias. R on T phenomenon is the coincidence of a premature ventricular complex with a T wave and may result to syncope and sudden cardiac death. Here we present a case of a 59-year-old woman with no previous history of medication, receiving moxifloxacin for community-acquired pneumonia. She was admitted complaining for thoracic pain and shortness of breath. Electrocardiogram showed both R on T phenomenon and QT prolongation. After discontinuation of the antibiotic symptoms and electrocardiography features were resolved. Physicians should always be vigilant about this rare and potentially fatal adverse drug reaction especially in high risk patients. General practitioners in particular being the first point of access in care have to carefully assess and detect high risk patients before the administration of moxifloxacin. [*PR Health Sci J* 2019;38:196-197]

Key words: R on T phenomenon, Arrhythmias, Moxifloxacin

Long QT syndrome and R on T phenomenon are associated with an increased risk of syncope and sudden cardiac death. This report describes an unusual concurrence of these two electrocardiographic abnormalities after initiation of a fluoroquinolone in a middle-aged woman.

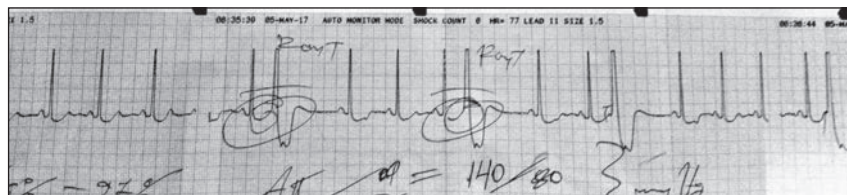


Figure 1. ECG on admission showing R on T phenomenon and long QT syndrome after moxifloxacin administration

Case report

A woman in her late 50s with no medical problems, presented to her primary care physician complaining of cough and fever. She denied intake of any other medication until then. Physical and radiological examination disclosed right middle lobe pneumonia. She was prescribed moxifloxacin 400mg once daily for 10 days. Six hours after initiation of antibiotic therapy she was re-admitted complaining heart palpitations, dizziness, thoracic discomfort and anxiety. On examination, blood pressure measured in both arms was 140/80mmHg (left) and 140/70mmHg (right), heart rate was 69 bpm and respiratory rate 14 breaths/min. Electrocardiogram (ECG) performed at that time is shown in Figure 1.

The ECG revealed long QT syndrome and superimposition of an ectopic beat on the T wave of a preceding beat known as R on T phenomenon (Figure 1).

Biochemical analysis including renal function tests, cardiac enzymes, troponin levels and electrolytes (serum potassium, calcium, magnesium and sodium levels) were all normal. Antibiotic therapy was interrupted and an ECG follow up was performed within 24 hours. On the repeated ECG, R on T phenomenon was resolved and the QT interval has returned to normal (QT corrected: 373ms) (Figure 2).

Discussion

R on T phenomenon was first reported by Smirk in 1949, describing 'R waves that interrupt T waves (1, 2). Ventricular vulnerability during the T wave period is the cause of the R on T phenomenon and responsible for the coincidence of a premature ventricular complex with a T wave (1, 2). It has been also suggested that R on T phenomenon may initiate sustained ventricular arrhythmias, posing a risk of sudden cardiac death (3).

QT interval measurement estimates the duration of ventricular repolarization and depolarization (4). It is measured from the beginning of the QRS complex until the end of the T wave (4). Long QT syndrome represents the result of an abnormality on cardiac repolarization (5), due to a malfunction of ion channels resulting to an intracellular excess of positively charged ions (inadequate outflow of potassium

*Primary Health Care Centre of Kissamos, Chania, Crete, Greece; †Private Cardiology Unit in Kissamos, Chania, Crete

The author/s has/have no conflict/s of interest to disclose. Information from this manuscript has been presented in the 18th Hellenic Cardiology congress, 16-18/5/2019 for educational input.

Address correspondence to: Dimitrios Anyfantakis, MD, MSc, PhD, Primary Health Care Centre of Kissamos, Chania, Crete, Greece. Email: danyfantakis@yahoo.gr

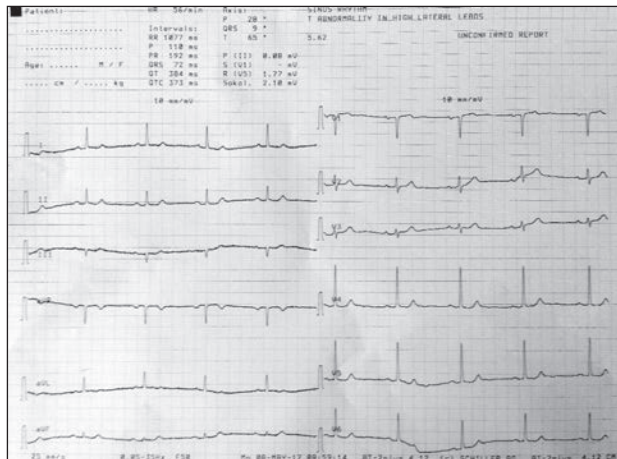


Figure 2. Follow up ECG after discontinuation of moxifloxacin showing resolution of R on T phenomenon and normal QTc interval

ions or extreme entry of sodium ions) (4,6). It is characterized by prolongation of the corrected QT (QTc) interval on the surface electrocardiogram and may be associated with torsade de pointes (TdP), a polymorphic ventricular tachycardia and high mortality related burden (5). QT prolongation in the ECG is better estimated in the V3 and V4 leads which are considered more representatives (7).

The syndrome was first reported by Selzer and Wray in 1964 after administration of quinidine (8). In regards to the cut off points of QTc, prolonged QTc values are considered more than 470ms for females and more than 450ms for males (4). Occurrence of arrhythmias is associated with values of QTc >500 ms (5). The calculation of the QTc, is usually performed with the Bazett's formula (Bazett: $QTcB = QT/RR^{1/2}$) (4).

Pharmacological therapy is the most common causative external cause of long QT syndrome followed by electrolytic disorders (hypomagnesaemia and hypokalemia) (5).

Moxiflocacin has been associated with acquired long QT syndrome, through a pathophysiological mechanism of hERG channel block (4, 9). Drug administration has been associated with a blockage of the rapid component (IKr) of the delayed rectifier potassium current (IK) leading to long QT syndrome (5).

Predisposing risk factors that contribute to acquired long QT syndrome secondary to fluoroquinolone therapy are considered the female gender, the elderly, administration of class Ia and III antiarrhythmic agents, structural cardiac disease, genetic predisposition and electrolyte abnormalities (5).

In regards to the frequency, malignant tachy-arrhythmias due to antibiotics are unusual. In post-marketing surveillance following moxiflocacin administration there was a single case reported of TdP in an elderly female patient with adverse risk factors for ventricular arrhythmia including electrolytic abnormalities, coronary artery disease, digoxin and a pacemaker inserted for a sick sinus syndrome (10).

To the best of our knowledge this is the first time that R on T phenomenon and prolongation of the QTc induced by moxiflocacin is reported in the literature. In our case gender and age were the only contributing factors for the acquired long QT syndrome. Physicians should be aware for this complication and maintain a high index of vigilance in case of elderly, female patients with metabolic abnormalities (hypokalemia) or heart disease and patients with concomitant use of other drugs that prolong QT interval. In this direction primary care physicians have to carefully assess and detect high risk patients before the administration of moxifloxacin (11).

Resumen

El síndrome de QT largo se presenta por la prolongación del intervalo QT corregido y se asocia con arritmias fatales y desenlaces cardíacos adversos. El fenómeno R sobre T se caracteriza por la coincidencia de un complejo ventricular prematuro con una T con una mayor tendencia al síncope y la muerte súbita cardíaca. Aquí presentamos el caso de una mujer de 59 años que recibió moxiflocacina por neumonía adquirida en la comunidad. Ella fue admitida quejándose de dolor torácico y dificultad para respirar. El electrocardiograma mostró tanto el fenómeno R sobre T como la prolongación del intervalo QT. Después de la interrupción de los síntomas de antibióticos y las características de la electrocardiografía se resolvieron. Los médicos siempre deben estar atentos a este efecto adverso raro y potencialmente fatal de la antibioterapia, especialmente en pacientes de alto riesgo.

References

- Smirk FH. R waves interrupting t waves. *Br Heart J* 1949;11:23–36
- Smirk F.H, Palmer D.G. A myocardial syndrome. With particular reference to the occurrence of sudden death and of premature systoles interrupting antecedent t waves. *Am J Cardiol* 1960;6:620–629.
- Engel TR, Meister SG, Frankl WS. The "R-on-T" phenomenon: an update and critical review. *Ann Intern Med* 1978;88:221-225.
- van Noord C, Eijgelsheim M, Stricker BH. Drug- and non-drug-associated QT interval prolongation. *Br J Clin Pharmacol* 2010;70:16-23.
- Kallergis EM, Goudis CA, Simantirakis EN, Kochiadakis GE, Vardas PE. Mechanisms, risk factors, and management of acquired long QT syndrome: a comprehensive review. *ScientificWorldJournal* 2012;2012:212178.
- Viscin S. Long QT syndromes and torsade de pointes. *Lancet* 1999;354:1625-1633.
- Sadanaga T, Sadanaga F, Yao H, Fujishima M. "An evaluation of ECG leads used to assess QT prolongation," *Cardiology* 2006;105:149–154.
- Selzer A, Wray HW. Quinidine syncope. Paroxysmal ventricular fibrillation occurring during treatment of chronic atrial arrhythmias. *Circulation* 1964;30:17-26.
- Alexandrou AJ, Duncan RS, Sullivan A, Hancox JC, Leishman DJ, Witchel HJ, Leaney JL. Mechanism of hERG K+ channel blockade by the fluoroquinolone antibiotic moxifloxacin. *Br J Pharmacol* 2006;147:905-916.
- Rubinstein E, Camm J. Cardiotoxicity of fluoroquinolones. *J Antimicrob Chemother* 2002;49:593-596.
- Khan F, Ismail M, Khan Q, Ali Z. Moxifloxacin-induced QT interval prolongation and torsades de pointes: a narrative review. *Expert Opin Drug Saf* 2018;17:1029-1039.