

Multimodal Endovascular approach in a Case of Multiple Dural Arteriovenous Fistulae

José A. Fernández-Abinader, MD*; Allyson Pagán-Rodríguez, BS†; Caleb Feliciano, MD‡; Héctor Rondón-Granados, MD§

Dural arteriovenous fistulae (DAVF) are vascular abnormalities in which arteriovenous shunts are contained in between the periosteal and meningeal lamellae of the dura matter. Rarely, multiple DAVF are diagnosed in a single patient; occurring in only about 8% of the diagnosed cases. We describe a rare presentation of DAVF in a patient with multiple DAVF, at 3 separate sites within the cranial cavity; associated with a medical history of two traumatic motor-vehicle accidents, total anomalous pulmonary venous return (TAPVR), and acquired aplastic anemia. We describe our approach in the treatment of this complex condition. [P R Health Sci J 2019;38:198-200]

Key words: Dural fistula, Fistulae, Arteriovenous fistula, Venous encephalopathy

Dural arteriovenous fistulae (DAVF) are vascular abnormalities in which arterio-venous shunts are contained between the periosteal and meningeal lamellae of the dura mater (1,2,3). Multiple DAVFs are rarely ever diagnosed in a single patient; occurring in only about 8% of the documented cases (1,2,4). We describe a case in which multiple cerebral arteriovenous fistulae were diagnosed in a 39-year-old male patient, who presented with an 18-month history of daily headaches and generalized cognitive dysfunction. There are no reported cases with a medical history of total anomalous pulmonary venous return (TAPVR) and acquired aplastic anemia.

Case Report

A 39-year-old hispanic male was emergently admitted to our service after a head computed tomography (CT), performed at another institution, demonstrated serpiginous hyperdense vessels within the deep and superficial aspects of the left temporal and left parietal lobes. For over a year, the patient had been experiencing daily, morning and evening headaches. He had decided to seek further medical management, as his headaches were becoming more intense, not relieved by over the counter medications, and were now associated with nausea, unsteadiness, and forgetfulness. The patient's past-medical history was significant for open-heart surgery, at 2 months of age, for the correction of total anomalous pulmonary venous return (TAPVR); for multiple courses of chemotherapy and blood transfusions, at 18 and 26 years of age, for the treatment of an acquired aplastic anemia and megakaryocytic hypoplasia, respectively. At the ages of 31 and 37 years, our patient became the victim of two motor vehicle accidents, where he experienced moderate multiple body trauma.

A six-vessel digital subtraction angiography (DSA) of the brain was performed (Image B). This study confirmed the CT and MRI findings of arteriovenous fistulae (Images A); revealing the presence of three DAVFs. One of the DAVF was a right sigmoid sinus-transverse sinus AV fistula, filling from the right, external carotid artery, the right meningohypophyseal carotid artery trunk, the neuromeningeal trunk of the vertebral artery, and the right posterior cerebral artery. Another DAVF was a left posterior superior sagittal sinus DAVF, filling from the right and left middle meningeal arteries. The third DAVF was a torcula-left transverse sinus AV fistula filling from the left neuromeningeal trunk and the external carotid artery.

Treatment

Brain magnetic resonance venography was performed revealing periventricular vein thrombosis. A short course of antiplatelet regimen was instituted. The DAVFs were treated with a staged endovascular regimen, consisting of three sequential partial embolization procedures, over a 30-day period.

A combined trans-venous and trans-arterial approach, via the right femoral artery and left femoral vein, was initially attempted for flow reduction by the embolization of the AV

*Neurosurgery Resident, PGY 6, Neurosurgery Section, Department of Surgery, University of Puerto Rico Medical Sciences Campus, San Juan, PR; †Third Year Medical Student, Ponce Health Sciences University, Ponce, PR; ‡Associate Professor, Program Coordinator Neurosurgery, Neurosurgery Section, Department of Surgery, University of Puerto Rico Medical Sciences Campus, San Juan, PR; §Endovascular Fellow, Neuroendovascular Surgery and Stroke Program, Puerto Rico Medical Services Administration and Neurosurgery Section, Department of Surgery, University of Puerto Rico Medical Sciences Campus, San Juan, PR

The author/s has/have no conflict/s of interest to disclose.

Address correspondence to: José A. Fernández-Abinader, MD, Neurosurgery Resident PGY 6, Neurosurgery Section, Department of Surgery, University of Puerto Rico Medical Sciences Campus, San Juan, PR. Email: alcynd@gmail.com

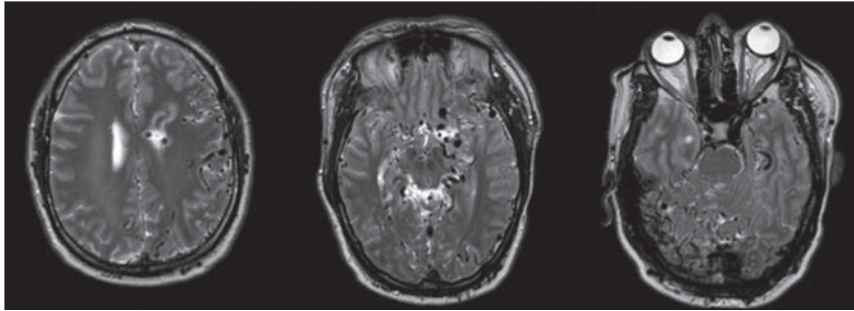


Figure A. Axial T2 MRI showing abnormal serpiginous flow voids suggestive of Dural AV Fistula

fistula. Discovery of a right sigmoid sinus outflow stenosis and of tortuous brachiocephalic venous changes precluded a safe femoral transvenous embolization approach, risking vessel perforation and compromising venous flow that could result in unintentional thrombosis. We then proceeded with selected catheterization of the right external carotid artery and super-selective catheterization of the DAF through the right occipital artery. Partial embolization of the fistula, with silk particles and N-butyl cyanoacrylate (NBCA), was achieved without much complications. A second embolization, via a right jugular percutaneous approach, was done with the use of Onyx, an non-adhesive liquid agent that can be injected at a slower rate allowing for greater control. In the third stage of treatment, a trans-arterial embolization of the torcula-left transverse sinus DAVF with Onyx liquid agent was achieved. (Images C) After finalizing treatment the patient achieved significant cognitive improvement and resolution of his headaches. Continuous analysis of residual DAVF and patient surveillance is ongoing.

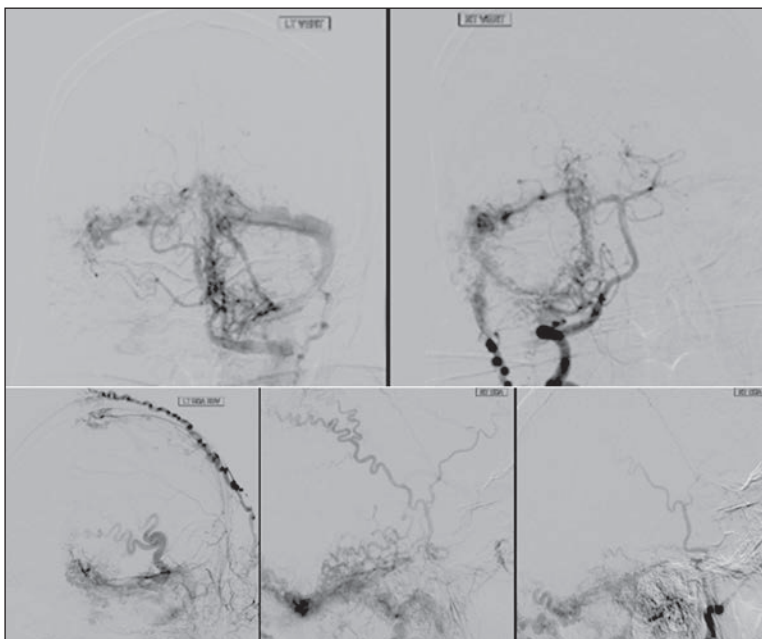


Figure B. Digital Subtraction Angiography (DSA) showing a left torcula-transverse sinus Dural AV fistula, a right sigmoid-transverse sinus Dural AV fistula and a left posterior superior sagittal sinus AV fistula.

Discussion

An arteriovenous fistula forms when an anomalous direct communication between an artery and a vein leads to the bypassing of the high-resistance capillary vasculature limiting local tissue perfusion (3). These lesions, which may develop naturally, or as a result of trauma, have an increased incidence within the fourth to sixth decades of life. Other etiologies include

postinfectious; related to surgery; and secondary to sinus thrombosis.

Cranial arteriovenous fistulae have been found to have female predominance (61-66%) (1). However, in males, these vascular anomalies tend to follow a faster and more malignant course, displaying aggressive neurological symptoms and presenting acutely with devastating hemorrhages (10). It is important to have a high level of suspicion, as these anomalies may lead to severe presentations, including: seizures, cerebellar dysfunction, orbital venous congestion, apathy, dementia, encephalopathy, cognitive decline, and failure to thrive (1,2,4,5,6).

Treatment may not necessarily be indicated once an asymptomatic DAVF is diagnosed as, most follow a benign course, and may even resolve or occlude spontaneously (5,6,7). Prior to any treatment consideration, DAVFs need to be classified on the basis of venous drainage patterns. The most commonly used classification systems are the Borden classification system and the Conrad Angiographic classification (5). Endovascular embolization of DAVFs is considered the gold-standard treatment for this condition (1,2,5,7). Compared to techniques that involve open surgery, stereotactic radiosurgery, or a combination of these; endovascular embolization of dural arteriovenous fistulae has consistently resulted in successful fistula occlusion, while remaining one of the most minimally invasive methods for symptom resolution (8,9).

Trans-arterial, trans-venous, or combined endovascular approaches may be used (1,2,10). The selection of a specific technique will depend on the unique characteristics of each fistula, its location, the quantity and size of its feeding vessels, and its venous drainage (1). As of today, the trans-arterial approach is preferred for most DAVFs; especially for those that possess stenotic, tortuous draining vessels, or have vessels that drain normal brain parenchyma (2). Combined approaches may fill in the gap that results when considering a single treatment modality, and may help to achieve fistula closure within very complex, and fairly inaccessible, DAVFs (10).

For the treatment of symptomatic DAVFs the ultimate therapeutic goal is to reduce blood flow through the fistula, reducing venous hypertension, and eventually achieve cure (1,2). Combined approaches (trans-venous and trans-arterial embolization) can be used for optimal treatment, helping to achieve fistula closure within very complex, and fairly inaccessible DAVF (10).

The treatment of a DAVF must be completed in a staged regime to avoid drastic changes in flow dynamics that could result from a rapid closure. Suboptimal obliteration may induce fistulae recurrence, development of other vascular anomalies, or worsening of fistula grade, via the stimulation of neovascularization. Long-term patient surveillance is key to the successful outcome in the treatment of DAVF.

Resumen

Las fístulas arteriovenosas durales (DAVF, por sus siglas en inglés) son anomalías vasculares en las cuales las derivaciones arteriovenosas están contenidas entre las laminillas periosteal y meníngea de la duramadre. En raras ocasiones, más de una de estas fístulas se diagnostican en un sólo paciente; ocurriendo sólo en alrededor del 8% de los casos. Describimos una presentación inusual de un paciente con múltiples DAVF en la cavidad intracraneana, asociada con un historial médico de retorno venoso pulmonar anómalo (TAPVR, por sus siglas en inglés), anemia aplásica adquirida, y dos accidentes traumáticos con vehículos motorizados. Describimos nuestro enfoque en el tratamiento de esta condición.

References

1. Greenberg, Mark S. *Handbook of Neurosurgery*. Eighth Edition. New York: Thieme; 2016;1575:1251-1255.
2. Miller TR, Gandhi D. Intracranial Dural Arteriovenous Fistulae. *Clinical Presentation and Management Strategies*. *Stroke* 2015;46: 2017-2025.
3. Patel R, Nicholson AA. Arteriovenous Fistulas: Etiology and Treatment. Important considerations from initial evaluation to treatment planning. *Endovascular Today* 2012;45-51.
4. Hurst RW, Bagley LJ, Galetta S, Glosser G, Lieberman AP, Trojanowski J, Sinson G, Stecker M, Zager E, Raps EC, Flamm ES. Dementia Resulting from Dural Arteriovenous Fistulas: The Pathologic Findings of Venous Hypertensive Encephalopathy. *AJNR Am J Neuroradiol* 1998;19: 1267-1273.
5. Gandhi D, Chen J, Pearl M, Huang J, Gemmete JJ, Kathura S. Intracranial Dural Arteriovenous Fistulas: Classification, Imaging Findings, and Treatment. *AJNR Am J Neuroradiol* 2012;33:1007-1013
6. Piippo, Anna. *Intracranial Dural Arteriovenous Fistulas: Characteristics, Treatment and Long-Term outcome*. Academic Dissertation. Kuopio, Finland; 2013.
7. Cooper CJ, Said S, Nunez A, Quansah R, Khalilullah S, Hernandez GT. Dural arteriovenous fistula discovered in patient presenting with recent head trauma. *Am J Case Rep* 2013;14:444-448.
8. Loh CT, Almekhlafi MA, Eesa M, Dolati P, Mitha AP. Dural Arteriovenous Fistula Treated by Combined Surgical/Endovascular Approach. *Case Report. JSM Neurosurgery and Spine* 2014;2:1045.
9. Bai Y, He C, Zhang H, Ling F. De novo multiple dural arteriovenous fistulas and arteriovenous malformation after embolization of cerebral arteriovenous fistula: case report. *Child's Nervous System* 2012;28: 1981-1983.
10. Tao Y, Niu Y, Zhu G, Chen Z. Endovascular treatment of a traumatic dural arteriovenous fistula of the superior sagittal sinus using dural lumen balloon microcathereter. *Case Report. Neurosciences* 2016;21:158-160.