

Gastric MALT Lymphoma with Biclonal Gammopathy and Bone Marrow Involvement Mimicking Multiple Myeloma

William Cáceres-Perkins, MD*; Fernando Cabanillas, MD†; Glorivette San Vicente, MD*; Carlos Rivera-Franceschini, MD*; Elias Sobrino-Najul, MD*; Laura I. Vega-Vázquez, MT*; Daniel Conde-Sterling, MD*

Mucosa-associated lymphoid tissue (MALT) lymphomas are B-cell neoplasms that commonly affect the gastrointestinal (GI) tract, usually the stomach. In most cases, extranodal marginal zone lymphoma (ENMZL) is an indolent disease. Bone marrow involvement is common with MALT lymphoma accompanied by paraproteinemia; such involvement impels disease progression. Here, we present the case of an 82-year-old Hispanic patient with long-standing ENMZL in whom the gastric site responded to antibiotic treatment and *Helicobacter pylori* eradication, but the disease progressed over the years, with a biclonal gammopathy and bone marrow involvement with marked plasmacytic differentiation. In view of this, we suggest the routine evaluation of paraprotein in patients with ENMZL. [P R Health Sci J 2020;39:275-277]

Key words: Marginal zone B-cell lymphoma, Biclonal gammopathy, Bone marrow

Gastric mucosa-associated lymphoid tissue (MALT) lymphoma is the most common primary site of marginal zone lymphomas (MZLs). Found in mucosal lymphoid tissue, the lymph nodes, and the spleen, lymphoid follicles contain marginal zone B-lymphocytes, from which MZLs originate (1,2); splenic MZL, extranodal MZL of MALT, nodal MZL, and splenic MZL comprise the 3 distinct types of MZL (3). MZLs originate from B-lymphocytes that are normally present in the marginal zone of lymphoid follicles that can be found in the spleen, lymph nodes, and mucosal lymphoid tissues (1,2). Three distinct types of MZLs exist: extranodal MZL of MALT, nodal MZL, and splenic MZL (3). *Helicobacter pylori* (*H. pylori*) infection and chronic immune stimulation have important roles in the pathogenesis of gastric MALT lymphomas. The eradication of the infection can lead to tumor regression (4).

Several chromosomal translocations have been implicated in the pathogenesis of MALT lymphoma, with t(11;18) being the most common (5). This translocation results in the formation of the chimeric fusion gene, API2–MALT1. The translocation t(11;18) is associated with locally advanced disease and is not likely to respond to *H. pylori* eradication (6).

Usually, extranodal marginal zone lymphoma (ENMZL) is an indolent disease (7). ENMZL cells have the potential to differentiate into plasma cells that can secrete immunoglobulins (8). Wohrer et al reported a prevalence of 36% of monoclonal gammopathy in MALT lymphoma patients (9). Asiatiani et al suggested that monoclonal gammopathy in ENMZL correlated with advanced disease and bone marrow involvement (10). Asiatiani's study suggested that the common Ig in monoclonal gammopathy was IgG, while the incidence of IgM gammopathy was low, at 3.8%. This contrasts with most other lymphomas,

which usually do not have associated gammopathies, and when they do, they usually are the IgM type.

In up to 25% of MALT lymphomas, a predominance of monoclonal plasma cells can be detected, a phenomenon called plasmacytic differentiation. Increased *plasmacytic differentiation* has been significantly correlated with rituximab therapy (11). The authors suggested that rituximab may not optimally eradicate the plasma cell component of the neoplasm.

Case report

An 82-year-old male Hispanic patient presented 20 years prior to this current diagnosis with dyspepsia, and an upper endoscopy revealed a gastric ulcer, non-erosive gastritis of the antrum and the body of the stomach; the mucosa had a diffuse cobblestone appearance. Several biopsies revealed a MALT lymphoma with *H. pylori* organisms (Figure 1). The hemoglobin levels (15.0 g/dl), peripheral smear, and comprehensive metabolic panel were within normal limits. Serum protein electrophoresis (SPEP) revealed an IgM monoclonal spike of 1.2 gm/dl, and immunoelectrophoresis showed that it was the lambda light chain type; a bone marrow aspirate and biopsy had

*Hematology and Oncology and Pathology & Laboratory programs, VA Caribbean Healthcare System, San Juan, PR; †Auxilio Mutuo Cancer Center, San Juan, PR; Hematology- Medical Oncology Section, School of Medicine, University of Puerto Rico Medical Sciences Campus, San Juan, PR; Department of Malignant Hematology, H. Lee Moffitt Cancer Center and Research Institute, Tampa, FL

The authors have no conflict of interest to disclose.

Address correspondence to: William Cáceres-Perkins, MD, Hematology and Oncology VA Caribbean Healthcare System, 10 Calle Casia, San Juan, PR 00921. Email: william.caceres@va.gov

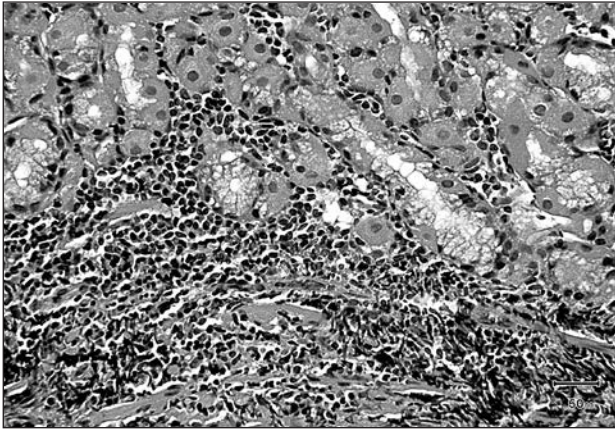


Figure 1. Gastric MALT lymphoma with a dense lymphoid infiltrate and lymphoepithelial lesions.

trilineage hematopoiesis and failed to show an increase in plasma cells or the involvement of lymphoma. Over the next 2 years after diagnosis, he had several courses of antibiotics and proton pump inhibitors, resulting in a resolution of his symptoms. His MALT lymphoma disappeared after *H. pylori* eradication.

In 2013, 20 years after the original diagnosis, a PET/CT scan revealed an upper left lung mass with a standardized uptake value of 5.5; he developed anemia (11.1 g/dl) and thrombocytopenia (107,000 platelets), with fatigue. A bone marrow aspirate and biopsy showed involvement of MZL with translocation (11;18) (q21;q21). This translocation resulted in API2–MALT1 fusion. SPEP and immunofixation revealed 2 monoclonal spikes: IgM lambda and IgG lambda, 2.4 gm/dl and 1.6 gm/dl, respectively (Figure 2). An MYD88 L265P mutation was not detected. An upper endoscopy did not reveal MALT lymphoma in his stomach. The patient had a weekly course of rituximab, 4 doses at 375 mg/m², with entecavir (0.5 mg, daily) prophylaxis for hepatitis B core antibody positivity. He had a partial response to therapy, with an improvement in his symptoms of fatigue and increased hemoglobin levels (12.6 g/dl).

The patient remained under surveillance, with the development in September 2018 of worsening peripheral

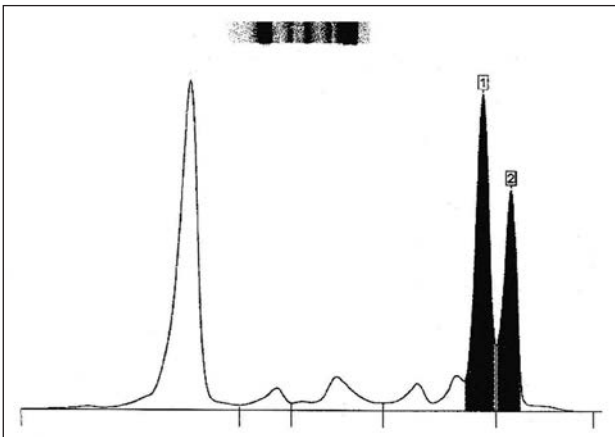


Figure 2. Serum protein electrophoresis disclosing biclonal gammopathy of 2.4 gm/dl (anodic) and 1.6 gm/dl (cathodic).

neuropathy, anemia (10.3 g/dl), worsening renal function (1.65 mg/dl), and increased serum viscosity (2.7 [normal range, 1.2–1.7]). A PET/CT scan disclosed a left upper lung mass that was stable in size, with no other adenopathies or bony lytic lesions. An evaluation of a repeat bone marrow aspirate revealed abnormal plasma cells (15%) in the patient's bone marrow. FISH studies showed t(11;18) and an additional 25% of cells with no t(11;18) but with a gain of 11q or trisomy 11. The trisomy 11 was interpreted as a possible coexisting plasma cell neoplasm (Figure 3). Flow cytometry revealed clonal plasma cells that co-expressed CD38/CD138/cytoplasmic lambda light chain s, with aberrant expression of CD56/cd117 in 9% of the analyzed events and negative CD20 and CD19 expression. A small population of malignant B-cells (1% of the total cells) had a borderline low kappa/lambda ratio (0.65:1).

The patient was recently started on ibrutinib 420 mg, po, daily, as a second-line therapy for his ENMZL (with plasmacytic differentiation), the aim being to improve his symptoms of fatigue, peripheral neuropathy, and altered hematologic parameters.

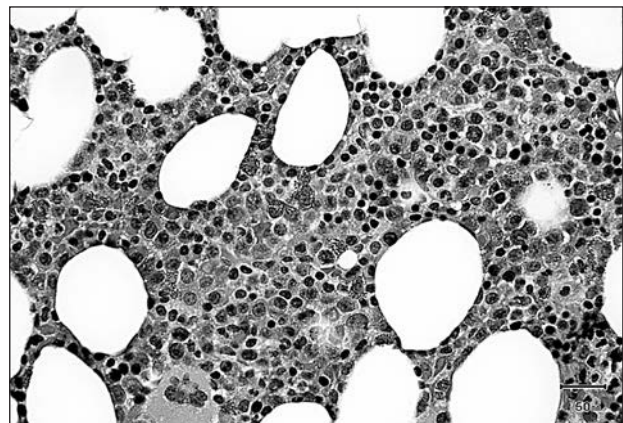


Figure 3. Bone marrow aspirate revealing plasmacytic differentiation.

Discussion

The prevalence of monoclonal gammopathy in MZL was first reported by Duong Van Huyen et al in a series of 31 patients with splenic MZL (12). Asatiani et al detected plasmacytic differentiation in 27% of their patients; all of those patients had stage IV disease with involvement of the lymph nodes and/or bone marrow, as did the patient described in our case report (10). Furthermore, Akoum et al reported on a patient with disseminated gastric MALT lymphoma with IgM kappa production, the presence of t(11;18), and the subsequent development of T-large granular lymphocytic leukemia (13). Akoum and team recommended including a paraprotein analysis in the workup of patients with MALT lymphoma. Reitter et al insisted that the paraprotein level should be routinely checked at the staging of MALT lymphoma and suggested that a change in the paraprotein level may be valuable for monitoring treatment response (14). For our patient, the development of a second

monoclonal paraprotein anteceded the clinical worsening of his disease. This finding and the presence of a larger number of clonal plasma cells with a similar light chain restriction correlated with the bone marrow MZL with marked plasma cell differentiation (PCD). The development of a second monoclonal spike over time can be explained as the basis of a switch from an IgM lambda in the malignant B-lymphocytes to an IgG lambda at the time that the malignant cells differentiated into plasma cells.

Troch et al analyzed patients with MALT lymphoma treated with rituximab-containing regimens. They identified 19 patients whose tumors did not show PCD at diagnosis. In 7 of these 19, restaging revealed PCD after treatment with rituximab-containing regimens. Out of these 7 patients, only 1 patient had a complete response as opposed to 10 of 12 without PCD, thus suggesting that rituximab may not optimally eradicate an unrecognized subclinical plasma cell component of these lymphomas, consequently leading to PCD (11). Since plasma cells do not express CD20, this is a plausible explanation. Troch and others proposed that rituximab might not optimally target the CD20-negative plasma cell component in these lymphomas and consequently lead to the clonal selection of CD20-negative plasma cells (11).

Our report shows a rare case of biclonal gammopathy that developed over the course of 20 years in a patient with a MALT lymphoma. It appears that this case gradually evolved from a typical case of gastric MALT lymphoma that eventually differentiated into an IgG plasma cell neoplasm, while the original IgM tumor was retained. Our case, as well as others reported in the literature, suggests that patients with MALT lymphoma in complete remission should be followed routinely with SPEP in order to detect a possible relapse and to detect also the possible transformation to a plasma cell neoplasm.

Resumen

Los linfomas de tejido linfoide asociado a la mucosa (MALT, por sus siglas en inglés) son neoplasias de origen de linfocitos B que comúnmente envuelven el tracto gastrointestinal (GI), usualmente el estómago. El linfoma de zona marginal extranodal (ENMZL, por sus siglas en inglés) es usualmente una enfermedad indolente. La paraproteinemia que acompaña al linfoma MALT correlaciona fuertemente con involucramiento de la médula ósea, y este involucramiento conlleva a progresión de la enfermedad. Presentamos un caso de un paciente Hispano de 82

años con una historia larga de ENMZL en que el origen gástrico respondió a tratamiento de antibióticos con la erradicación de *Helicobacter pylori*, pero la enfermedad progresó a través del tiempo con una gammapatía biclonal y involucramiento de médula ósea con marcada diferenciación plasmácica. Debido a esto, sugerimos que se evalúe de rutina la presencia de paraproteínas en los pacientes con ENMZL.

References

1. Kahl B, Yang D. Marginal zone lymphomas: management of nodal, splenic, and MALT NHL. *Hematology Am Soc Hematol Educ Program* 2008;359-364.
2. Thieblemont C. Clinical presentation and management of marginal zone lymphomas. *Hematology Am Soc Hematol Educ Program* 2005;305-313.
3. Campo E, Pileri SA, Jaffe ES et al. Nodal marginal zone lymphomas In: Swerdlow SH, Campo E, Harris NL, et al; eds. *WHO classification of tumours of haematopoietic and lymphoid tissues*. 4th ed. Lyon, France: IARC; 2017:218-219.
4. Wotherspoon AC. Gastric lymphoma of mucosa associated lymphoid tissue and *Helicobacter pylori*. *Annu Rev Med* 1998;49:289-299.
5. Farinha P, Gascoyne RD. Molecular pathogenesis of mucosa-associated lymphoid tissue lymphoma. *J Clin Oncol* 2005;23:6370-6378.
6. Li H, Ye H, Dogan A, et al. T(11;18)(q21;q21) is associated with advanced mucosa-associated lymphoid tissue lymphoma that expresses nuclear BCL10. *Blood* 2001;98:1182-1187.
7. Thieblemont C, Berger F, Dumontet C, et al. Mucosa-associated lymphoid tissue lymphoma is a disseminated disease in one third of 158 patients analyzed [published correction appears in *Blood* 2000 Apr 15;95(8):2481]. *Blood* 2000;95:802-806.
8. Tirelli A, Guastafierro S, Cava B, Lucivero G. Triclonal gammopathy in an extranodal non-Hodgkin lymphoma patient. *Am J Hematol* 2003;73:273-275.
9. Wohrer S, Streubel B, Bertsch K, Chott A, Raderer M. Monoclonal immunoglobulin production is a frequent event in patients with mucosa-associated lymphoid tissue lymphoma. *Clinical Cancer Res* 2004;10:7179-7181.
10. Asatiani E, Cohen P, Ozdemirli M, Kesler CM, Mavromatis B, Cheson BD. Monoclonal gammopathy in extranodal marginal zone lymphoma (ENMZL) correlates with advanced disease and bone marrow involvement. *Am J Hematol* 2004;77:144-146.
11. Troch M, Kiesewetter B, Dolak W, et al. Plasmacytic differentiation in MALT lymphoma following treatment with rituximab. *Ann Hematol* 2012;91:723-728.
12. Duong Van Huyen JP, Molina T, Delmer A, et al. Splenic marginal zone lymphoma with or without plasmacytic differentiation. *Am J Surg Pathol* 2000;24:1581-1592.
13. Akoum R, Serhal W, Farhat H. Disseminated gastric MALT lymphoma with monoclonal gammopathy, t(11:18)(q21;q21) and subsequent development of T-large granular lymphocytic leukemia: a case report and review of the literature. *Case Rep Med* 2015;2015:953297.
14. Reitter S, Neumeister P, Beham-Schmid C, et al. A case of generalized MALT lymphoma with IgM paraproteinemia and peripheral blood involvement. *Ann Hematol* 2010;89:213-214.