



Malrotation of the intestine and preduodenal portal vein associated with abdominal situs inversus: A case report

ROSA DÍAZ, MSIV*; HUMBERTO LUGO-VICENTE, MD†

Abdominal situs inversus is a rare condition usually associated with malformations of asymmetric organs such as the heart, liver, spleen and malrotation of the intestines. A case of abdominal situs inversus with intestinal malrotation and preduodenal portal vein is reported. Patient underwent prophylactic Ladd's procedure and preduodenal portal vein was left undisturbed during surgery. This case highlights the

importance of rigorous investigation of anatomic features prior to surgery in a patient with heterotaxia. The authors advocate radiological investigation of patients with heterotaxia and prophylactic Ladd's procedure in those with intestinal malrotation.

Key words: Abdominal situs inversus, Intestinal malrotation, Preduodenal portal vein

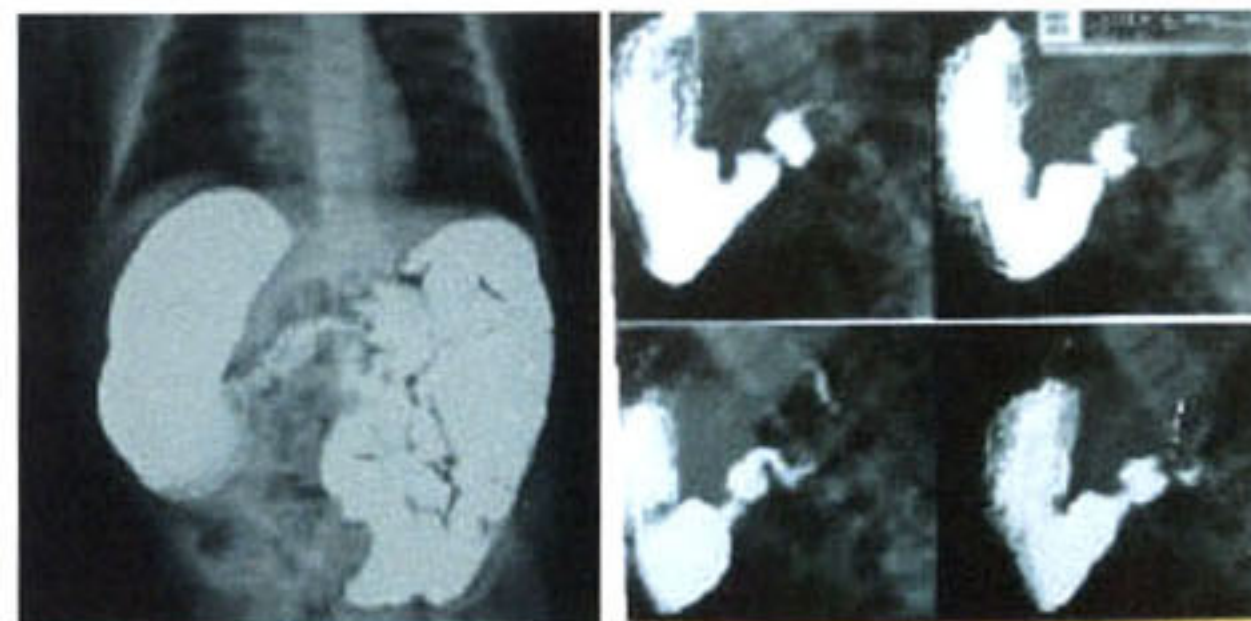
Abdominal situs inversus, also called abdominal heterotaxia or isolated levocardia, is characterized by inversion of the abdominal viscera but with a normally located heart in the left hemithorax. It is a rare condition commonly associated (95%) with significant malformations of asymmetric organs such as the heart and great vessels, spleen, liver, biliary tract, and malrotation of the bowel (1-3). In the present report, we describe a case of abdominal situs inversus with intestinal malrotation and preduodenal portal vein successfully repaired with a modified -mirror image Ladd procedure.

Case Report

A two month old girl presented to the Emergency Room due to acute onset abdominal distension. Patient detailed past history of intermittent abdominal distension, obstipation, irritability, poor feeding and copious non-projectile, non-bilious emesis since one week of age. Multiple changes in milk had been made by pediatrician without improvement in patient's condition. The child was well nourished and her general condition was good.

Physical examination did not reveal any other abnormalities. Patient's condition improved and she was sent home. Multiple imaging studies were performed outpatient with the findings of abdominal situs inversus and malrotation. Patient continued to present intermittent symptoms of obstipation and vomiting and was scheduled for prophylactic Ladd's procedure. At the time of admission, patient was asymptomatic with a soft and depressible abdomen.

Chest film revealed no abnormalities in the thorax and gastric bubble beneath right dome of the diaphragm. Barium follow through examination (Figure 1 and 2) confirmed that the stomach was situated below the right diaphragm followed by a duodenojejunal junction (ligament of Treitz) located at the left of the spine and crowding of small intestines towards the left side of the



Figures 1 and 2: UGIS Showing Abdominal Situs Inversus.

From the * UPR School of Medicine and Department of Pediatric Surgery, UPR School of Medicine, San Juan, Puerto Rico

Address correspondence to: Humberto Lugo-Vicente MD, PO Box 10462, San Juan, PR 00922 <titolugo@coqui.net>

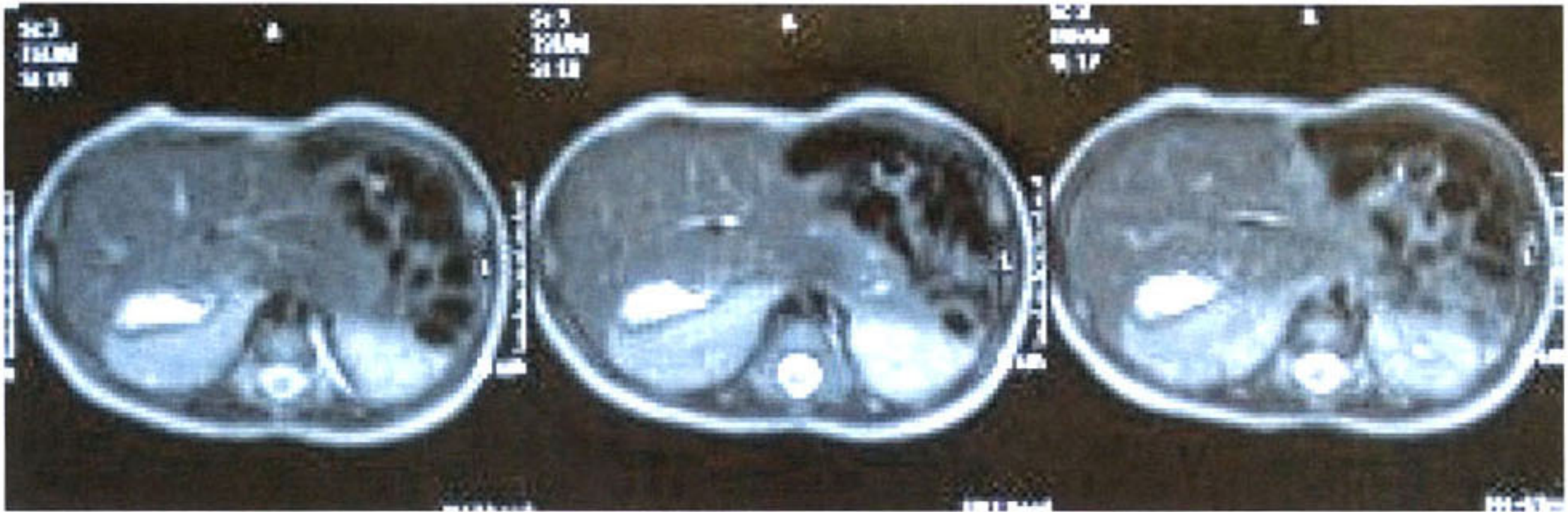

Figure 3: CT-Scan Showing Liver, Stomach and Spleen located on the Right Side of the Abdomen.

abdomen. The colon was situated on the right side of the abdomen, but it was not well delineated. Progress of the meal was normal and without evidence of obstruction. Computed tomography with intravenous and oral contrast (Figure 3) revealed that the liver, stomach and spleen were located on the right side of the abdomen and left sided small intestine. There was no evidence of heart disease. Radiological findings are those of abdominal situs inversus with levocardia and intestinal malrotation.

Surgical procedure. Laparotomy was performed through a supraumbilical transverse incision. Patient was eviscerated (Figure 4) and lysis of Ladd's bands extending

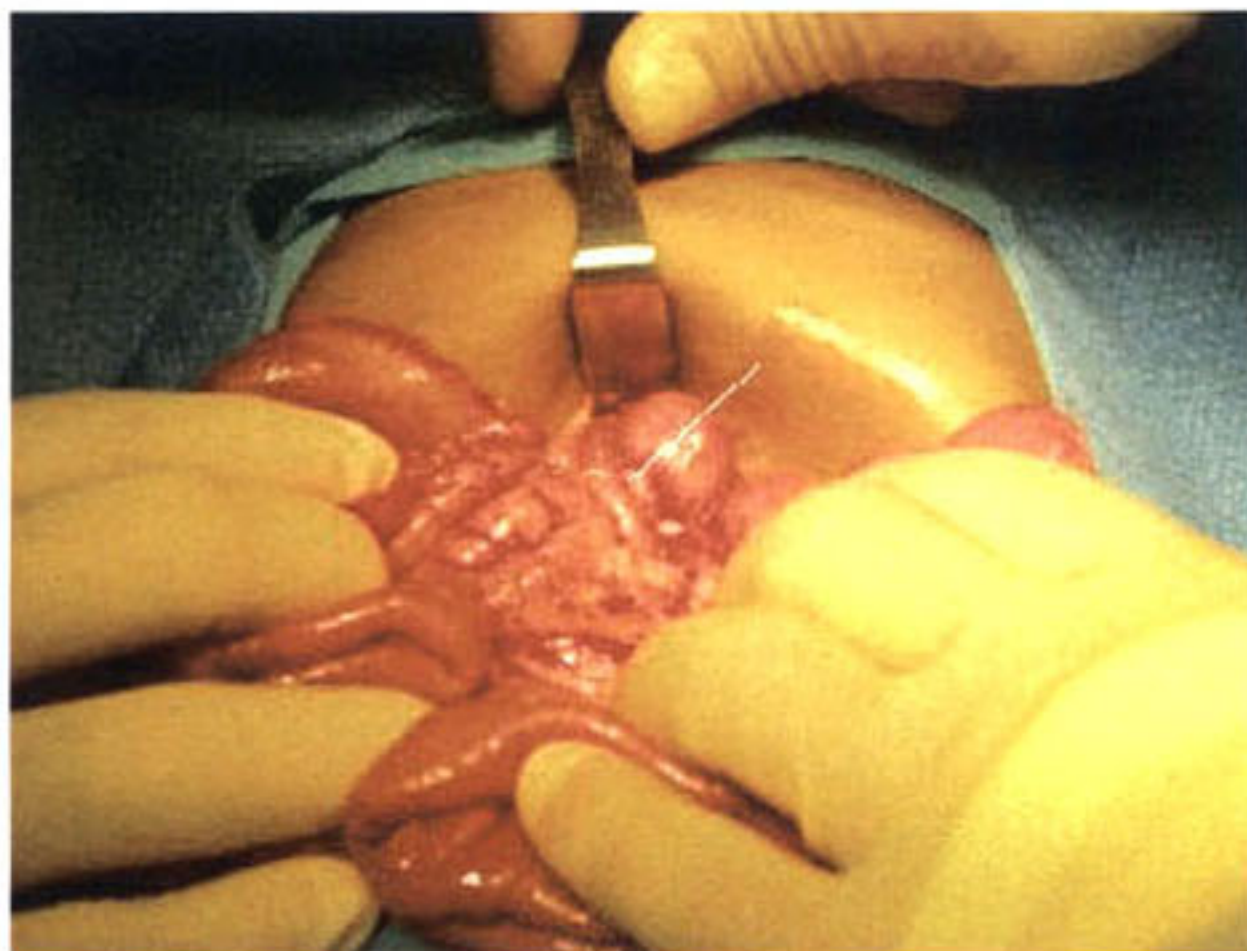


Figure 4: White Line Points Toward the Pre-duodenal Portal Vein.

towards the left side of the abdomen was performed. A preduodenal portal vein over the second portion of the duodenum was found and left undisturbed. The appendix, although normal in appearance, was removed. The intestine was carefully replaced into the abdominal cavity with the small bowel positioned on the left and colon on the right side of abdomen (mirror image Ladd's procedure).

There were no complications during surgery and the patient recovered well.

Discussion

Malrotation is defined as a failure of normal rotation of any part of the intestinal tract during embryologic development. It occurs in approximately 1 in 500 live births and is seen in the majority of children with heterotaxy syndromes (4-5). Malrotation in itself is not a surgical emergency. However, patients with malrotation are at increased risk for volvulus, a surgical emergency, since abnormally rotated bowel does not develop normal mesenteric attachments (4).

The consensus in the literature has been for many years that given the high incidence of malrotation and serious heart disease in heterotaxia, high risk of performing emergency Ladd's procedure in such a patient and morbidity and mortality associated to volvulus, all children with heterotaxia should be screened for intestinal rotational abnormalities using upper gastrointestinal contrast studies and that, if such an abnormality is found, a prophylactic modified Ladd's procedure should be performed (5-8). Choi et al challenge this approach to rotational abnormalities in heterotaxy and suggested that it is safe to offer radiological investigation for intestinal malrotation only to symptomatic patients and to perform Ladd procedure only if radiological findings are suggestive of high risk for volvulus, as long as there is regular follow up of asymptomatic patients (6). Regardless, radiological investigation and prophylactic Ladd's procedure remains the standard of care in our hospital given the lifelong risk of volvulus in these patients and the low risk of elective Ladd's procedure.

An incidental finding during surgery of this patient was a preduodenal portal vein crossing over the second portion

of the duodenum. Preduodenal portal vein (PDPV) is a rare anomaly that has been reported in 82 patients in the literature (9) and was first described by Knight in 1921 (10). It arises when there is degeneration of the erroneous portion of the vitelline veins system. Some have suggested that preduodenal portal vein can cause obstruction through extrinsic compression of the duodenum (11). However, this remains controversial. Regardless, PDPV remains a significant entity for the surgeon given its exposed position and risk of laceration during surgery. In our patient, we acknowledged the presence of the PDPV but left it undisturbed given that it clearly was not causing problems. If PDPV is found to be the etiology of intestinal obstruction, the treatment of choice would be duodenoduodenal anastomosis anterior to the portal vein (12).

The present case illustrates the need for rigorous investigation of anatomic features in a patient with partial situs inversus before undergoing surgery. We support the use of prophylactic Ladd's procedure in patients with heterotaxia and malrotation given the low risk associated with the procedure, high risk of volvulus, and high incidence of congenital cardiac defects in these patients. While the incidental finding of PDPV in our patient did not lead to complications during the surgery, it is important for the surgeon to keep in mind this entity when performing surgery in patients with heterotaxia. This case is rare in that this patient presented with abdominal situs inversus, malrotation and preduodenal portal vein in the absence of splenic and cardiac defects.

Resumen

Situs inversus abdominal es una anomalía congénita rara que usualmente esta asociada con malformaciones de órganos asimétricos como el corazón, hígado, bazo y malrotación intestinal. En el presente discutimos un caso de situs inversus abdominal con malrotación intestinal y hallazgo incidental de una vena preduodenal portal. El

paciente se sometió a un procedimiento de Ladd profiláctico y la vena preduodenal portal se dejó quieta. Este caso enfatiza la importancia de una investigación rigurosa prequirúrgica de la anatomía de pacientes con heterotaxia. Los autores apoyamos el uso de estudios radiológicos para investigar la anatomía de pacientes con heterotaxia y de cirugía profiláctica en los pacientes con malrotación intestinal.

References

1. Tryfonas GI, Chaidos C, Avtzoglou PP, Zioutis J, Klokari A and Papanastasiopoulou A: Partial situs inversus: duodenal obstruction in a neonate with isolated levocardia. *J Ped Surg* 1992;27:1584-1586.
2. Chacko AK, Krishnawami S, Sukumar IP, et al: Isolated laevocardia: two cases with abdominal situs inversus, thoracic situs solitus and normal circulation. *Am Heart J* 1983;106:155-159.
3. Campbell M, Forgacs P: Laevocardia with transposition of the abdominal viscera. *Br Heart J* 1953;15:401-422.
4. Strouse PJ: Disorders of intestinal rotation and fixation ("malrotation"). *Pediatr Radiol* 34:837-851.
5. Chang J, Brueckner M, Touloukian RJ: Intestinal rotation and fixation abnormalities in heterotaxia: early detection and management. *J Pediatr Surg* 2004;28:1281-1285,1993.
6. Choi M, Borenstein SH, Hornberger L, Langer JC: Heterotaxia syndrome: the role of screening for intestinal rotation abnormalities. *Arch Dis Child* 2005;90:813-815.
7. Nakada K, Kawaguchi F, Wakisaka M, et al: Digestive tract disorders associated with asplenia/polysplenia syndrome. *J Pediatr Surg* 1997;32:91-4.
8. Ditchfield MR, Hutson JM: Intestinal rotational abnormalities in polysplenia and asplenia syndromes. *Pediatr Radiol* 1998;28:303-6.
9. Mordehai J, Cohen Z, Kurzbart E, Mares AJ: Preduodenal portal vein causing duodenal obstruction associated with situs inversus, intestinal malrotation, and polysplenia: a case report. *J Pediatr Surg* 2002;37:E5.
10. Knight G: An anomalous portal vein with its surgical dangers. *Ann Surg* 1921;74:697-699.
11. Esscher T: Preduodenal portal vein- a cause of intestinal obstruction? *J of Pediatr Surg* 1980;15:609-612.
12. Fernandes ET, Burton EM, Douglas Hixson S, Hollabaugh RS: Preduodenal portal vein: surgery and radiographic appearance. *J of Pediatr Surg* 1990;25:1270-1272.