

CLINICAL STUDIES

Identification and Management of Abdominal Compartment Syndrome in the Pediatric Intensive Care Unit

FRANCISCO J. DIAZ, MD; ALICIA FERNANDEZ SEIN, MD; FELICITA GOTAY, MD

Objective. Asses if Abdominal Compartment Syndrome (ACS) increases the morbidity and mortality of the Pediatric Intensive Care Unit patients and if early recognition and intervention with decompressive therapy will alter outcome and decrease mortality.

Setting. Pediatric Intensive Care Unit of the University Pediatric Hospital –UPR

Patients. All patients admitted to the PICU from July 1, 1999 to June 30, 2002 were enrolled in the study. Those having a distended and/or tense abdomen on physical examination were identified at risk for intra-abdominal hypertension (IAH). IAH was diagnosed if the intra-abdominal pressure (IAP) was above 10 mmHg and with ACS if the IAH was accompanied by: hemodynamic instability, oliguria or anuria, metabolic acidosis and respiratory deterioration.

Measurements and Main Results. 1052 patients were admitted to PICU. Ten patients with evidence of ACS

were identified with an incidence of 0.9%. Ages ranged from 6 weeks to 12.3 years. Peak intravesical pressure measurements ranged from 17 to 39 mmHg. Inspiratory pressure was raised from a mean of 21.2 to 32.0 cmH₂O. The PCO₂ increased from a mean of 35.1 to 63 torr and the pH decreased from a mean of 7.40 to 7.12. Overall mortality was 40% for this patient population.

Conclusions. The outcome of pediatric critical care patients depends on multiple variables. Now there is evidence that in a select group of patients IAH and ACS play a significant role in their morbidity and mortality. This makes it mandatory for clinicians taking care of this population to be increasingly aware of this condition.

Key Words: Abdominal compartment syndrome; Intra-abdominal hypertension; Children; Pediatrics; Intra-vesical pressure; Percutaneous decompression; Management

For many years the etiology and pathophysiology of the Compartment Syndrome in the extremities and in the injured brain have been well documented in the medical literature. Continuous monitoring, frequent clinical assessment and interventions have prevented tissue loss and improved patient outcome. The Abdominal Compartment Syndrome (ACS) has just recently been recognized as a major determinant of morbidity and mortality when left unattended.

The abdominal cavity is surrounded by the abdominal wall, psoas muscle, vertebral column, diaphragm and pelvis, which limit increases in abdominal contents. Therefore, a change in volume of its content will cause a change in the intra-abdominal pressure. This increase in the abdominal pressure will be tolerated up until a point when further increases in pressure will adversely affect circulation and tissue perfusion.

In 1999, we managed a 14y/o boy involved in a car accident who sustained 60% TBSA burn lesion and inhalation injury. After effective initial fluid resuscitation and management of acute respiratory distress syndrome (ARDS), he developed progressive abdominal distention, ileus, oliguria, hemodynamic instability and hypoxemia. Intra-abdominal pressure (IAP) was 39 mmHg. He developed multi-organ failure and died within 48 hours. This patient prompted us to develop a protocol for measuring IAP, trying to abort similar outcomes in our critically ill pediatric patients. Measuring the intra-vesical pressure through a urinary catheter has been validated as a tool for monitoring intra-abdominal pressure. (1) The absolute level of IAP at which ACS occurs is unknown.

The purpose of this study is to asses if ACS increases the morbidity and mortality of the Pediatric Intensive Care Unit (PICU) patients and if early recognition and intervention with some form of decompressive treatment will alter outcome and decrease mortality.

Materials and Methods

The study was performed at the PICU of the University Pediatric Hospital of the University of Puerto Rico, a level

Pediatric Critical Care Section, University Pediatric Hospital, University of Puerto Rico

Address correspondence to: Francisco J. Diaz, Pediatric Critical Care, Department of Pediatrics, University of Puerto Rico, PO Box 365067, San Juan, PR 00936-5067. E-mail: frankpedcc@yahoo.com

I unit. It is the pediatric burn, trauma and critical care center for the island of Puerto Rico. The unit has an average of 350 admissions per year of children with ages ranging from the neonatal period to 16 years.

All patients admitted to the PICU from July 1, 1999 to June 30, 2002 were enrolled in the study. Those having a distended and/or tense abdomen on physical examination were identified at risk for intra-abdominal hypertension (IAH) and were monitored with serial intra-abdominal pressure measurements. IAH was diagnosed if the intra-abdominal pressure (IAP) was above 10 mmHg and with ACS if the IAH was accompanied by: hemodynamic instability requiring volume resuscitation and/or initiation or increases in vasopressor support; oliguria or anuria; metabolic acidosis (base deficit over 5 mmol/L); and increases in ventilatory pressures and the fraction of inspired oxygen (FiO₂) due to worsening of respiratory acidosis and hypoxemia.

IAP was assessed indirectly by measuring the intra-vesical pressure as previously described by Cheatham and Safcsak (1). We modified the method by decreasing the volume to be infused to the bladder because this method was originally described for adult patients. This has been reported previously in ACS studies of pediatric patients (2). In our system a 3-way stopcock is connected to a disposable pressure transducer system. A 20 ml syringe is connected to the stopcock. An 18 gauge angiocatheter is inserted into the aspiration port of the urinary catheter using aseptic technique. The infusion catheter is attached to the pressure tubing using the 3-way stopcock. The tubing is filled with normal saline solution and the system is calibrated to zero at the level of the symphysis pubis. In order to take a measurement the urinary catheter is clamped immediately distal to the angiocatheter, then 20 mL of normal saline if the patient weight is above 10 kg or 10 mL of normal saline if the patient weight is less than 10 kg are instilled into the urinary bladder using the syringe in the 3-way stopcock. The IAP is measured when continuity with the pressure transduction system is reestablished and at the end of expiration. After the measurement the clamp is removed and the bladder is allowed to drain. The volume of normal saline used in the measurement process was subtracted from the patient urinary output for that hour.

After the diagnosis of ACS was done some form of decompressive treatment was initiated, either exploratory laparotomy or placement of a percutaneous drainage to relieve IAP. The decision was taken based on the primary diagnosis of the patients, radiological evidence of significant presence of ascites to consider the percutaneous drainage and the clinical judgment of the Pediatric Intensivist and Surgeon in charge. If the

percutaneous drainage was used the albumin level of the ascitic fluid was measured and albumin losses were replaced (gm per gm) with Albumin 25%. This was done in an effort to keep the patients with adequate intravascular oncotic pressure but with a negative fluid balance.

In all patients vital signs, urine output, mechanical ventilator parameters, arterial blood gases were serially monitored. In patients identified at risk for IAH, the IAP was monitored every two hours and every hour if the IAP increased above 10mmHg.

Pre-ACS and during-ACS values were compared by using two-tailed paired Student's *t*-test. We considered *p* < .05 to be statistically significant.

Results

During 36 consecutive months, 1052 patients were admitted to the PICU. Ten patients with evidence of ACS were identified, with an incidence of 0.9%. Ages ranged from 6 weeks to 12.3 years, mean of 2.7 years, with a 4:1 male to female ratio (Table 1).

Eight patients developed ACS after admission to PICU during management of their primary condition. In only one patient ACS diagnosis was done at admission and in another with 70% TBSA burn during the first eight hours of fluid resuscitation.

Septic shock and hypoxemia were the physiologic events most frequently associated with the development of the ACS. Two patients were admitted with significant burn injury, one had 60% TBSA the other had 70% TBSA. Primary intra-abdominal pathology was identified in 4 patients, two had GI obstruction, one had NEC and another had an intra-abdominal malignancy. Of these four patients three also had concomitant septic shock and received aggressive fluid resuscitation. (Table 1)

Peak intra-vesical pressure measurements ranged from 17 to 39 mmHg, mean of 22.5 mmHg. Nine patients were on mechanical ventilation at the time the ACS was established and all required an increase in ventilation parameters. (Figure 1). Inspiratory pressure was raised from a mean of 21.2 to 32.0 cmH₂O, range 21 – 40 cmH₂O, this difference with statistical significance (*p*=0.004) (Figure 1); PEEP from 5.2 cmH₂O to a mean of 7.8 cmH₂O, range 5 – 13 cmH₂O (*p*=0.03). Seven required 100% oxygen administration due to severe hypoxemia from a mean FiO₂ of 0.63 to 0.87. During the acute episode of ACS all patients developed respiratory acidosis; the PCO₂ increased from a mean of 35.1 to 63 torr (*p*=0.001) (Figure 2) and the pH decreased from a mean of 7.40 to 7.12 (*p*=0.007). (Figure 3) Renal function deteriorated during the episode of ACS. BUN increased in all our patients from a mean of 16.4 to 21.3 mg/dl, range from 9 to 46 mg/dl.

Table 1. Patient description

Patient #	Age	Sex	Diagnosis	Peak IAP mmHg	Treatment	Outcome
1	14 y/o	M	60% TBSA burn and inhalation injury, ARDS	39	Laparotomy	Died
2	6 w/o	M	GI obstruction with dysmotility	17	Laparotomy	Died
3	2 m/o	M	Kwashiorkor, zinc deficiency	27	Abdominal tube	Survived
4	5 m/o	F	Septic Shock	20	Abdominal tube	Survived
5	2 y/o	M	BPD; NEC, Septic Shock	18	Hemodialysis	Survived
6	1 y/o	M	Neuroblastoma s/p nephrectomy, Renal failure	23	Supportive	Died
7	3 y/o	F	Abdominal rhabdomyosarcoma	19	Abdominal tube	Survived
8	8 y/o	M	70% TBSA burn s/p Escharotomy (abdomen, chest, extremities)	24	Supportive	Survived
9	3 m/o	M	Arthrogriposis, Septic shock, GI Obstruction, UGIB; Seizures, Respiratory failure	22	Abdominal tube	Died
10	8 m/o	M	BPDSepic Shock, MSOF	21	Abdominal tube	Survived
			Caudal Regression Syndrome with Respiratory arrest due to UAO, Septic Shock, MSOF, Budd Chiari			

TBSA, total body surface area; ARDS, acute respiratory distress syndrome; GI, gastrointestinal; MSOF, multisystem organ failure; BPD, bronchopulmonary dysplasia; NEC, necrotizing enterocolitis; UGIB, upper gastrointestinal bleeding; UAO, upper airway obstruction.

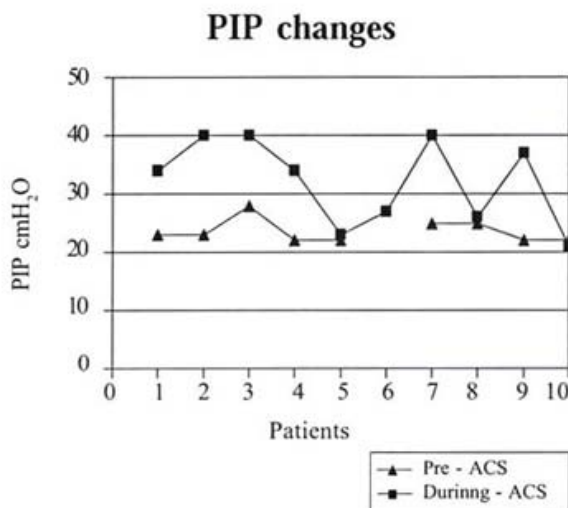


Figure 1. Changes observed in the positive inspiratory pressure ventilation before and during the episode of ACS. Patient #6 was spontaneously breathing prior to ACS. $p=0.004$

As intra-vesical pressure increased, all ten patients developed progressive respiratory deterioration, hemodynamic instability, poor perfusion, and oliguria. Many interventions were attempted to correct the physiologic derangements: fluid resuscitation, inotropic support, increased ventilatory assistance and FiO_2 , and use of neuromuscular blocking agents. These measures failed to improve patient's condition and even worst, they

compromised even more the ACS, promoting positive fluid balance and ascites, and increasing diaphragmatic distending pressures. The abdomen became increasingly distended and tense, the lung volumes and thoracic compliance decreased. Fluid balance control with furosemide infusions, colloid administration and fluid restriction was attempted in seven cases. Five cases failed to respond (71.4%) and required percutaneous abdominal tube placement for fluid drainage. Two patients had active Do Not Resuscitate (DNR) orders due to their primary condition and only supportive measures were provided without invasive procedures as requested by the families. Abdominal decompression was done by exploratory laparotomy in two patients, and by percutaneous placement of abdominal tube drainage system in five cases. One patient was treated with hemodialysis due to anuric renal failure. Rapidly after decompression the intra-vesical pressure dropped, urine output increased and the ventilator's parameters were decreased.

Eight patients had length of stay at PICU over 15 days. Overall mortality was 40% for this patient population. The two patients who underwent laparotomy died within 48 hours of the surgical procedure. A patient who developed ACS secondary to abdominal rhabdomyosarcoma was given only supportive therapy and subsequently died due to his primary disease. One patient with bronchopulmonary dysplasia (BPD) with superimposed pneumonia and worsening hypoxemia developed multisystem organ failure (MSOF) and died.

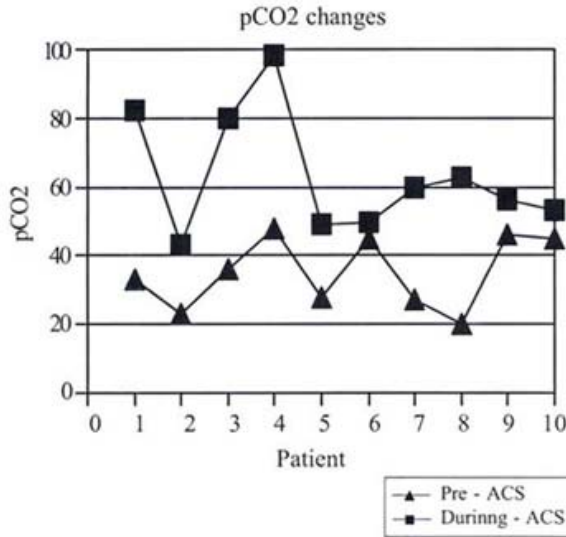


Figure 2. Changes in pCO2 values before and during episode of ACS. $p = 0.001$

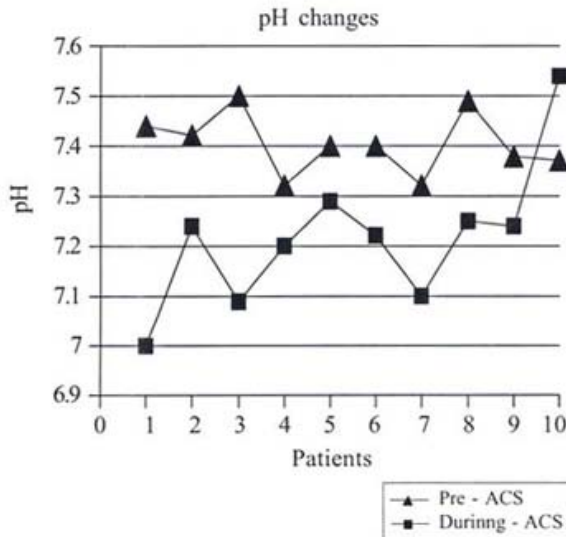


Figure 3. Changes in pH values observed before and during the episode of ACS $p = 0.007$

Discussion

Abdominal Compartment Syndrome was first described in 1984 by Krohn et al. (3) in a patient after surgery for aortic aneurysm. Since then it has been more frequently associated with abdominal trauma, surgery, peritonitis, ascites, and following fluid resuscitation in burned patients. IAH is likely to develop in any condition or event that may cause an acute augmentation of intra-abdominal volume.

Measuring the intra-vesical pressure through a urinary catheter has been validated as a tool for monitoring intra-abdominal pressure.(1) Normal IAP is considered to be zero (equal to atmospheric pressure) or less if the patient is breathing spontaneously and slightly positive if the patient is in positive pressure ventilation as intrathoracic pressures get transmitted to the abdominal cavity. The absolute level of IAP at which ACS occurs is unknown and most probably varies according to the individual patients. Abdominal Compartment Syndrome occurs when elevated IAP produces systemic signs and symptoms of intestinal and renal hypoperfusion and respiratory compromise. Continuous monitoring of the IAP permits early detection of IAH and aggressive intervention to prevent or reverse organ failure and improve patient's outcome.

Richardson and Trinkle, using an animal model, measured the effect of the IAP at the inferior vena cava (IVC). They found that in spite of a normal arterial blood pressure, at IAP above 10 mmHg there is a decrease in venous return and cardiac output and an increase in the peak inspiratory pressure and the intra-thoracic pressures (4). For this reason we decided to monitor patients more closely after this threshold of IAP of 10 mmHg and to diagnose ACS if clinical picture compatible as described previously.

Töns et al. (5) defined ACS as *primary* when IAH is caused directly by peritonitis, ileus or abdominal and pelvic trauma, and *secondary* as a result of forced closure of the abdominal wall after abdominal surgery. In our experience 90% of our cases with ACS were related to shock syndromes and fluid resuscitation. Ivy et al. (6) reported ACS in patients with shock that were fluid resuscitated with more than 250 mL/kg.

Over 120 patients with ACS have been published, but its frequency is probably underestimated and most of the reports are in the adult population. Ivatury et al. (7) found an overall incidence of 32.9% in 70 patients with major abdominal trauma. It occurred in 22.2% of patients treated prophylactically by mesh closure in contrast to 52% in patients that had their fascia sutured at laparotomy. Ertel W. et al. (8) described 311 consecutive patients with severe abdominal and/or pelvic trauma, in 17 (5.5%) the criteria of ACS were met. These criteria were the development of acute respiratory compromise, renal dysfunction and the presence of a rigid or tense abdomen. Meldrum et al. (9) reported an incidence of 14.5%. Ivy et al. (6) reported ACS in seven of ten patients with TBS burn over 70%. In one of the few reports in the pediatric population Beck et al. (2) found ACS in 0.6% of the admissions to PICU. This incidence is similar to our experience of 0.9%. This marked difference in the reported incidence of this condition

between adults and pediatric patients may be due either to age related differences or that the reports in the adult population are mostly from surgical units.

Radiologically all our patients had severe abdominal distention with decreased lung volumes without ascites if the etiology was associated to acute gastrointestinal obstruction or with significant ascites if it was associated with massive fluid resuscitation with some form of systemic inflammatory response. Epelman et al. (10) published the abdominal CT findings in 4 patients with ACS before decompression and found tense infiltration of the retroperitoneum, extrinsic compression of the inferior vena cava, direct renal compression or displacement and bowel wall thickening. An increased ratio of anteroposterior-to-transverse abdominal diameter (positive round belly sign) and bilateral inguinal herniation was found in two patients.

The evolution of ACS should be suspected in any patient with progressive hypoxemia, hypercarbia requiring high peak inspiratory pressures (PIP), oliguria, and a tense abdomen. All our patients demonstrated increases in PIP and PCO_2 that were statistically significant between pre-ACS values and during ACS values. Also a decrease in pH and in PaO_2 was evident. Oliguria or anuria was present in all our patients. This deterioration in clinical condition could explain the morbidity and high mortality in this group of patients. The overall mortality at our PICU for the same time period was 10%, in contrast with the 40% observed in the subgroup of ACS.

In a survey done by Mayberry JC et al. (11), on the prevention of the ACS, 71% of trauma surgeons indicated that they would decompress elevated IAP in postceliotomy patient if one or two signs of clinical deterioration were present, only 14% would decompress a patient for elevated IAP alone. DeCou et al. (12), published a series of three girls from 4-5 years with ACS treated by silo decompression, they were in profound shock requiring massive fluid resuscitation. The respiratory, renal, and hemodynamic function improved immediately in all 3 patients after decompression. In the series of Ertel W. et al. (8) emergency decompression resulted in a significant increase in cardiac index, tidal volume, oxygenation, and urine output and a marked drop in the IAP, HR, CVP, PIP, PCO_2 and lactate levels. The overall mortality was 22.8% (71/311); in the group with ACS it was 35.3%. Ivy reported a 100% mortality of patients with TBSA burn over 70% (6).

The diagnosis of IAH must be suspected, confirmed and treated aggressively in any patient with deteriorating respiratory function requiring high PIP, low PaO_2/FIO_2 ratios, oliguria and tense abdomen. IAP should be measured in all patients with risk factors,

and interventions started early in the course of the evolution to prevent the fatal effects of ACS.

Recently in the medical literature there are increasing reports of patients with ACS treated with percutaneous drainage (13-15). Latenser and others conducted a pilot study comparing percutaneous decompression with decompressive laparotomy for ACS in patients with burn injuries. They concluded that percutaneous decompression is a safe and effective method of decreasing IAH and preventing ACS in a selected (less than 80% TBSA burn) group of patients (15). In 2002 there was a report in the Journal of Trauma of two pediatric patients with ACS due to blunt trauma that were treated successfully with percutaneous paracentesis (14). In our study we used percutaneous decompression more frequently than exploratory laparotomy (Table 1). The mortality in this group was 20%, lower than the 100% noted in the patients that underwent laparotomy in this period of time. This could be due to a number of factors: the primary diagnosis, the severity of the illness or that the major surgical procedure worsened the hemodynamic status. Another important element could be the timing since diagnosis to decompression; the percutaneous decompression was performed at the bedside by the Pediatric Intensivist decreasing the time for the treatment of the ACS. Also we must consider that 80% of the patients treated with percutaneous drainage had been aggressively resuscitated with fluid volume for septic shock, they had no primary intra-abdominal pathology. Although this is a small group of patients this trend warrants further investigation.

We have seen positive results when decompression is performed at levels of IAP of less than 20 mmHg. The overall death rate was 40% this compares favorably with previously reported mortality of 60% in the PICU setting (2), and markedly improves the usually fatal outcome of untreated ACS (17).

With this past experience we are currently measuring IAP in patients at risk of developing ACS and the decompression is being done more promptly at pressures of 15 to 20 mmHg depending on the patient's condition. We plan to evaluate this new approach since it seems to be improving outcome.

Conclusion

The outcome of pediatric critical care patients depends on multiple variables. Now there is evidence that in a select group of patients IAH and ACS play a significant role in their morbidity and mortality. This makes it mandatory for clinicians taking care of this population to be increasingly aware of this condition, of its diagnosis and timely management to optimize patient outcomes. Pediatric

patients in critical condition at risk for IAH and ACS should be closely monitored in order to be recognized and ideally prevented or adequately treated. In our experience when the etiology of the IAH and ACS is aggressive fluid resuscitation for shock syndromes and significant ascites is evidenced, percutaneous abdominal decompression is an effective and safe alternative of treatment.

Resumen

El Síndrome de Compartimiento Abdominal esta siendo descrito cada vez más en la literatura médica, sin embargo, la mayoría de los estudios y los pacientes descritos son de la población adulta. Es nuestra impresión que probablemente este síndrome esta siendo subestimado en la población pediátrica. En la Unidad de Intensivo Pediátrico del Hospital Pediátrico Universitario de la UPR se diagnosticaron 10 casos de este síndrome en un período de 36 meses. La morbilidad de estos pacientes se evidenció con un aumento en los parámetros de ventilación mecánica, deterioro hemodinámico y compromiso renal. La mortalidad de este grupo fue mayor (40%) que la descrita para el mismo período de la población total de nuestra unidad (10%). En la población pediátrica este síndrome debe ser más sospechado, diagnosticado y tratado agresivamente para poder mejorar su morbilidad y mortalidad.

Acknowledgement

The authors gratefully acknowledge the contribution of Aurea Gonzalez, RN, Coordinator, Pediatric Intensive Care Unit, University Pediatric Hospital, UPR for her involvement in the development of the protocol for measuring intravesical pressure and management of intra-abdominal hypertension and Abdominal Compartment Syndrome. Our thanks to all the nursing staff of our unit for their commitment and dedication to the care of our pediatric patients.

References

1. Cheatham ML, Safcsak K: Intra-abdominal pressure: A revised method for measurement. *J Am Coll Surg* 1998; 186:594-595

2. Beck R, Halberthal M, Zonis Z, Shoshani G, Hayari L, Bar-Joseph G: Abdominal compartment syndrome in children. *Pediatr Crit Care Med* 2001;2(1):51-56

3. Krohn IL, Harman PK, Nolan SP: The measurement of intra-abdominal pressure as a criterion for re-exploration. *Ann Surg* 1984; 199:28-30

4. Richardson JD, Trinkle JK: Hemodynamic and respiratory alterations with increased intra-abdominal pressure. *J Surg Res* 1976; 20(5):401-4

5. Töns C, Schachtrupp A, Rau M, Mumme T, Schumpelick V: Abdominal compartment syndrome: prevention and treatment. *Chirurg* 2000 Aug;71(8):918-26

6. Ivy ME, Atweh NA, Palmer J, Possenti PP, Pineau M, D'Aiuto M: Intra-abdominal hypertension and abdominal compartment syndrome in burn patients. *J Trauma* 2000 Sep;49(3):567-8

7. Ivatury RR, Porter JM, Simon RJ, et al: Intra-abdominal hypertension after life-threatening penetrating abdominal trauma: Prophylaxis, incidence, and clinical relevance to gastric mucosal pH and abdominal compartment syndrome. *J Trauma* 1998; 44:1016-1021

8. Ertel W, Trentz O: The abdominal compartment syndrome. *Unfallchirurg* 2001 Jul; 104(7):559

9. Meldrum DR, Moore FA, Moore EE, et al: Prospective characterization and selective management of the abdominal compartment syndrome. *Am J Surg* 1997; 174:667-672

10. Epelman M, Soudack M, Engel A, Halberthal M, Beck R: Abdominal compartment syndrome in children: CT findings. *Pediatr Radiol* 2002 May;32(5):319-22

11. Mayberry JC, Goldman RK, Mullins RJ, Brand DM, Crass RA, Trunkey DD: Surveyed opinion of American trauma surgeons on the prevention of the abdominal compartment syndrome. *J Trauma* 1999 Sep;47(3):509-13

12. DeCou JM, Abrams RS, Miller RS, Gauderer MW: Abdominal compartment syndrome in children: experience with three cases. *J Pediatr Surg* 2000 Jun;35(6):840-2

13. Corcos AC, Sherman HF: Percutaneous treatment of secondary abdominal compartment syndrome. *J Trauma* 2001 Dec;51(6):1062-4

14. Sharpe RP, Pryor JP, Gandhi RR, Stafford PW, Nance ML: Abdominal compartment syndrome in the pediatric blunt trauma patient treated with paracentesis: report of two cases. *J Trauma* 2002 Aug;53(2):380-2

15. Latenser BA, Kowal-Vern A, Kimball D, Chakrin A, Dujovny N: A pilot study comparing percutaneous decompression with decompressive laparotomy for acute abdominal compartment syndrome in thermal injury. *J Burn Care Rehabil* 2002 May-Jun;23(3):190-5

16. Perks DH, Grewal H: Abdominal compartment syndrome in the pediatric patient with blunt trauma. *J Trauma Nurs* 2005 Apr-Jun;12(2):50-4

17. Burch JM, Moore EE, Moore FA, Franciose R: The Abdominal Compartment Syndrome. *Surg Clin North America* 1996 Aug;76(4):833-42