

• REVIEW ARTICLE •

Extracorporeal Photopheresis: a Review on the Immunological Aspects and Clinical Applications

Zelma C. Chiesa-Fuxench, MD; José González-Chávez, MD

Extracorporeal photopheresis (ECP) was hailed as a new therapeutic concept for the treatment of diseases caused by aberrant T lymphocytes since it was first described more than twenty years ago. Advances in molecular biology and immunology have allowed a greater understanding of the mechanisms involved in ECP. As a result, ECP is being increasingly considered as a safe and promising immunomodulatory therapy with diverse clinical applications. At present ECP is approved by the FDA for the treatment of cutaneous T-cell lymphoma (CTCL). ECP is considered a relatively safe and promising immunomodulatory therapy with diverse clinical applications reported in the literature. ECP has been used in the treatment of patients following acute allograft rejection in cardiac, lung, renal or liver transplantation, graft-versus-host disease, systemic lupus erythematosus, systemic scleroderma, rheumatoid arthritis and pemphigus vulgaris. The use of ECP as a novel form of therapy is in constant evolution with newer studies focusing on the treatment of patients with Crohn's disease and the immunological effects of ECP in children with type 1 diabetes mellitus. However, because the exact mechanism by which ECP exerts its effects remains to be described in detail and because important questions regarding the use of ECP in the clinical setting, such as length of therapy or design of specific protocols, concomitant use of immunosuppressive therapy, patient characteristics, long term side effects, assessment of therapy efficacy and cost effectiveness continue to remain unanswered, the exact role of ECP cannot be fully established except in the case of patients with CTCL and GvHD. Nevertheless, future clinical studies with ECP can be done with the objective of designing more appropriate treatment protocols based on expected patient response and with a side effect profile that is fairly tolerable. [P R Health Sci J 2010;4:337-347]

Key words: Extracorporeal photopheresis, Immunology, Clinical applications

More than twenty years ago extracorporeal photopheresis (ECP) was hailed as a new therapeutic concept for the treatment of diseases caused by aberrant T lymphocytes (1). Nearly two decades later, advances in molecular biology, as well as immunology, have shed new light into the mechanisms of action involved in such process. In 1994, it was reported that nearly 70 medical centers worldwide were using this type of therapy, and by 2001 that number had more than doubled to approximately 150 centers worldwide with ECP being performed more than 200,000 times (2-3). ECP is considered a relatively safe and promising immunomodulatory therapy with diverse clinical applications reported in the literature (4). For example, ECP has been used in the treatment of patients following acute allograft rejection in cardiac, lung, renal or liver transplantation, acute and chronic graft-versus-host

disease (GvHD), systemic lupus erythematosus (SLE), systemic scleroderma (SSc), rheumatoid arthritis (RA) and pemphigus vulgaris (PV). It is also FDA approved for the treatment of cutaneous T-cell lymphoma (CTCL) (1). The purpose of this review is to discuss recent developments in the mechanism of action in ECP and its most common clinical applications.

Department of Dermatology, University of Puerto Rico School of Medicine, San Juan, Puerto Rico

The authors have no conflicts of interest to disclose.

Address correspondence to: Zelma C. Chiesa-Fuxench, Department of Dermatology, University of Puerto Rico School of Medicine, PO Box 365067 San Juan, Puerto Rico 00936-5067. Tel: (787) 765-7950 • Fax: (787) 767-0467 • Email: zelma.chiesa1@upr.edu

Mechanism of action

At first look, ECP appears to be a simple concept. Blood is removed from the patient and the buffy coat containing the majority of white blood cells is treated with methoxsalen, while the red blood cells are returned to the patient (Figure 1). Methoxsalen (8-MOP) is a molecule found in the plant *Ammi majus*, which remains biologically inert unless exposed to ultraviolet radiation (4). It is believed that in diseases of increased T lymphocyte proliferation, such as CTCL, pathogenic cells can be isolated in large enough quantities from a patient's blood sample. When this blood is passed through a UV light source, after being treated extracorporeally with 8-MOP, molecular changes such as DNA cross linking are known to occur in the exposed cells, including the pathogenic T lymphocytes, causing them to undergo apoptosis (Figure 2) (5). Studies in patients with chronic GvHD (cGvHD) have demonstrated that lymphocytes treated with ECP undergo apoptosis by the following means: 1) downregulation of Bcl2 protein, which has an anti-apoptotic effect; 2) upregulation of bax, which promotes apoptosis; 3) increased bax/Bcl2 ratio; 4) decrease in Bcl2 mRNA; and 5) increase in Fas antigen (6). However, because such a small percentage of mononuclear cells are obtained during any given time, and disease responsiveness is noted after reinfusion of the irradiated cells to the patient, direct cell death alone of pathogenic T cells could not be the only plausible explanation behind the mechanism of action of ECP.

Multiple studies have published results substantiating the fact that an immunological response was occurring following the reinfusion of irradiated T-cells which resulted in the development of anticolonotypic immunity. A breakthrough in understanding such a process was achieved when evidence was found that although monocytes were not affected by 8-MOP or exposure to UV radiation, they would transiently adhere to the walls of the flow chamber resulting in activation and differentiation of such cells into antigen presenting cells (APCs) (3). These cells would then be able to present the engulfed antigens, by way of MHC Class I molecules, to CD8+ cytotoxic T-cells which ultimately resulted in an immune response against those tumor cells which expressed the same antigens on their surface. These findings lead to the development of the term transimmunization (3). However, the idea that methoxsalen-treated monocytes do not undergo apoptosis when irradiated with ultraviolet radiation has been challenged. Lamioni et al. evaluated the effects of ECP *in vivo* and *in vitro* in ten transplanted patients with a diagnosis of chronic rejection (7). Their results demonstrated that not only do the activated lymphocytes undergo apoptosis, but monocytes, natural killer cells, as well as lymphocytes B and T, are also susceptible to apoptosis when treated with 8-MOP and are exposed to UVA (7). Another interesting point comes from the observations made by others in which transient adherence to the plastic flow chamber of monocytes and the presence of apoptotic

cells may even not be sufficient to induce differentiation of monocytes, resulting in the development of dendritic cells with a tolerogenic phenotype and function (8). APCs also recognize apoptotic leukocytes through TAM receptors. These receptors are important because they inhibit inflammation by promoting the production of anti-inflammatory cytokines such as IL-10 and TGF- β (9-10).

Several animal models have also been used to further understand the mechanisms behind ECP. Maeda et al. developed a murine model of contact hypersensitivity (CHS) to evaluate whether ECP could result in the development of immune tolerance through the induction of regulatory T-cells (T_{reg}) (11). Lymph node cells and splenocytes from mice sensitized to dinitrofluorobenzene were isolated and treated with 8-MOP and UVA *in vitro*. Intravenous injection of these cells into untreated naïve mice resulted in inhibition of immune response. This response was determined to be cell-mediated and antigen-specific based on the transfer of cells between previously treated and naïve mice. Those cells responsible for the transfer of immunity between both populations of mice were found to be a subset of T_{reg} with CD4+CD25+ markers (11). *In vitro* studies also demonstrated that an increase in these T_{reg} cells resulted in the increased production of the anti-inflammatory cytokines IL-10 and TGF- β which are both capable of inducing immune suppression. Further studies with a similar murine model found that ECP inhibited both the sensitizing (which takes place in the lymph nodes) and effector (which takes place in areas of inflammation) phases of CHS by way of increased IL-10 production and not by T_{reg} cells as had been previously thought (11-12). Nevertheless, the importance of T_{reg} cells in maintaining and inhibiting immune responses cannot be undermined.

The increased production of IL-10 induced by ECP has also been demonstrated in *in vitro* studies with human populations. Di Renzo et al. evaluated the effects of ECP on dendritic cell maturation and cytokine production in seven patients with GvHD (13). Their results demonstrated a down regulation of co-stimulatory molecules, needed for dendritic cell maturation and stimulation of T-cell responses, and an increased production of IL-10 by peripheral blood monocytes when co-cultured with monocytes previously treated with ECP (13). Yet, no correlation was found between a higher increase in IL-10 production and ECP response.

The balance between circulating T_{h1} and T_{h2} group of cells has also been a source of study in patients treated with ECP. Gorgun et al. treated 10 patients diagnosed with cGvHD with ECP on two consecutive days every two weeks for six months (14). Normalization of skewed CD4/CD8 ratios and increases in CD3-CD56+ natural killer cells were observed. Their results demonstrated that ECP alters lymphocyte proliferation *in vitro* by modulating the differentiation of dendritic cell subtypes, DC1 and DC2, and favoring a shift from a T_{h1} to a T_{h2} cytokine profile (14). Another group of regulatory T-cells which have

also been studied are the CD8+ suppressor T-cells (CD8+T_{sp}) because of their role in promoting tolerance induction by apoptotic cells. These CD8+ T_{sp} cells suppress the immune response by upregulation of the TNF-related apoptosis-inducing ligand (TRAIL) (15). However, additional studies are needed to evaluate the role of these cells in the mechanism of ECP.

More recently, the antigenic properties of sub-cellular particles from apoptotic lymphocytes, otherwise known as blebs, which were subjected to treatment with methoxsalen and UVA light, were characterized (16). Following therapy with methoxsalen and UVA light, inflammatory blebs released from apoptotic cells demonstrated an increase in CD5, a surface marker thought to contribute to immunosuppression, thereby conferring protection against autoimmunity, and a decrease in the exposure of CD28 and CD26 (16). Furthermore, these apoptotic sub-particles also showed an increased expression of CD8, a T-cell surface marker, which is also involved in the induction of immunologic tolerance. These findings were consistent with an immunosuppressive phenotype of surface markers. In this same study, researchers also found an increase in the expression of phosphatidylserine in apoptotic cells, which is recognized by phagocytosing macrophages, thereby leading to their anti-inflammatory clearance (16).

Describing the intricacies of ECP in detail continues to be a work in progress. As previously discussed, ECP, as a form of immunomodulatory therapy, alters the immune system in various ways; seeking a balance between tolerance and immunity. The most important aspects of the mechanisms behind ECP are summarized in Table 1 and Figures 1-4.

Clinical Applications

Cutaneous T-Cell Lymphoma (CTCL)

Through the years ECP has been used as a form of immunomodulatory therapy in a wide number of disorders including, cutaneous malignancies, solid organ transplant rejection, autoimmune diseases, and acute or chronic GvHD (5). Since being first introduced as an acceptable form of therapy for CTCL, ECP remains as the only FDA-approved selective anticancer form of immunization therapy (3). Edelson et al. performed one of the first studies with ECP in patients

with the leukemic variant of CTCL. A total of 37 patients were entered into the study, 29 classified as erythrodermic. Results showed that 27/37 (73%) patients with CTCL responded to therapy with ECP, with erythrodermic patients having an overall response rate of 83% (17). The initial treatment regimen consisted of a cycle of ECP on two successive days on a monthly basis (17). A follow-up retrospective study of 32 patients with CTCL was done with participants stratified into the following groups: erythrodermic, tumor-stage and widespread disease with relapse after one year of multimodal therapy (18). The majority of patients were classified as erythrodermic [22], with nineteen receiving ECP as their first line of therapy (86%) (18). Response to therapy was calculated based on the percentage and the degree of skin surface involvement with 5/22 patients clearing 75% or more of skin surface involvement; 10/22 demonstrating an improvement of 25% but less than 75%; and 4/22 demonstrating an improvement of less than 25% (18).

ECP is currently approved for the treatment of skin manifestations in all stages of CTCL, yet it is most commonly used as palliative treatment in patients with erythrodermic CTCL, including stage III and IVA, and those with Sézary syndrome (19). In a recently published review of 16 studies with patients classified as early-stage (IA, IB and IIA) CTCL, the use of ECP as monotherapy or with adjuvant therapy resulted in response rates that varied from 33 to 88% (20). Bisaccia et al. evaluated the role of ECP as monotherapy in a retrospective study of one of the largest cohort of CTCL patients available (n=69) (21). A total of 37 participants, of which 21 were classified as early-stage (IB=18, IIA=3), were treated with ECP as monotherapy for a minimum of six months. An overall response rate of 54% was observed, with 14% and 41% undergoing complete and partial remission, respectively. The overall response rate for early-stage CTCL, which included all T2, patients was 60% (21). Zic et al. also reported a similar response rate of 54% in 13 patients with early-stage CTCL (IB=5, IIA=8) treated with ECP and various forms of adjuvant therapy including: PUVA, methotrexate, corticosteroids, electron beam radiation, and retinoids (22). Their results also demonstrated that ECP could also be used successfully in patients with refractory CTCL (22). The use of GM-CSF, oral bexarotene and INF- α as adjuvant therapy has also been reported in other studies of patients with CTCL (23-25). In a prospective, clinical trial, Wollina et al. evaluated the use of ECP with IFN- α -2a in fourteen patients with CTCL stage IIA/IIB (25). Participants were treated with a combination of ECP using oral 8-MOP and subcutaneous injections of IFN- α -2a three times a week. The overall response rate was 50%, with stage IIA patients having a better overall response than stage IIB patients (60% vs. 25%). At follow up one year later the response rate was maintained at 46.2%, with

Table 1. Immunological aspects of extracorporeal photopheresis

1. Induction of apoptosis in pathogenic T cell clones
2. Activation and differentiation of Antigen Presenting Cells (monocytes)
3. Increase in the number of CD3- CD56+ natural killer cells
4. Normalization of inverted CD4/CD8 ratios
5. Attenuation in the capacity of dendritic cells to stimulate autologous or allogeneic T cells
6. Shift in cytokine production from a Th1 (inflammatory) to a Th2 (anti-inflammatory) profile
7. Induction of regulatory T lymphocytes CD4+ CD25+ (Tregs)
8. Increase in IL-10 and TGF- β
9. Decrease exposure of CD28 and CD86 surface markers in apoptotic blebs
10. Increased exposure of CD5 and CD8 surface markers in apoptotic blebs
11. Increased surface expression of phosphatidylserine on apoptotic cells.

stage IIa patients faring better than patients classified as stage IIb (55.6% vs. 25.0%) (25).

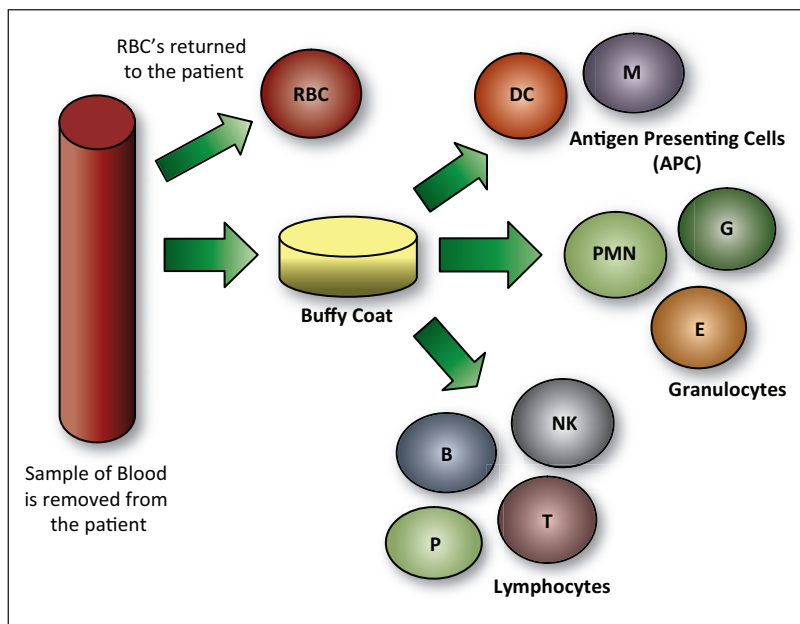


Figure 1. Isolation of the buffy coat and white blood cell components. (RBC's, Red Blood Cells; PMN, Polymorphonuclear cells; B, B cell lymphocytes; T cell lymphocytes; M, Monocytes; DC., Dendritic cells; P, Plasma cells; NK, Natural Killer cells; E, Eosinophils; G, Granulocytes; T, T cell lymphocytes.)

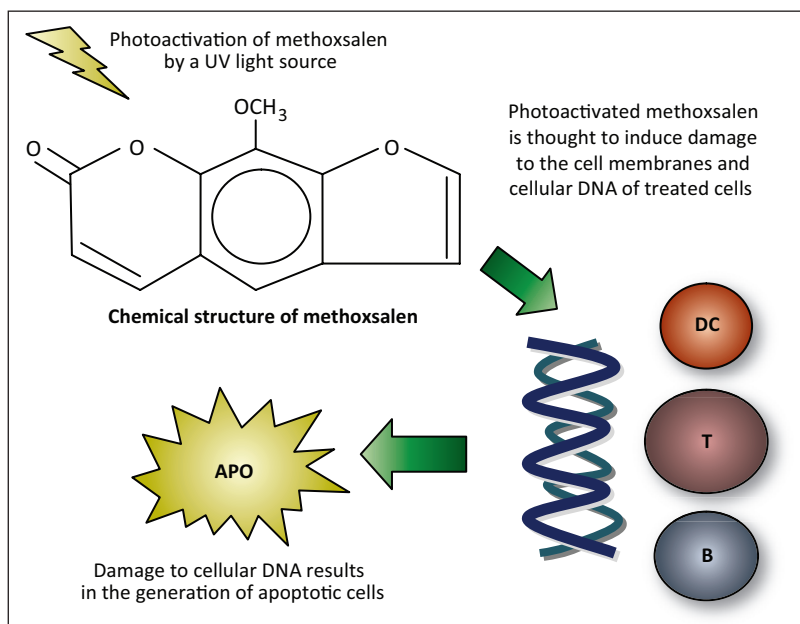


Figure 2. Exposure to photoactivated methoxsalen resulting in apoptosis of irradiated cells. (M, Monocytes; DC., dendritic cells; APO, Apoptotic cells)

Despite an overall positive experience with the use of ECP in CTCL, differences in study design, including the ECP protocols used; participants' baseline characteristics; clinical definition

of response; length of treatment and staging of CTCL prior to study entry, make it difficult to properly evaluate the use

of ECP in CTCL. Results from subsequent studies also show that the role of ECP in treating some stages of CTCL may be limited. In a randomized cross-over study comparing the effects of PUVA and ECP in patients with plaque stage (T2; IB) mycosis fungoides (MF) the use of ECP was not as effective as treatment with PUVA (26). Skin scores showed a marked improvement (decrease) in all patients during treatment with PUVA, contrary to therapy with ECP in which skin scores remained the same or increased in some cases (26). Furthermore, neither treatment appeared to have any effect over the circulating abnormal T-cell clones since these were detectable before and after therapy. One reason for which ECP may be ineffective in patients with patch stage MF is the fact that the majority of patients treated had low levels of circulating Sézary cells in the peripheral blood (26). Previous studies have demonstrated that patients with large numbers of circulating Sézary cells respond better to ECP as monotherapy, thereby implying the need for an increased tumor burden in order for therapy with ECP to be effective (26-27). In a phase I open label study by Girardi et al. 12 patients with leukemic CTCL demonstrated an improvement in the number of circulating malignant cells after therapy with ECP with a mean reduction of 50.1% (28). Furthermore, six patients classified as T4/B2 from this same group also demonstrated a significant improvement in absolute CD4 counts ($\geq 50\%$ drop) and/or normalization of CD4/CD8 ratios (2/6) (28). Since 1987, more than thirty studies have evaluated the use of ECP in CTCL, and patients with erythrodermic CTCL were found to have a higher response rate (29). In patients with erythrodermic CTCL, the U.K. Consensus Statement on the use of ECP for CTCL determined that there is good/fair clinical evidence to support its use in this group of patients and that there is also good evidence to reject its use in patients with non-erythrodermic CTCL (29). In 2002, Knobler and Warmuth reviewed the case of one of the

first patients with CTCL treated with ECP (30). The patient, a 90 year-old white woman, was initially diagnosed in 1983 with stage IVA CTCL. In 1985 she began therapy with ECP

after recurrence of her disease despite being previously treated with PUVA. In 1992 she was being treated every 8 weeks with ECP and since then tapering of therapy has been continued successfully with ECP currently being done every 15 weeks. No significant side effects have been reported as of yet (30). Zic et al also published results showing that ECP could induce long-term clinical remission in a small group of patients (22).

Several guidelines exist for the use of ECP in patients with CTCL. Guidelines from the National Cancer Institute in the United States list the use of ECP as a palliative treatment option in patients with CTCL stage III and for patients with stage IV in addition to radiotherapy (29, 31). The British Association of Dermatologists and the U.K. Cutaneous Lymphoma Group, as well as the European Organization for Research and Treatment of Cancer (EORTC) in mycosis fungoides and Sézary syndrome, recommend the use of ECP for patients with erythrodermic CTCL (29, 32-33). Both of these offer recommendations on treatment protocols and maintenance therapy schedules, as well clinical and laboratory parameters for determining response to therapy.

Solid Organ Transplants

Recipients of solid organ transplants continue to face challenges because of the potential for allograft rejection. The use of immunosuppressive therapy in this population poses the threat of potentially fatal conditions such as infections or malignancies, including lymphomas. Although results from prospective studies are not available, multiple case reports and other anecdotal data involving the use of ECP in transplant recipients of heart, lung, liver, kidney and allogeneic stem cell transplantation can be found in the literature (2, 4, 34-35). Of particular interest, a study by Barr et al. showed a statistically significant reduction in the number of acute rejection episodes in patients of heart transplants treated with ECP and triple drug immunosuppressive therapy without an increase in the incidence of infections (34). In this study, no increase in rejection episodes was noted six months

after the discontinuation of ECP and there was also a detectable decrease in the amount of CMV DNA suggesting the possibility of a direct antiviral effect by ECP (34). Other studies have also shown favorable results in heart transplant recipients including reversal of allograft rejection episodes and tapering of immunosuppressive drugs (36-38).

Although data involving ECP and other types of solid organ transplants is more limited, a study of recipients of liver transplants demonstrated that the use of ECP allowed for a reduction in immunosuppressive therapy, was well tolerated and showed no added mortality or morbidity in three of the five patients involved (35). In kidney transplant recipients, the use of ECP has also yielded positive results with measurable decreases in creatinine levels, improvement in biopsy findings and a decrease in immunosuppressive therapy in three of four patients treated (4, 39).

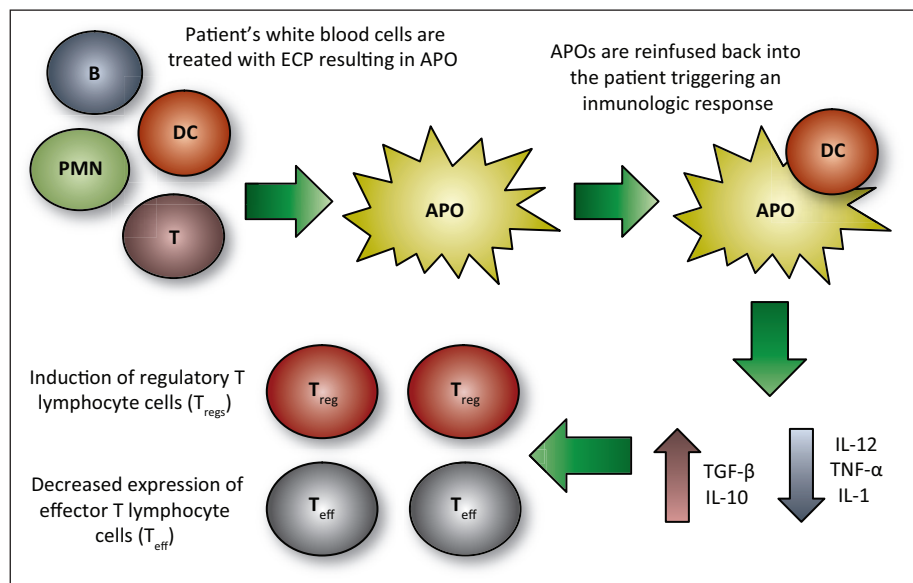


Figure 3. Induction of immune tolerance by extracorporeal photopheresis (PMN, Polymorphonuclear cells; B, B cell lymphocytes; T cell lymphocytes; M, Monocytes; DC., dendritic cells; APO, Apoptotic cells; T_{reg}, Regulatory T cell lymphocytes; T_{eff}, Effector T cell lymphocytes.)

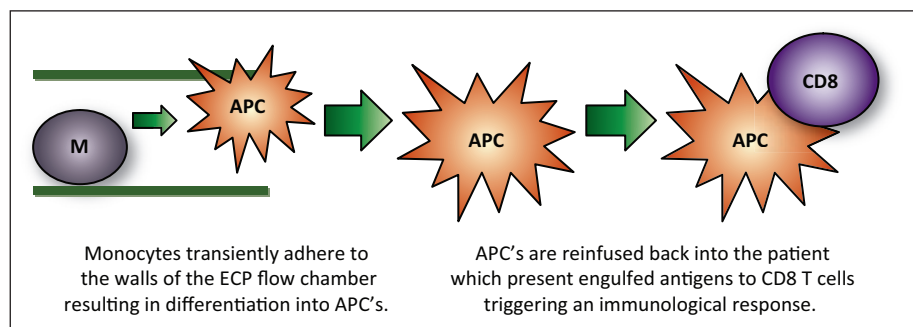


Figure 4. Transimmunization: Monocytes adhere to the ECP flow chamber's walls resulting in differentiation into antigen presenting cells. (M, Monocytes; DC., APC, antigen presenting cells; CD8 T cell lymphocytes.)

The use of ECP in lung transplant recipients has also been described favorably in patients with refractory lung allograft rejection. In a study by Benden et al. a statistically significant decrease in lung function decline was observed in patients with progressive bronchiolitis obliterans syndrome after 12 cycles of ECP (Pre-ECP FEV1: 112 mL/month vs. Post-ECP FEV1: 12 mL/month). In this same study clinical stabilization was also achieved in patients with recurrent allograft rejection (40).

Graft-versus-Host Disease

In patients with allogeneic stem cell transplants, GvHD continues to be a threat, representing a major cause of morbidity and mortality. Treatment of GvHD is mostly based on the use of steroids and other immunosuppressive agents as initial modes of therapy (41). In a review by Carcagní et al. the use of ECP in patients with steroid dependent or refractory acute GvHD and chronic GvHD shows promise over other forms of therapy since it allows for a more selective form of immunosuppression with limited side effects (41). ECP has been used in the treatment of steroid and immunosuppressive-refractory GvHD for the past ten years (33).

Chronic Graft-versus-Host Disease (cGvHD)

Over time, results from multiple studies in patients with chronic GvHD (cGvHD) support the use of ECP as a viable form of therapy (41-47). In a study by Greinix et al., published more than ten years ago, 15 patients with extensive cGvHD were subjected to treatment with ECP for a median of 14 cycles. Participants were treated on two consecutive days every two weeks for three months, and then every four weeks until resolution of GvHD. Patients with cutaneous manifestations demonstrated a favorable response to ECP therapy, with improvements of post-inflammatory hyperpigmentation and the clinical appearance of normal skin in 80% (12/15) of patients. Mucosal and liver involvement also resolved completely in 100% (11/11) and 70% (7/10) of patients, respectively (42). Child et al. evaluated eleven patients with cutaneous cGvHD, four of which presented with mucosal and five with pulmonary involvement (43). All had failed prior therapies with corticosteroid and immunosuppressive agents. Participants were treated with ECP twice a month for four months and then once monthly for three more months. Three received ECP alone, whereas the rest continued with current immunosuppressive therapies. Nine patients demonstrated a reduction in skin scores with an overall improvement of 48%; while 3/4 patients with mucosal lesions also demonstrated an improvement (43). In contrast to findings reported by Greinix et al. improvement in liver and lung function were not as consistent.

In 2003, a study of 28 patients with advanced cGvHD, 20 with skin surface involvement of more than 50%, was carried out to demonstrate the clinical effects of ECP in cGvHD and identify any baseline or clinical parameters which could serve

as predictors of outcome (44). The ECP protocol consisted of two consecutive days of therapy every two weeks for the first four months, followed by monthly ECP. Skin scores were used to assess response to therapy and were calculated based on the percentage of surface area involvement containing sclerodermoid, lichenoid and/or erythematous lesions (44). Improvements in skin scores were most notable after three months of treatment with ECP with a median change from baseline of 46%. Also, of the six patients with severe ulcerative disease treated with ECP, half of them demonstrated an improvement in their condition as per clinical evaluation. However, only a partial response was observed in patients with liver involvement, none of them demonstrating complete normalization of liver function parameters after therapy with ECP (44). Similarly, only a minimal response was noted in lung GvHD. Both these findings are in accordance to those results previously published by Child et al. Furthermore, their analysis of patient's baseline characteristics and laboratory parameters was unable to identify any variables predictive of a favorable response to treatment (44). Foss et al. also found no differences in response to ECP therapy when patients were stratified as either favorable or unfavorable risk groups using the Akpek score for cGvHD which takes into account the presence or absence of thrombocytopenia, *de novo* versus progressive disease, and limited versus extensive skin involvement (45-46). In this study, 25 patients with steroid refractory cGvHD were enrolled to receive ECP on either two consecutive days every two weeks (17/25) or once a week (8/25) until stabilization of disease or best clinical response had been observed (45). Twenty patients demonstrated an improvement of skin manifestations with six experiencing softening of sclerodermatous changes and healing of skin ulcers in three. The overall response rate was 64%. Despite the fact that response rates were similar for those receiving weekly versus biweekly ECP, or in those starting therapy less than or more than 18 months after transplantation, patients with progressive development of cGvHD were more likely to respond to therapy versus those with *de novo* onset (64% vs. 36%) (45). Yet, Child et al., previously reported a higher response rate in participants who started therapy earlier than one year after onset of cGvHD (43). More recently, the results of a multicenter, prospective, phase two clinical trial, in which 95 patients with cutaneous cGvHD were randomized to receive either standard therapy or ECP plus standard therapy, demonstrated an improvement in Total Skin Score (TSS) of 14.5% in the ECP group versus 8.5% in the standard therapy group (47). Although their results were not statistically significant, most important is the fact that a greater number of patients in the ECP group were able to reduce their steroid doses by at least 50% during the duration of the study (25% vs. 12.8%). Results of steroid-tapering, and the decrease in immunosuppressive therapy made possible with the use of ECP in patients with cGvHD, have also been reported in other

studies. Foss et al. reported a reduction in steroid therapy in 13/25 study participants and 11/25 (44%) of patients were able to discontinue at least one other immunosuppressive medication (45). Apisarnthanarax et al. also reported a steroid sparing effect in 64% of patients (48). In the study by Flowers et al., patients treated with ECP were able to reduce their steroid doses by at least 50% vs. those treated with standard therapy alone (25 vs. 12.8%) (47). Because corticosteroids and immunosuppressive drugs, such as cyclosporine A (CsA), tacrolimus, and mycophenolate mofetil continue to be the mainstay of therapy in GvHD, and because the use of such drugs results in significant immunosuppression, the use of ECP in this group of patients may represent an advantage due to its fairly safe profile.

Acute Graft-versus-Host Disease (aGvHD)

The use of ECP in patients with acute GvHD (aGvHD) has also been evaluated. Greinix et al. performed ECP in six patients with aGvHD grades II and III unresponsive to therapy with prednisolone and CsA. The ECP protocol used has been previously described (42). Four patients (67%) experienced a complete resolution of symptoms with confirmation of results by histologic evaluation of skin biopsies. In the two patients with partial response to ECP, corticosteroid therapy was able to be discontinued and although 5/6 patients had to continue using CsA, a decrease in drug dosing was achieved (42). Comparable results were also observed by Perfetti et al. in their retrospective analysis of 23 patients with aGvHD who were subjected to ECP therapy with a similar schedule (49). A complete response rate in skin, liver and gut of 66%, 27% and 40% of the participants was noted. Complete responses of 70% and 42% were also obtained for aGvHD grade II and III, respectively. Whereas, patients classified as grade IV had a complete response rate of 0%.

In 2006 Greinix et al. performed yet another study which sought to evaluate the use of ECP as second line therapy in patients with steroid-refractory aGvHD (50). In this prospective phase two clinical trial, 38 participants who were already on therapy with prednisone and CsA were given 1 cycle of ECP for two consecutive days at either one to two week intervals until improvement, and then every two to four weeks until maximal response (50). A complete response was noted in patients with cutaneous (86%), liver (61%) and gut (61%) manifestations. Furthermore, a variation in response rates was noted depending on the grade of aGvHD. Those who were classified as grade II demonstrated a complete response rate of 86% (31/36), whereas response rates for grade III (7/13; 55%) and grade IV (3/10; 30%) were lower coinciding with previous results published by Perfetti et al. in which response rates lower as grade of aGvHD increases (49-50). Their results also demonstrated an improved overall survival at four years of 59% in patients achieving a complete resolution of aGvHD on ECP versus 11% for those

who were unable to achieve complete resolution (50). Messina et al. also reported a similar trend, with an overall survival at 5 years of 69% in responders and 12% in non-responders (51). In this study 33 patients with aGvHD, already on therapy with corticosteroids and CsA, were treated with ECP on two consecutive days/weekly during the first month, every two weeks during the second and third month, and then monthly for the following three months. A complete response in skin, gut and liver manifestations was noted in 76%, 75% and 60% of patients (51). Results from previous studies are promising, since most show an improvement of symptoms in patients with aGvHD, particularly those with cutaneous manifestations. However, there continues to be a number of limitations with the use of ECP in GvHD. These include the lack of multicenter clinical trials with a large cohort of patients; the effect of using additional immunosuppressive drugs before, during and after therapy with ECP; the time of onset from solid organ transplant-to rejection episode-to initiation of ECP therapy; and standardization of ECP treatment protocols.

Autoimmune diseases

Pemphigus vulgaris

Limited data has also been published regarding the use of ECP in a variety of autoimmune diseases. In a study by Rook et al. four patients with a diagnosis of pemphigus vulgaris refractory to therapy with corticosteroids and immunosuppressive drugs were treated with ECP, three of which were able to discontinue treatment because they experienced long term clinical remission (52). However, all three patients experienced relapses for which therapy with ECP was resumed. Some have suggested that simultaneously tapering both ECP and immunosuppressive drugs could have resulted in the recurrence of this condition (4). In a study by Wollina et al. seven patients with autoimmune bullous diseases, including pemphigus vulgaris and bullous pemphigus, were treated with ECP, as adjuvant therapy, on two consecutive days every four weeks. Six out of seven patients treated demonstrated a complete remission of skin and mucous membrane lesions without experiencing significant adverse events (53). Furthermore, concomitant immunosuppressive therapy was able to be tapered in those patients responsive to therapy with ECP. More recently, the case of a patient with severe pemphigus vulgaris treated first with plasmapheresis followed by maintenance therapy with ECP, demonstrated that the clinical response obtained by plasmapheresis was not maintained when therapy was switched to ECP (54). In this patient, immunosuppressive therapy with corticosteroids was started and gradually discontinued and the patient was started once again on plasmapheresis due to relapse. The authors do note that although plasmapheresis was superior to ECP, their observations cannot be used to make broader conclusions since they are based on solely one case (54). As of yet, the number of patients with pemphigus vulgaris treated with ECP continues to

be limited and since results from clinical trials with a large cohort of patients are not available, there is not sufficient evidence to support the use of ECP in patients with this disease.

Systemic Scleroderma

Although the most current guidelines for the management of systemic scleroderma (SSc) from the European League Against Rheumatism (EULAR) do not include the use of ECP as a possible mode of therapy, the use of such therapy in SSc has been evaluated in previous studies (55-56). A single blind, randomized, parallel group clinical trial comparing the use of D-penicillamine with ECP was carried out in patients with SSc with progression of skin involvement during the past six months. A total of 79 study participants were randomized to receive either ECP on two consecutive days per month or D-penicillamine (maximum dose = 750 mg/d) (56). Study parameters included skin thickness severity score, oral aperture and hand closure measurements, percent surface area involvement, as well as pulmonary function evaluation and skin biopsies. After six months of therapy statistically significant improvements in skin severity scores were noted in 21 of 31 (68%) participants receiving ECP, whereas 8 of 25 (32%) participants who received D-penicillamine showed an improvement (56). However, at the ten-month evaluation point the skin severity score, oral aperture and hand closure values had improved in both study groups. A decreased in thickness of the dermal layer was observed in skin biopsies of patients treated with ECP, which correlated with clinical improvement. None of the participants receiving ECP reported significant adverse effects and treatment was not discontinued; however, six patients were permanently discontinued from D-penicillamine due to adverse effects (56). A subsequent randomized, double-blind, placebo controlled clinical trial in 64 patients with SSc of recent onset (≤ 2 years) found a significant improvement in skin and joint lesions, when compared to initial baseline levels, in patients treated with ECP but not in patients receiving sham photopheresis (57). However, when both groups were compared no significant statistical difference was observed. The investigators believe that this could be attributed to the limited number of study participants or the stringent inclusion criteria (57). Despite the limited amount of research data that is available, results from these studies merit further investigation since they provide further evidence that the use of ECP in SSc early in the course of the disease may have a positive impact on skin and joint involvement. It is also a form of therapy that is well tolerated and with a very low incidence of adverse effects compared to other forms of therapy available, such as D-penicillamine (56).

Rheumatoid Arthritis

As is the case with other autoimmune diseases, studies exploring the use of ECP in rheumatoid arthritis (RA) are also very limited. In 1999, Malawista et al. performed a six month pilot study of seven patients with RA using ECP, with

condition of the affected joints and joint scores as their primary measure of improvement (58). Participants were subjected to ECP on two consecutive days per month. After three months of therapy the frequency of treatments was increased biweekly in three of the participants due to poor response to therapy. 58 Three of the participants (43%) showed an improvement in the condition of their joints, one participant (14%) demonstrated some improvement, but was not deemed a clinical success based on a predetermined clinical index score, and three other participants did not show evidence of improvement (43%). The average improvement in joint scores was 80% in participants responsive to ECP with results becoming evident at 12 to 16 weeks of therapy. After discontinuation of ECP, responders remained mostly pain free for two to three months, after which worsening of their arthritis was observed with one participant developing new subcutaneous nodules (58). In another study, seven subjects with RA refractory to other forms of treatment were treated with three cycles of ECP over a period of three weeks (59). The protocol design for this study was different from the study by Malawista et al. since the lymphocyte preparation was exposed to 8-MOP and UVA ex-vivo, rather than oral ingestion of 8-MOP, after which it was reinfused back into the patients. Their results showed an improvement of RA in all the participants, with two of them demonstrating a prolonged effect. 59 Recently, the case of a 50 year-old man with a diagnosis of Sézary syndrome and seronegative rheumatoid arthritis was reported as being successfully treated with ECP (60). The patient's CTCL had become unresponsive to standard treatment regimens including the use of psoralen-UVA, lymph node irradiation and chemotherapy. ECP was performed on two consecutive days per month for a total of six months, after which the patient began to demonstrate clinical improvement of both diseases. Maintenance therapy was given at a rate of 4, then 2, then 1 ECP cycle(s) per year for a period of six years during which time the patient remained in complete remission. Due to recurrence of his CTCL the patient was placed on maintenance therapy every eight weeks without further progression of his disease (60).

Although at one time promising, the role of ECP for the treatment of RA is still questionable. Furthermore, the British Photodermatology Group and the U.K. Skin Lymphoma Group stated in their 2001 meeting report that at this time there is poor evidence to support the use of ECP in patients with RA (33). As with other autoimmune diseases, well designed clinical trials are lacking. Despite ECP being well tolerated, issues such as the concurrent use of immunosuppressive therapy, study design and use of appropriate ECP protocols tailored to patients with RA instead of CTCL, and the continuation of additional cycles of ECP with hopes of achieving disease stabilization, merit further exploration.

Systemic Lupus Erythematosus

In 1992 Knobler et al. published the results of an open-label pilot study in a group of patients with SLE (61). Ten patients

with mild to moderate SLE, as per the SLE Activity Scoring System, were treated with ECP for two consecutive days every four weeks for a total of six months. Patients with central nervous system, cardiopulmonary or active renal compromise were initially excluded from the study. After completion of the first six months of therapy, treatment cycles were then given on two consecutive days bimonthly for another six months. Study participants were then followed for a total of 18 to 30 months (61). Eight patients completed the study and although no significant changes were noted in laboratory parameters, seven of these demonstrated improvement in their clinical scores, including skin and joint manifestations (61). However, to the best of our knowledge, there are no other clinical studies available which further examine the effect of ECP in patients with SLE. Since only a few anecdotal cases have been reported in the literature, the use of ECP merits further investigation before it can be considered as a viable form of therapy in patients with SLE (62-63).

Recent Developments

The use of ECP is in constant evolution with newer studies showing promise of its use. Such studies include using ECP for the prevention of restenosis in patients after percutaneous transluminal coronary angioplasty (64-65). Recent case reports have also been published suggesting the use of ECP as an adjunct therapy in patients with active, refractory Crohn's disease (CD) of moderate intensity, as well as a role in the treatment of patients with moderate to severe CD, intolerant to anti-TNF agents or other immunosuppressants (66-67). Karlsson et al. have recently published interesting data evaluating the immunological effects of ECP in children with type 1 diabetes mellitus (68). In this subgroup of patients, ECP induces a shift towards a T_{H2} cytokine pattern which, in accordance to previous results, may result in normalization of the T_{H1}/T_{H2} imbalance between pro-inflammatory and anti-inflammatory cytokines (12).

Extracorporeal photopheresis: common side effects and limitations

As previously stated, ECP is considered a relatively safe and promising form of immunomodulatory therapy (4). The most common side effects are headache, nausea, chills and low-grade fever. Other side effects such as hypotension, vasovagal syncope, septicemia, anemia, abnormal clotting response, skin infections over the venous access site, and bacterial endocarditis have also been reported (1, 4, 25, 33, 42, 69-70). ECP should also be considered as a safe and effective alternative for patients in whom other forms of available therapies are highly immunosuppressive. However, the use of ECP is not without contraindications since patients with severe renal, hepatic or cardiac impairment, in which minimal alterations in fluid balance and blood loss could potentially result in increased morbidity or mortality (33). Patients with hypersensitivity to

psoralen compounds and other coagulation disorders should also consider abstaining from such therapy.

Conclusion

As has been previously discussed, because data from large-scale, multicenter, prospective studies are still lacking, and because the mechanism of action of ECP is still not completely understood, the exact role of such treatment cannot be clearly established except in select cases of patients with CTCL and GvHD. As a result, important questions regarding the use of ECP in the clinical setting such as length of therapy or design of specific protocols; concomitant use of immunosuppressive therapy; patient characteristics; long term side effects of therapy; assessment of therapy efficacy; and the cost effectiveness of such therapy, continue to be unanswered. In the future, results from such studies could be used to establish appropriate treatment protocols based on expected patient response and with a side effect profile that is fairly tolerable for the patient, ultimately resulting in disease control and improvements in quality of life.

Resumen

La fotoféresis extracorpórea, o ECP por sus siglas en inglés, es un concepto terapéutico utilizado principalmente para el tratamiento de enfermedades causadas por linfocitos T aberrantes. Los adelantos continuos en los campos de biología molecular e inmunología han hecho posible un mayor entendimiento de cuáles son los mecanismos responsables de este proceso. Como resultado, la ECP se perfila como un tipo de terapia inmunomoduladora que es segura y efectiva, y que además cuenta con diversas aplicaciones clínicas. Al presente, la ECP está aprobada por la Administración de Drogas y Alimentos, o FDA por sus siglas en inglés, para el tratamiento de linfoma cutáneo de células T (CTCL). La ECP es considerada una terapia inmunomoduladora con una diversidad de aplicaciones clínicas. La misma ha sido utilizada en el manejo de pacientes con trasplantes de órganos sólidos como por ejemplo corazón, pulmón y riñones, con rechazo agudo y crónico; enfermedad de injerto versus huésped (GvHD), lupus sistémico eritematoso (SLE), artritis reumatoide (RA), escleroderma sistémico y pénfigo vulgar. El uso de ECP como una forma novel de terapia está en constante evolución con nuevas investigaciones enfocadas en los efectos de esta terapia en los pacientes con enfermedad de Crohn y los efectos inmunológicos de ECP en niños diagnosticados con diabetes mellitus tipo 1. Aun así, se desconocen ciertos aspectos de este tipo de terapia, como por ejemplo el tiempo de duración de la terapia o el diseño de protocolos específicos, el uso o no de terapia inmunosupresora en combinación, y cuáles son los efectos secundarios a largo plazo y su costo efectividad, que dificultan el poder esclarecer

en su totalidad cuál es el rol de ECP. Por tal razón, es necesario que aquellos estudios clínicos que sean diseñados en el futuro sirvan para poder contestar estas interrogantes con el fin de obtener resultados favorables para el paciente, a la vez que se logra mantener un perfil de seguridad aceptable.

References

- Edelson RL. Photopheresis: a new therapeutic concept. *Yale J Biol Med* 1989;62:565-77.
- Wolfe JT, Lessin SR, Singh AH, Rook AH. Review of immunomodulation by photopheresis: treatment of cutaneous T-cell lymphoma, autoimmune disease, and allograft rejection. *Artif Organs* 1994;18:888-97.
- Edelson RL. Cutaneous T cell lymphoma: the helping hand of dendritic cells. *Ann N Y Acad Sci* 2001;941:1-11.
- Oliven A, Shechter Y. Extracorporeal photopheresis: a review. *Blood Rev* 2001;15:103-8.
- Babic AM. Extracorporeal photopheresis: Lighting the way to immunomodulation. *Am J Hematol* 2008;83:589-91.
- Di Renzo M, Rubegni P, Sbrano P, Cuccia A, et al. ECP-treated lymphocytes of chronic graft-versus-host disease patients undergo apoptosis which involves both the Fas/FasL system and the Bcl-2 protein family. *Arch Dermatol Res* 2003;295:175-82.
- Lamioni A, Parisi F, Isacchi G, Giorda E, et al. The immunological effects of extracorporeal photopheresis unraveled: induction of tolerogenic dendritic cells in vitro and regulatory T cells in vivo. *Transplantation* 2005;79:846-50.
- Legitimo A, Consolini R, Failli A, Fabiano S, et al. In vitro treatment of monocytes with 8-methoxypsoralen and ultraviolet A light induces dendritic cells with a tolerogenic phenotype. *Clin Exp Immunol* 2007;148:564-72.
- Xia CQ, Campbell KA, Clare-Salzler MJ. Extracorporeal photopheresis-induced immune tolerance: a focus on modulation of antigen-presenting cells and induction of regulatory T cells by apoptotic cells. *Curr Opin Organ Transplant* 2009;14:338-43.
- Lemke G, Rothlin CV. Immunobiology of the TAM receptors. *Nat Rev Immunol* 2008;8:327-36.
- Maeda A, Schwarz A, Kernebeck K, Gross N, et al. Intravenous infusion of syngeneic apoptotic cells by photopheresis induces antigen-specific regulatory T cells. *J Immunol* 2005;174:5968-76.
- Maeda A, Schwarz A, Bullinger A, et al. Experimental extracorporeal photopheresis inhibits the sensitization and effector phases of contact hypersensitivity via two mechanisms: generation of IL-10 and induction of regulatory T cells. *J Immunol* 2008;181:5956-62.
- Di Renzo M, Sbrano P, De Aloe G, Pasqui AL, et al. Extracorporeal photopheresis affects co-stimulatory molecule expression and interleukin-10 production by dendritic cells in graft-versus-host disease patients. *Clin Exp Immunol* 2008;151:407-13.
- Gorgun G, Miller KB, Foss FM. Immunologic mechanisms of extracorporeal photochemotherapy in chronic graft-versus-host disease. *Blood* 2002;100:941-7.
- Griffith TS, Kazama H, VanOosten RL, Earle JK, et al. Apoptotic cells induce tolerance by generating helpless CD8+ T cells that produce TRAIL. *Immunol* 2007;178:2679-87.
- Stadler K, Frey B, Munoz LE, Finzel S, et al. Photopheresis with UV-A light and 8-methoxypsoralen leads to cell death and to release of blebs with anti-inflammatory phenotype in activated and non-activated lymphocytes. *Biochem Biophys Res Commun* 2009;386:71-6.
- Edelson R, Berger C, Gasparro F, Jegasothy B, et al. Treatment of cutaneous T-cell lymphoma by extracorporeal photochemotherapy. Preliminary results. *N Engl J Med* 1987;316:297-303.
- Heald PW, Perez MI, Christensen I, Dobbs N, et al. Photopheresis therapy of cutaneous T-cell lymphoma: the Yale-New Haven Hospital experience. *Yale J Biol Med* 1989;62:629-38.
- Geskin L. ECP versus PUVA for the treatment of cutaneous T-cell lymphoma. *Skin Therapy Lett* 2007;12:1-4.
- Miller JD, Kirkland EB, Domingo DS, Scull H, et al. Review of extracorporeal photopheresis in early-stage (IA, IB, and IIA) cutaneous T-cell lymphoma. *Photodermatol Photoimmunol Photomed* 2007;23:163-71.
- Bisaccia E, Gonzalez J, Palangio M, Schwartz J, et al. Extracorporeal photochemotherapy alone or with adjuvant therapy in the treatment of cutaneous T-cell lymphoma: a 9-year retrospective study at a single institution. *J Am Acad Dermatol* 2000;43:263-71.
- Zic JA, Stricklin GP, Greer JP, Kinney MC, et al. Long-term follow-up of patients with cutaneous T-cell lymphoma treated with extracorporeal photochemotherapy. *J Am Acad Dermatol* 1996;35:935-45.
- Duvic M, Hester JP, Lemak NA. Photopheresis therapy for cutaneous T-cell lymphoma. *J Am Acad Dermatol* 1996;35:573-9.
- Duvic M, Chiao N, Talpur R. Extracorporeal photopheresis for the treatment of cutaneous T-cell lymphoma. *J Cutan Med Surg* 2003;7:3-7.
- Wollina U, Looks A, Meyer J, Knopf B, et al. Treatment of stage II cutaneous T-cell lymphoma with interferon alfa-2a and extracorporeal photochemotherapy: a prospective controlled trial. *J Am Acad Dermatol* 2001;44:253-60.
- Child FJ, Mitchell TJ, Whittaker SJ, et al. A randomized cross-over study to compare PUVA and extracorporeal photopheresis in the treatment of plaque stage (T2) mycosis fungoides. *Clin Exp Dermatol* 2004;29:231-6.
- Evans AV, Wood BP, Scarisbrick JJ, Fraser-Andrews EA, et al. Extracorporeal photopheresis in Sézary syndrome: hematologic parameters as predictors of response. *Blood* 2001;98:1298-301.
- Girardi M, Berger CL, Wilson LD, Christensen IR, et al. Transimmunization for cutaneous T cell lymphoma: a Phase I study. *Leuk Lymphoma* 2006;47:1495-503.
- Scarisbrick JJ, Taylor P, Holtick U, Makar Y, et al. Photopheresis Expert Group U.K. consensus statement on the use of extracorporeal photopheresis for treatment of cutaneous T-cell lymphoma and chronic graft-versus-host disease. *Br J Dermatol* 2008;158:659-78.
- Knobler E, Warmuth I. Extracorporeal photochemotherapy: a case report and update. *Cutis* 2002;69:119-23.
- U.S. National Institutes of Health, National Cancer Institute. Mycosis fungoides and the Sézary Syndrome Treatment (PDQ[®]) 2007. Available at: <http://www.nci.nih.gov/cancertopics/pdq/treatment/mycosisfungoides/Patient/page5>.
- Trautinger F, Knobler R, Willemze R, Peris K, et al. EORTC consensus recommendations for the treatment of mycosis fungoides/Sézary syndrome. *Eur J Cancer* 2006;42:1014-30.
- McKenna KE, Whittaker S, Rhodes LE, Taylor P, et al. Evidence-based practice of photopheresis 1987-2001: a report of a workshop of the British Photodermatology Group and the U.K. Skin Lymphoma Group. *Br J Dermatol* 2006;154:7-20.
- Barr ML, Meiser BM, Eisen HJ, Roberts RF, et al. Photopheresis for the prevention of rejection in cardiac transplantation. Photopheresis Transplantation Study Group. *N Engl J Med* 1998;339:1744-51.
- Urbani L, Mazzoni A, Catalano G, De Simone P, et al. The use of extracorporeal photopheresis for allograft rejection in liver transplant recipients. *Transplant Proc* 2004;36:3068-70.
- Giunti G, Schürfeld K, Maccherini M, Tanganelli P, et al. Photopheresis for recurrent acute rejection in cardiac transplantation. *Transplant Proc* 1999;31:128-9.
- Dall'Amico R, Montini G, Murer L, Andreetta B, et al. Extracorporeal photochemotherapy after cardiac transplantation: a new therapeutic approach to allograft rejection. *Int J Artif Organs* 2000;23:49-54.
- Lehrer MS, Rook AH, Tomaszewski JE, DeNofrio D. Successful reversal of severe refractory cardiac allograft rejection by photopheresis. *J Heart Lung Transplant* 2001;20:1233-6.
- Dall'Amico R, Murer L, Montini G, Andreetta B, et al. Successful treatment of recurrent rejection in renal transplant patients with photopheresis. *J Am Soc Nephrol* 1998;9:121-7.

40. Benden C, Speich R, Hofbauer GF, Irani S, et al. Extracorporeal photopheresis after lung transplantation: a 10-year single-center experience. *Transplantation* 2008;86:1625-7.
41. Carcagni MR, De Aloe G, D'Ascenzo G, Rubegni P, et al. Extracorporeal photopheresis in graft-versus-host disease. *J Dtsch Dermatol Ges* 2008;6:451-7.
42. Greinix HT, Volc-Platzer B, Rabitsch W, Gmeinhardt B, et al. Successful use of extracorporeal photochemotherapy in the treatment of severe acute and chronic graft-versus-host disease. *Blood* 1998;92:3098-104.
43. Child FJ, Ratnavel R, Watkins P, Samson D, et al. Extracorporeal photopheresis (ECP) in the treatment of chronic graft-versus-host disease (GVHD). *Bone Marrow Transplant* 1999;23:881-7.
44. Seaton ED, Szydlo RM, Kanfer E, Apperley JF, et al. Influence of extracorporeal photopheresis on clinical and laboratory parameters in chronic graft-versus-host disease and analysis of predictors of response. *Blood* 2003;102:1217-23.
45. Foss FM, DiVenuti GM, Chin K, Sprague K, et al. Prospective study of extracorporeal photopheresis in steroid-refractory or steroid-resistant extensive chronic graft-versus-host disease: analysis of response and survival incorporating prognostic factors. *Bone Marrow Transplant* 2005;35:1187-93.
46. Akpek G, Zahurak ML, Piantadosi S, Margolis J, et al. Development of a prognostic model for grading chronic graft-versus-host disease. *Blood* 2001;97:1219-26.
47. Flowers ME, Apperley JF, van Besien K, et al. A multicenter prospective phase 2 randomized study of extracorporeal photopheresis for treatment of chronic graft-versus-host disease. *Blood*. 2008;112:2667-74.
48. Apisarnthanarax N, Donato M, Körbling M, Couriel D, et al. Extracorporeal photopheresis therapy in the management of steroid-refractory or steroid-dependent cutaneous chronic graft-versus-host disease after allogeneic stem cell transplantation: feasibility and results. *Bone Marrow Transplant* 2003;31:459-65.
49. Perfetti P, Carlier P, Strada P, Gualandi F et al. Extracorporeal photopheresis for the treatment of steroid refractory acute GVHD. *Bone Marrow Transplant* 2008;42:609-17.
50. Greinix HT, Knobler RM, Worel N, et al. The effect of intensified extracorporeal photochemotherapy on long-term survival in patients with severe acute graft-versus-host disease. *Haematologica* 2006;91:405-8.
51. Messina C, Locatelli F, Lanino E, et al. Extracorporeal photochemotherapy for paediatric patients with graft-versus-host disease after haematopoietic stem cell transplantation. *Br J Haematol* 2003;122:118-27.
52. Rook AH, Jegasothy BV, Heald P, Nahass GT, et al. Extracorporeal photochemotherapy for drug-resistant pemphigus vulgaris. *Ann Intern Med* 1990;112:303-5.
53. Wollina U, Lange D, Looks A. Short-time extracorporeal photochemotherapy in the treatment of drug-resistant autoimmune bullous diseases. *Dermatology* 1999;198:140-4.
54. Saraceno R, Ruzzetti M, Lanti A, Marinacci M, et al. Therapeutic options in an immunocompromised patient with pemphigus vulgaris: potential interest of plasmapheresis and extracorporeal photochemotherapy. *Eur J Dermatol* 2008;18:354-6.
55. Kowal-Bielecka O, Landewé R, Avouac J, Chwiesko S, et al. EULAR recommendations for the treatment of systemic sclerosis: a report from the EULAR Scleroderma Trials and Research group (EUSTAR). *Ann Rheum Dis* 2009;68:620-8.
56. Rook AH, Freundlich B, Jegasothy BV, Perez MI, et al. Treatment of systemic sclerosis with extracorporeal photochemotherapy. Results of a multicenter trial. *Arch Dermatol*. 1992;128:337-46.
57. Knobler RM, French LE, Kim Y, Bisaccia E et al. A randomized, double-blind, placebo-controlled trial of photopheresis in systemic sclerosis. *J Am Acad Dermatol* 2006;54:793-9.
58. Malawista S, Trock D, Edelson R. Treatment of rheumatoid arthritis by extracorporeal photochemotherapy: a pilot study. *Arthritis Rheum* 1991;34:646-54.
59. Hilliquin P, Andreu G, Heshmati F, Menkès CJ, et al. Treatment of refractory rheumatoid polyarthritis by extracorporeal photochemotherapy] *Rev Rhum Ed Fr*. 1993;60:125-30.
60. Macheiner W, Jantschitsch C, Graninger W, Pálóczy K, et al. Sézary syndrome and seronegative polyarthritis: treatment with extracorporeal photochemotherapy. *Am Acad Dermatol* 2003;48:220-6.
61. Knobler RM, Graninger W, Graninger W, Lindmaier A, et al. Extracorporeal photochemotherapy for the treatment of systemic lupus erythematosus. A pilot study. *Arthritis Rheum* 1992;35:319-24.
62. Lichtebalyohere A, Heller A, Stadler R. Extracorporeal photochemotherapy of therapy of refractory cases of systemic lupus erythematosus with urticarial vasculitis and pemphigus foliaceus. *Eur J Dermatol* 1996; 6:106-109.
63. Owsianowski M, Garbe C, Ramaker J, Orfanos CE, et al. Therapeutic experiences with extracorporeal photopheresis. Technical procedures, follow-up and clinical outcome in 31 disease[German]. *Hautarzt* 1996;47:114-123.
64. Bisaccia E, Palangio M, Gonzalez J, Klainer AS et al. Photopheresis. Therapeutic potential in preventing restenosis after percutaneous transluminal coronary angioplasty. *Am J Cardiovasc Drugs* 2003;3:43-51.
65. Bisaccia E, Klainer AS, Gonzalez J, Schwartz J, et al. Feasibility of photopheresis to reduce the occurrence of restenosis after percutaneous transluminal coronary angioplasty: a clinical pilot study. *Am Heart J* 2001;142:461-5.
66. Bisaccia E, Palangio M, Gonzalez J. Extracorporeal photochemotherapy for the treatment of refractory Crohn's disease. *Transfus Apher Sci* 2007;37:171-4.
67. Abreu MT, von Tirpitz C, Hardi R, Kaatz M, et al. Extracorporeal Photopheresis for the Treatment of Refractory Crohn's Disease: Results of an Open Label Pilot Study. *Inflamm Bowel Dis* 2009;15:829-36.
68. Faresjö MK, Ernerudh J, Berlin G, Garcia J, et al. The immunological effect of photopheresis in children with newly diagnosed type 1 diabetes. *Pediatr Res* 2005;58:459-66.
69. Gottlieb SL, Wolfe JT, Fox FE, Denardo BJ, et al. Treatment of cutaneous T-cell lymphoma with extracorporeal photopheresis monotherapy and in combination with recombinant interferon alfa: a 10-year experience at a single institution. *J Am Acad Dermatol* 1996;35:946-57.
70. Knobler E, Warmuth I, Cocco C, Miller B, et al. Extracorporeal photochemotherapy--the Columbia Presbyterian experience. *Photodermatol Photoimmunol Photomed* 2002;18:232-7.