

• CASE REPORTS •

Hyperthyroidism, Hyperfunctioning Thyroid Nodule, and Thyroid Cancer in a Young Female: a Rare and Unusual Coexistence

José Hernán-Martínez, MD, FACP*; María Uzcategui, MS IV†; Eric Corder, MS IV‡; Manuel Castillo, MD, FACS*; Samuel Sostre, MD, Ph D*, FACP; Luz Alicea, MD‡

The prevalence of concomitant thyroid carcinoma with Grave's disease has been reported to range from 0 to 10%. Many controversies exist in the literature regarding the diagnostic workup and management in these types of patients. We are reporting a case of a 31 year old woman who had Graves' disease, a palpable thyroid nodule, and results from a thyroid scan revealed a "hot" nodule. Interestingly, an ultrasound guided FNA of the "hot" nodule showed papillary thyroid microcarcinoma. Finally, a total thyroidectomy showed multilobar tumor involvement. The diagnostic tools employed to establish the proper management strategy for this patient were based on data in the literature that is full of discrepancies. The fact that Grave's disease occurs concomitantly with thyroid cancer, specifically the papillary type, is an indisputably rare combination. One rare feature on our clinical case was the reported malignancy of a papillary carcinoma within a "hot" nodule which usually is much less than 1%. Many studies describe an increasing incidence of Grave's disease patients with concomitant papillary thyroid carcinoma. One possible explanation for these findings could be improvements in medical technology of screening tools. We propose that, thyroid ultrasonography should be integrated in the diagnostic workup in patients presenting with Graves' disease, especially in those presenting with palpable nodules. Fine needle biopsy should not be restricted to cold nodules. [P R Health Sci J 2010;1:78-82]

Key words: Graves' disease, Thyroid stimulating immunoglobulin, Papillary thyroid carcinoma, Thyroid stimulating hormone, Nucleomegaly, Hot nodule, Psammoma bodies, Follicular carcinoma, Radioactive iodine, Thyroidectomy

Grave's disease, first described in 1825, is an autoimmune disease characterized by antibodies against the thyroid stimulating hormone (TSH) receptor. It manifests clinically as hyperthyroidism with diffuse goiter, exophthalmus, proximal muscle weakness, and pretibial myxedema. The prevalence of concomitant thyroid carcinoma with Grave's disease has been reported to range from 0 to 10% (1-2). The most commonly encountered thyroid cancer is of the papillary histologic subtype. When these two diseases coexist the clinical behavior has been described as ranging from benign to very aggressive. Previous studies indicate that 2 to 20% of autopsies have reported the incidental discovery of papillary thyroid carcinoma (1-2). Thyroid cancers occurring in combination with Grave's disease have a variable presentation and the literature divides it into incidental thyroid cancer and non-incidental thyroid cancer (3). Incidental thyroid carcinomas are nodules that usually measure less than 1 cm hence the name, thyroid microcarcinomas (1). They are rarely palpated during

physical examination. Non-incidental thyroid cancer refers to patients with Grave's disease who also have a thyroid nodule or cancer during the pre-operative workup. These thyroid cancers are usually larger than 1 cm.

Case Report

A 31 year-old woman was referred to our endocrinology clinic due to a palpable right lobe thyroid nodule on November

*San Juan Bautista School of Medicine and San Juan Bautista Medical Center Caguas, Puerto Rico, †ACP Student Member, ‡ACP Associate

This case report was awarded the First Prize in the Poster Division of the Clinical Vignette Competition at the American College of Physicians, Puerto Rico Chapter, held on October 10, 2008 at Restaurant Los Chavales Convention Center.

Address correspondence to: Call Box 4964 Caguas, Puerto Rico 00726-4964. Tel. (787) 653-0550 ext. 6030 • Email: m.interna@yahoo.com

2005. Laboratory data revealed normal thyroid function test, anti-microsomal and anti-thyroglobulin antibodies, calcitonin and thyroglobulin levels. A thyroid ultrasound, done elsewhere, was originally read as a heterogeneous thyroid with adenoma-like nodules on the right lobe. The left lobe was read as essentially homogeneous without cystic or solid components. A fine needle aspiration biopsy guided by palpation of the right lobe nodule failed to reveal any malignancy. She was lost to follow up and returned to the clinic in December, 2007 with the chief complaint of nervousness and palpitations. Her past medical history was negative for neck or head irradiation and for radioiodine therapy. There was a strong family history of thyroid disease but a negative history of thyroid cancer. The most remarkable physical findings were a regular pulse of 120 beats per minute, palpable diffuse goiter with palpable right thyroid nodule, exophthalmic measurement OD of 18 and OS of 20, lid lag and hyperreflexia. The laboratory data are illustrated on Table 1. The most remarkable laboratory results were a low TSH of 0.0001 IU/mL, a high T4, and borderline high Free T3, all of which are consistent with hyperthyroidism. Furthermore,

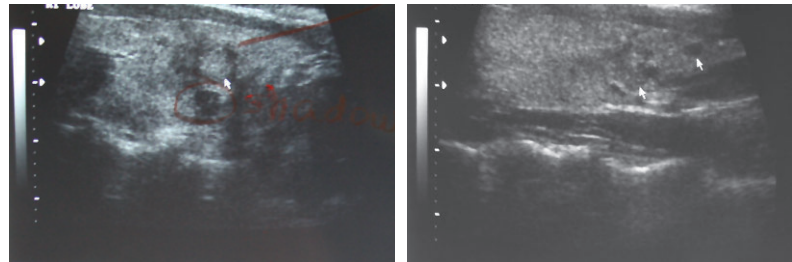


Figure 1. Thyroid ultrasonography showing posterior shadowing of the nodule and multiple speckled calcifications within the nodule.

Figure 2. Thyroid ultrasonography showing a hypogenic nodule of 1.2 X 0.9 X 0.7 cm at the midlobe, walls were somewhat irregular. A tiny cyst 0.2 cm was found in the lower lobe.

Table 1. Laboratory results pre-operatively

	Patient Results	Normal Values
TSH	0.010 IU/mL	0.47 – 5.04 IU/mL
TSH	0.0004 IU/mL	0.47 – 5.04 IU/mL
Free T3	3.4 pg/mL	1.5 – 3.5 pg/mL
T4	13.52 mg/dL	4.5 – 12.0 mg/dL
Thyroglobulin	124.0 ng/mL	0.5 – 5.5ng/mL
Thyroid Stimulating Immunoglobulin	211%	0 – 125%
Microsomal Antibodies	16.77 IU/mL	Negative less than 40
Thyroglobulin Antibodies	Less than 33.3 IU/mL	Negative less than 79

a high thyroid stimulating immunoglobulin confirmed the autoimmune etiology of the hyperthyroidism. Also remarkable were the elevated levels of quantitative thyroglobulin levels and normal levels of anti-thyroid antibodies. The original thyroid ultrasonography was revised by a nuclear medicine specialist. The right lobe measured 4.8 X 1.9 X 2.0 cm. It showed an echogenic pattern and revealed a solid nodule of 0.8 X 0.8 cm in the mid-lobe (Figure 1). The walls were irregular as well as the halo surrounding it. There was posterior shadowing of the nodule and multiple speckled calcifications within the nodule which raised the suspicion of malignancy. These findings were not previously reported. A hypogenic nodule of 1.2 X 0.9 X 0.7 cm was also identified within the right lobe (Figure 2). The left lobe measured 4.3 X 1.4 X 1.5 cm and exhibited an echogenic

pattern in which no nodules or cysts were detected. On the thyroid scan of 24 hours I 131, the uptake was 41.5% (normal: 9 – 36%). The gland revealed markedly increased tracer trapping (Figure 3) when compared to the salivary glands, which were not visualized in this study. In addition, there was a small “hot” nodule in the mid-right lobe, medially located. No “cold” thyroid nodules could be identified. A fine needle aspiration cytology of mid-right lower lobe nodule revealed “clusters of papillary caps of atypical follicular cells with nucleomegaly and nuclear grooves”, compatible with papillary carcinoma (Figure 4). The patient was started on Methimazole (30 mg) and Propranolol (40 mg) in March, 2008. Gradual reduction in the Methimazole dosage was done until September, 2008 when she achieved an euthyroid state (TSH 2.02). A total thyroidectomy was performed. On examination of the carotid compartments no nodules were palpated. Macroscopic examination of the thyroid gland revealed a weight of 15.5 g. The measurements were a left lobe 3.8 X 3.0 X 1.5 cm and a right lobe 4.3 X 4.0 X 1.8 cm. The capsule was purple/brown and smooth. On section, the right lobe showed two nodular lesions, which were pink/tan, measured 0.7 cm and 1.2 cm respectively (Figure 5). Sections through

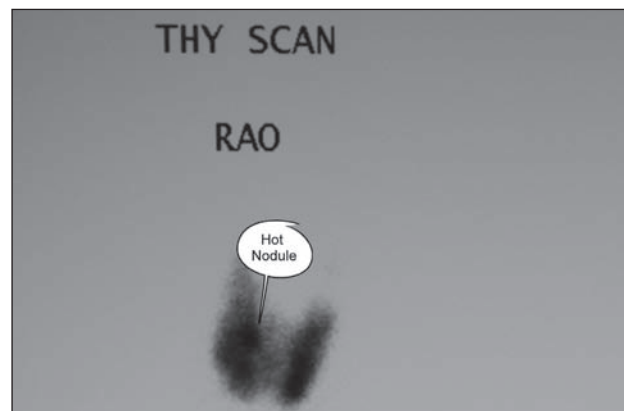


Figure 3. The uptake was 41.5% (normal: 9 – 36%). The gland revealed markedly increased tracer trapping when compared to the salivary glands.

the left lobe and isthmus revealed red/pink parenchyma. The pathologic diagnosis of the right lobe was papillary carcinoma in which the tumor measured 6 mm in diameter. It showed cystic degeneration and psammoma bodies. It was at 0.2 mm of the nearest inked margins. A second nodule that was previously identified as a hypogenic nodule on the thyroid ultrasonography was found to be a microfollicular adenoma. Incidentally, on the left thyroid lobe a micropapillary carcinoma, follicular-variant that measured 2 mm in diameter and totally excised was also identified. The thyroid isthmus was without significant pathological changes. Table 2 shows the histopathology description of the thyroid specimens. In the post-operative course no chemical or clinical hypocalcemic symptoms were noted. Radioactive iodine I 131 therapy was given and suppressive thyroid supplementation was started.

Table 2. Pathology results from specimen biopsy post-thyroidectomy

Right Thyroid Lobe	Right Thyroid Lobe	Left Thyroid Lobe
The tumor measured 6 mm in diameter. It showed cystic degeneration and psammoma bodies.	It was at 0.2 mm of the nearest inked margins.	Tumor measured 2 mm in diameter and appears totally excised.
Micropapillary Carcinoma	Microfollicular Adenoma	Micropapillary Carcinoma, Follicular -Variant. "Incidentaloma"

Discussion

Different studies around the world have confirmed the rare coexistence of Grave’s disease and thyroid cancer. The prevalence ranges from 1.1 to 7.1% (1). Papillary thyroid microcarcinoma is the most common histologic subtype, ranging from 42 to 100% in these series. Anaplastic thyroid carcinoma has also been associated with Graves’ disease however, it is even less frequently reported than the papillary type (3). Data reported in the literature has raised the issue concerning the clinical aggressiveness of thyroid cancer in patients with Grave’s disease. Some of these data revealed a poor prognostic clinical outcome when such a combination occurs, however recent clinical studies provide evidence on the contrary (4-6). The incidence of Grave’s disease with concomitant thyroid cancer, specifically the papillary type, is an indisputably rare combination. Evidence shows that patients with Graves’ disease may have cytopathologic findings that resemble papillary thyroid carcinoma. In these types of patients cytokeatin 19 may help in the differentiation between the two (7).

The diagnostic tools employed to establish the proper management strategy for this patient were based on data in the literature that is full of discrepancies. Preoperatively, the patient had a palpable thyroid nodule corroborated by ultrasonography. Thyroid ultrasonography showed “posterior shadowing” surrounding the nodule, a finding that may be suggestive of malignancy. Results from a thyroid scan showed a “hot” autonomous nodule. Despite this finding ultrasonography-guided FNA was performed yielding results concordant with papillary carcinoma. A total thyroidectomy was performed. It has been found that in patients with these concomitant conditions a better outcome is associated with the more aggressive approach (8). Gross examination of the thyroid specimen showed multifocal nodules that were not detected by thyroid ultrasonogram or by thyroid scan.

When multifocal nodules are diagnosed this is associated with a poor prognosis because it magnifies the metastatic potential of the cancer. Our patient had several influencing factors that might point towards a more aggressive clinical course: the elevated T4, TSI, and thyroglobulin levels pre-operatively, and the multifocal involvement within the two thyroid lobes.

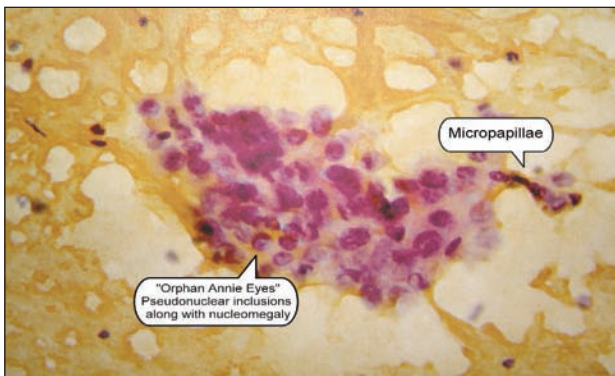


Figure 4. Fine needle aspiration cytology of mid-right lower lobe nodule revealed clusters of papillary caps of atypical follicular cells with nucleomegaly and nuclear grooves.

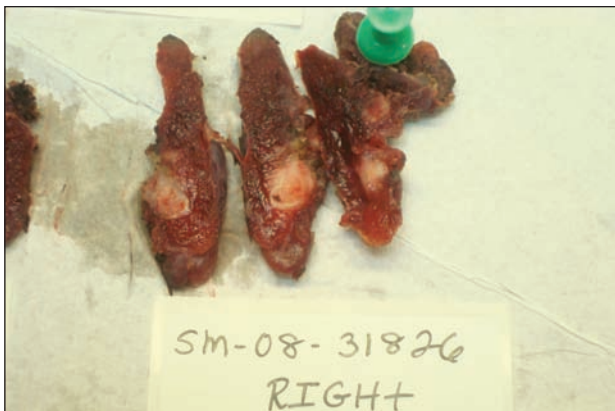


Figure 5. On gross examination, the capsule was purple/brown and smooth. On section, the right lobe showed two nodular lesions, which were pink/tan, measured 0.7 cm and 1.2 cm respectively. Sections through the left lobe and isthmus revealed red/pink parenchyma.

One rare feature on our clinical case was the reported malignancy of a papillary carcinoma within a "hot" nodule which usually is much less than 1% (1). The laboratory values, as described in the literature, as well as physical examination findings, FNA biopsy, and ultrasonography can be useful tools in predicting prognosis (1, 9). Some data suggests that in patients with these concurrent conditions, serum concentrations of T3 and T4 prior to anti-thyroid treatment were reliable prognostic indicators (10). These concentrations may predict aggressiveness and metastatic tendency in these types of patients (10). Past studies from the 1990s proposed that thyroid stimulating immunoglobulin (TSI) may play a role in determining aggressiveness of thyroid cancers in patients with Grave's disease (11). Recent clinical studies in 2007 reported that TSI levels were found to have an inverse correlation with the tumor size (5). While other publications support the hypothesis that TSI levels correlate with tumor growth, other investigators published data in 2008 that strongly suggests that TSI does not change the behavior of preexisting thyroid cancers (1, 3). Besides being expressed in normal thyroid tissue, TSH receptors are also expressed on the plasma membrane of benign and malignant thyroid tumors. Studies suggest that TSH stimulates thyroid tumor growth. This is supported by existing evidence showing that increasing TSH concentrations correlate directly with malignancy, reflecting a trophic effect promoting neoplasia and carcinogenesis (12). It has been reported that suppression of TSH by administering exogenous thyroid hormone is associated with reduced recurrence and mortality in patients with thyroid cancer (10).

Thyroid ultrasonography has become the most sensitive screening tool when screening for thyroid nodules and fine needle aspiration guided by ultrasonography has even better diagnostic accuracy than by palpation (9). When performing an ultrasound in a patient with Grave's disease there are some indicators that can raise the suspicion of malignancy. These indicators are based on characteristic impression of the nodule(s) such as irregularity, vascularity, and microcalcifications (8). Kim et al. recommends that all patients with Grave's disease, regardless of having a palpable nodule or not, should be screened using ultrasonography (9). This could be due to the fact that most of the papillary thyroid microcarcinomas that were found on those patients were incidental findings post-operatively (9). Our patient had a non-incidental papillary thyroid microcarcinoma of 6 mm that was detected by palpation. On post-operative histologic examination an incidental follicular variant of papillary thyroid microcarcinoma that measured 2 mm was discovered in the opposite lobe.

Conclusions

Many studies describe an increasing incidence of Grave's disease with concomitant papillary thyroid carcinoma. One possible explanation for these findings could be improvements in medical technology of screening tools. The discrepancies

in the literature regarding screening, diagnostic methods, epidemiology, disease course, and treatment, might be due to differences among the patient population. Geographic, genetic, ethnic, iodine intake, or other unknown factors may be responsible. In view of the lack of medical experience in Puerto Rico, regarding Grave's disease with concomitant thyroid carcinoma, we propose further prospective clinical studies to evaluate the prevalence and clinical course in these types of patients. We also recommend that thyroid ultrasonography should be integrated in the diagnostic workup in patients presenting with Graves' disease (13). Fine needle aspiration should not be restricted to cold nodules.

Resumen

Se ha reportado que la prevalencia de la enfermedad de Graves' en coexistencia con carcinoma del tiroide fluctúa entre 0 a 10%. Existen muchas discrepancias en la literatura acerca de los exámenes diagnósticos y el manejo en este tipo de pacientes. Una fémina de 30 años de edad fue referida a nuestra clínica de endocrinología por un nódulo palpable en el tiroide. En el ultrasonido del tiroide se encontró un nódulo hipoeoico con una sombra acústica posterior. Los resultados de la cintigrafía de tiroide reportaron un nódulo caliente. Finalmente, se le realizó una biopsia de aguja fina guiada por ultrasonido la cual demostró ser positiva para carcinoma papilar de tiroide. La tiroidectomía total demostró involucramiento multilobular. Las herramientas diagnósticas empleadas para establecer el manejo adecuado fueron basadas en literatura que esta llena de discrepancias. El hecho de que la enfermedad de Graves' exista concomitantemente con carcinoma papilar del tiroide es una combinación indiscutiblemente inusual. Un punto importante en nuestro caso es que la probabilidad reportada de que exista carcinoma papilar de tiroide dentro de un nódulo caliente es menos de 1%. Muchos estudios describen el aumento en la incidencia de la enfermedad de Graves' en coexistencia con carcinoma papilar de tiroide. Una posible explicación podría ser la mejoría en la tecnología de los instrumentos médicos. Nosotros proponemos que la ultrasonografía de tiroide sea integrada como manejo estándar en pacientes que sufren la enfermedad de Graves', especialmente en aquellos que tienen nódulos palpables. También, que la biopsia de aguja fina no debe estar restringida a nódulos fríos.

References

1. Phitayakorn R, McHenry C. Incidental thyroid carcinoma in patients with Graves' disease. *Am J Surg* 2008;195:292-297.
2. Ahmad A, Al-Omari, Haddad F. Case Report: Graves' disease and papillary thyroid cancer. *Saudi Med J* 2005;26:1280-1282.
3. Majima T, Komatsu Y, Doi K. Anaplastic thyroid carcinoma associated with Graves' disease. *Endocr J* 2005;52:551-557.
4. Lin JD, Kuo SF. Incidental and nonincidental papillary thyroid microcarcinoma. *Ann Surg Oncol* 2008;15:2287-2292.

5. Yano Y, Shibuya H. Recent outcome of Graves' disease in patients with papillary thyroid cancer. *Eur J Endocrinol* 2007;157:325-329.
 6. Chao TC, Lin JD. Surgical treatment of thyroid cancer with concurrent Graves' disease. *Ann Surg Oncol* 2004;11:407-412.
 7. Erkilic S, Emrah N. The role of cytokeratin 19 in the differential diagnosis of true papillary carcinoma of thyroid and papillary carcinoma-like changes in Graves' disease. *Endocrine* 2005;16:63-66.
 8. Duh QY. Thyroid cancer in Graves' disease: Incidental versus clinical cancer. *J Surg Oncol* 2004;11:356-357.
 9. Kim WB, Han SM, Kim TY. Ultrasonographic screening for detection of thyroid cancer in patients with Graves' disease. *Clin Endocrinol* 2004;60:719-725.
 10. Ross DS. Predicting thyroid malignancy. *J Clin Endocrinol Metab* 2006;91:256-260.
 11. Belfore A, Garofalo MR. Increased aggressiveness of thyroid cancer in patients with Graves' disease. *J Endocrinol Metab* 1990;70:830-835.
 12. Chao TC, Lin JD, Jeng LB. Thyroid cancer with concurrent hyperthyroidism. *Arch Surg* 1999;34:130-134.
 13. Lee J, Hyun Nam K. Clinicopathologic features and treatment outcomes in differentiated thyroid carcinoma patients with concurrent Graves' disease. *J Korean Med Sci* 2008;23:796-801.
 14. Hales IB, McElduff M, Crummer P. Does Graves' disease or thyrotoxicosis affect the prognosis of thyroid cancer? *J Clin Endocrinol Metab* 1992;75:886-889.
-