

Stereotactic Radiosurgery for Intracranial Tumors: Puerto Rico Experience

David Lozada, MD*; Ricardo H. Brau, MD†

Historically, the treatment for most intracranial pathologies has included medical management, surgery, radiotherapy and recently, stereotactic radiosurgery. Since its introduction, stereotactic radiosurgery has evolved from an investigational concept into a recognized neurosurgical procedure for the management of a wide variety of brain disorders. The goal of this research was to describe the experience in Puerto Rico using this technology and review the efficacy, safety, and role of radiosurgery in the treatment of the most common intracranial tumors treated today. Patients treated from 1999-2009 at Clínicas Las Américas were reviewed and medical literature databases were searched for articles pertaining to stereotactic radiosurgery performed in these intracranial tumor pathologies: meningiomas, gliomas, cerebral metastasis, vestibular schwannomas and pituitary adenomas. Each study was examined to determine the radiosurgical parameters, duration of follow-up review, tumor growth control rate and complications. A total of 50 peer-reviewed studies were examined. Radiosurgery in benign tumors resulted in the control of tumor size in 90% of treated patients. Unfortunately radiosurgery for malignant tumors is not curative, but has been effective in improving survival and quality of life. Although microsurgery remains the primary treatment modality in most cases, stereotactic radiosurgery offers both safe and effective treatment for much intracranial pathologies. Further refinements in the radiosurgical technique will likely lead to improved outcomes and make it a standard of care. [*P R Health Sci J* 2010;3:286-292]

Key words: Stereotactic radiosurgery, Intracranial tumors, Linear accelerator, Gamma Knife Surgery

Stereotactic Radiosurgery (SRS) is a technology that utilizes externally generated ionizing radiation to inactivate or eradicate (a) defined target(s) in the head or spine without the need to make an incision. The target is defined by high-resolution stereotactic imaging. It uses multiple convergent beams aimed to the target. The beams deliver a maximal dose to the target (with precision of approximately 1mm), while minimizing irradiation of the surrounding tissues. All the treatment is performed in a single session. The procedure requires a multidisciplinary team consisting of a neurosurgeon, radiation oncologist and medical physicist. Technologies that are used to perform SRS include linear accelerators, particle beam accelerators and multisource Cobalt 60 units. In order to enhance precision, various devices may incorporate robotics and real time digital imaging (Stereotactic Radiosurgery Task Force AANS/CNS/ASTRO, March 20, 2006).

“Stereotactic radiosurgery” was invented by the Swedish neurosurgeon Lars Leksell in 1951. Since its introduction, stereotactic radiosurgery (SRS) has evolved from an investigational concept into a recognized neurosurgical

procedure for the management of a wide variety of brain disorders. Presently, radiosurgery can be employed either as a definitive or adjuvant treatment modality in the fields of neuro-oncology, cerebrovascular and functional neurosurgery.

The three major sources of radiation used today to perform SRS are the multi-source Cobalt 60 units, linear accelerators and the particle beam accelerators. These machines provide extremely accurate targeting and precise treatment for brain cancers. They are dedicated to treat brain tumors and other cerebral conditions in a one-day treatment. The original system is the Gamma Knife® (GK). Its Clinical efficacy has been well documented, with more than 502,726 cases treated worldwide

*Resident PGY-4, †Chairman and Professor of the Section of Neurological Surgery University of Puerto Rico Medical Sciences Campus, San Juan, Puerto Rico

The authors have no conflict of interest to disclose.

Address correspondence to: Ricardo H. Brau MD, Professor and Chairman, Section of Neurological Surgery University of Puerto Rico Medical Sciences Campus / Section of Neurosurgery PO Box 365067, San Juan, Puerto Rico 00936. Tel: (787) 765-8276 • Email: rhbrau@gmail.com

providing the data for over 2,500 publications in peer-reviewed medical literature. The GKS is ideal for tumors less than 3.5 cm, and functional disorders of the brain.

The linear accelerator based radiosurgery machines are also prevalent throughout the world. One benefit of this technology is its ability to easily treat large tumor volumes (over 3.5 cm) by treating over several sessions. Most linear accelerator based machines are used for general radiotherapy, however with special adapters they can be used for Stereotactic Radiosurgery. Here in Puerto Rico, at “Clínica Las Américas” there is a linear accelerator-based system. The initial radiosurgery system at Clínicas Las Américas installed in 1999 was manufactured by Radionics®. In 2003 this system was changed to a Brain Lab System® that incorporated a multileaf collimator. The linear accelerator systems utilize radiation beams that are redirected in many “arcs” to lessen the adverse effects on healthy tissue. These machines can perform radiosurgery on tumors smaller than 3.5cm with the same precision of a Gamma Knife and for larger tumors it can fractionate treatments over several days.

In contrast to traditional radiosurgery, the CyberKnife® Robotic Radiosurgery System takes advantage of intelligent robotics to enable the effective treatment of tumors anywhere in the body. It utilizes a 6 MV compact linear accelerator mounted on a computer-controlled six-axis robotic manipulator that permits a wide range of beam orientations. To date, an estimated over 80,000 patients have been treated with the CyberKnife® System and currently more than 50 percent of all CyberKnife® procedures in the United States are extra cranial.

The particle/proton beam exists in a handful of centers in the United States. Due to the cost of the particle beam facility, little research is currently available; however, more is expected in the future.

Procedure

At Clínicas Las Américas all radiosurgical procedures are performed on an outpatient basis. The patient is referred to the neurosurgical and radio-oncology clinic, where a detailed history and physical examination is performed. The patients are presented with an in depth review of the treatment options. If radiosurgery is deemed appropriate, the patient is sent to the radiology department where a volumetric MR imaging study is obtained. On the day of treatment a stereotactic head ring is applied after administration of a local anesthetic agent. Subsequently, stereotactic CT scanning is performed. One to three-millimeter thick slices are obtained throughout the entire head. The volumetric MR imaging study obtained is used to generate a “preplan. The stereotactic CT scan and MR images are transferred to the treatment-planning computer. The CT scan and MR images are fused electronically. The preplan is carefully examined and adjusted to generate the actual treatment plan.

The patient is treated accordingly. The head ring is removed on the same day of treatment. After a short observation period, the patient is discharged. If the patient is treated with

fractionated radiosurgery the ring is removed after the last treatment session. Normally the fractions are given in 3 days or less. Close clinical and radiological neuroimaging follow-up examination is arranged at appropriate intervals depending on the entity treated and the condition of the patient.

Applications of Stereotactic Radiosurgery

The most common applications of stereotactic radiosurgery include treatment of intracranial malignant tumors, benign intracranial tumors, intracranial vascular disorders, and functional disorders (Figure 1). SRS is also being developed for treatment of extra cranial sites including lung tumors, liver tumors, and spinal lesions.

From February 17, 1999 to December 31, 2009 seven hundred and sixty nine (769) patients have undergone stereotactic radiosurgery at “Clínicas Las Américas in San Juan, PR” (Table 1). Within the benign intracranial tumors, meningiomas, pituitary adenomas and acoustic neuromas are the most common intracranial pathologies treated by SRS in Puerto Rico (Figure 2). Among these benign tumors, meningiomas are the most predominant. In the category of intracranial malignant tumors, secondary cerebral metastasis and primary malignant glial tumors are the most commonly treated pathologies by SRS (Figure 3). Among these intracranial malignant tumors, secondary cerebral metastases make up the largest volume due to their frequent incidence.

Detailed analysis of different segments of the treated pathological entities at Clínicas Las Américas will be submitted for publication in the near future.

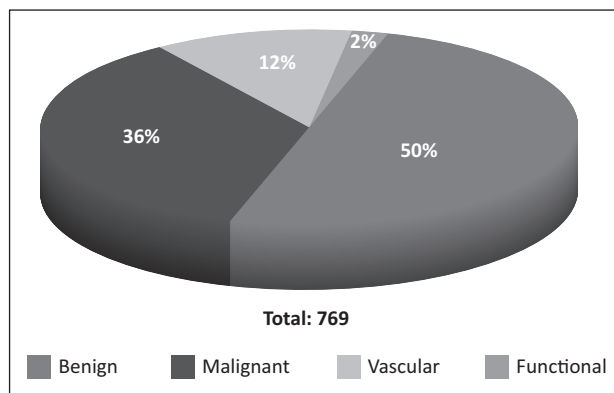


Figure 1. Pie graph depicting the cumulative indications treated with stereotactic radiosurgery in Puerto Rico. Statistics adapted from Clínica las Américas in San Juan, PR (1999-2009).

Methods for Review of the Literature

The radiosurgery databases of Clínicas Las Américas Radiosurgery Group were analyzed to include all the intracranial tumors treated from 1999-2009. The Medline and Pub Med databases were searched for articles pertaining to radiosurgery as a treatment for these common intracranial

Table 1. Cumulative indications treated at Clinicas Las Americas in San Juan, P.R. (1999-2009).

Benign Tumors	
Vestibular Schwanomma	78
Tigeminal Schwanomma	6
Other Schwanomma	5
Gliomas Grade I	6
Meningioma	169
Pituitary Adenoma (Secreting)	25
Pituitary Adenoma (Non-Secreting)	42
Pineal Region Tumor	1
Hemangioblastoma	2
Craniopharyngioma	1
Glomer Tumor	5
Other Benign Tumors	43
Total	383

Malignant Tumors	
Malignant Glial Tumor (II, III, IV)	60
Metastatic Tumor	192
Oligodendriogliomas	5
Hemangiopericytoma	1
Other Malignant Tumors	16
Total	274
Total Tumors	657

Vascular Disorders	
AVM's	91
Cavernous Angioma	3
Total	94

Functional Disorders	
Trigeminal Neuralgia	18
Total	18

Total Indications	
Total Indications	769

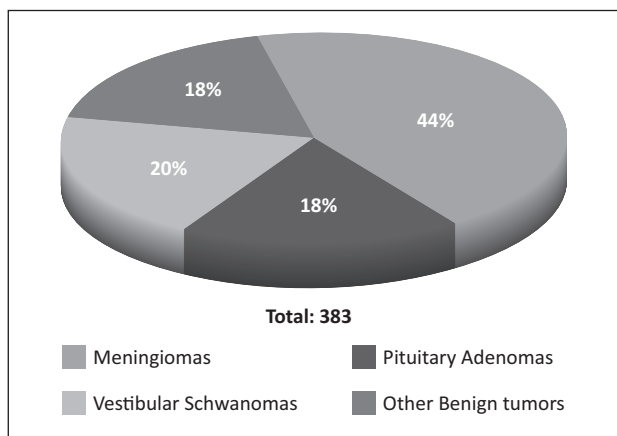


Figure 2. Pie graph depicting the most common intracranial benign tumors treated with stereotactic radiosurgery in Puerto Rico. Statistics adapted from Clínica Las Américas in San Juan, PR (1999-2009).

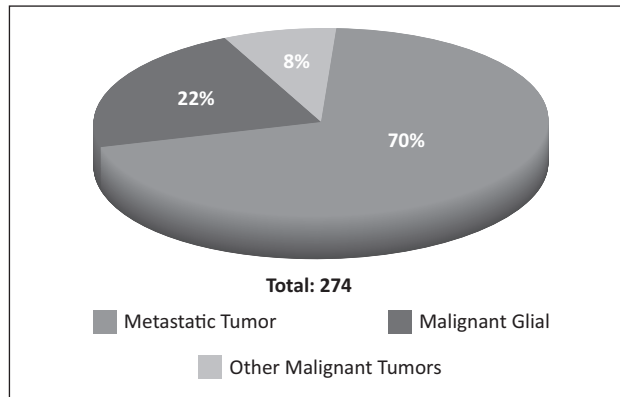


Figure 3. Pie graph depicting the most common intracranial malignant tumors treated with stereotactic radiosurgery in Puerto Rico. Statistics adapted from Clínica Las Américas in San Juan, PR (1999-2009).

pathologies: meningiomas, gliomas, cerebral metastasis, vestibular schwannomas, and pituitary adenomas. Each study reviewed and analyzed has an update of the current indications, limitations, safety and outcomes of this technology. A total of 50 published studies were reviewed.

Benign Intracranial Tumors

Meningiomas

Meningiomas are the most important type of intracranial mesodermal tumors and represent approximately 18% of all primary intracranial tumors. To date over 169 (42% of the benign intracranial tumors) cases have been treated in Puerto Rico. Histologically, the WHO 2007 Classification of Meningiomas recognizes several meningioma subtypes of which nine are considered benign (WHO Grade I).

In the 1990s stereotactic radiosurgery was described for the first time in the treatment of meningiomas I and opened up new ways to treat these tumors. Even though radiation treatment of meningiomas was initially controversial it became more and more accepted after studies provided evidence that radiation could be an effective treatment (1-2).

Surgery, however, is still considered the gold standard (3-4) because it is the most effective way to reduce tumor volume instantly, decompress brain tissue and provide tissue diagnosis. Although surgery of convexity meningiomas usually cures the patient, this is often not possible in the skull base. Depending on the Simpson grade (Table 2) of tumor removal, 5-year recurrence rates are found to be 9% for Grade I, between 19 and 29% for Grade II and III, and 44% for Grade IV tumor resection.^{5,6} The 10- year survival rate reported in the literature was 75% but could be as low as 39% if less than a gross-total resection was achieved.⁷ Because in skull base tumors incomplete removal is described in more than 40% of cases (8-9) radiosurgery plays an important role as a complementary treatment option to achieve a tumor growth stabilization.

Table 2. Table showing the Simpson grading system used for the removal of meningiomas.

Grade	Degree of removal
I	Macroscopically complete removal with excision of dural attachment and abnormal bone (including sinus resection when involved)
II	Macroscopically complete with endothermy coagulation (Bovie, or laser) of dural attachment
III	Macroscopically complete without resection or coagulation of dural attachment or of its extradural extensions (e.g. hyperostotic bone)
IV	Partial removal leaving tumor in situ
V	Simple decompression (\pm biopsy)

In a paper on patients with benign meningiomas, Kondziolka, et al., (10) reported that 91% remained neurologically stable at 5- to 10-year follow-up after radiosurgery. Tumor control rates have ranged from 84 to 100% after either gamma knife surgery or linear accelerator based radiosurgery. Based on a large number of studies (11-18) and a recent study of Guenther CF et al., tumor control with radiosurgery is expected in more than 90% of patients with WHO Grade I and II meningiomas. Radiosurgery is capable of more than just controlling tumor growth. It has been documented that in 82.3% of all tumors treated with radiosurgery achieved a significant reduction in tumor volume.

The best chance to cure patients with meningiomas is to perform a total surgical removal of the tumor and its attachment (11). Microsurgery strives for total tumor resection with preservation of all nervous and vascular structures. Complementary Radiosurgery should be considered to treat any remnant tumor left after surgery. Also can be use as a primary line of treatment if the morbidity and mortality of meningioma resection are considered unacceptable.

Vestibular Schwannomas

Among benign intracranial tumors, Vestibular Schwannomas (VS) has, to date, been the second most frequent target for stereotactic radiosurgery (World Wide Statistics Leksell GK Society 2009). This benign lesion (representing approximately 10% of all primary brain tumors) is a neoplastic proliferation of Schwann cells arising from the myelin sheath of the vestibular branches of the eighth cranial nerve. These tumors are slightly more common in women, present at a mean age of 50 years, and occur bilaterally in patients with Neurofibromatosis type II. In Puerto Rico, 78 cases of acoustic schwannomas (19% of benign intracranial tumors) have been treated at "Clínicas Las Américas" with good results and low complications.

Surgical resection of the tumor is indicated for patients with larger tumors (>3 cm). These tumors can produce major neurological deficits from brainstem or cranial nerve compression. Stereotactic radiosurgery is recommended for

small or medium-sized tumors (<3 cm) with the goals of preserving neurological function, prevention of tumor growth and in many cases a reduction in the tumor volume. Some physicians advocate radiosurgery in patients unwilling or unable to undergo microsurgery, whereas others advocate its use in those with postoperative residual or recurrent tumor. Wallner et al. (19), published that external-beam radiation lowered the postoperative recurrence rate from 46 to 6% in a surgical series at the University of California, San Francisco.

Experience with radiosurgery now extends to over thirty years. Single fraction Radiosurgery has good useful hearing preservation rates (70–71%), but fractionated radiotherapy with LINAC or Cyber knife are providing even better results (74–98% useful hearing preservation) (20-21). Proton Beam did not provide good results for preservation of hearing (33%) (22).

Recently Pollock et al. (23) designed a prospective observational study comparing adult patients with unilateral, unoperated VS less than 3 cm in diameter who underwent surgical resection or radiosurgery. Early outcomes were better for VS patients undergoing stereotactic radiosurgery compared with surgical resection (Level 2 evidence). With the current available results, radiosurgery should be considered the best management strategy for the majority of VS patients.

Pituitary Adenomas

Pituitary adenomas are very common lesions, constituting between 10 and 20% of all primary brain tumors (24-25). Pituitary adenomas are broadly classified into two groups; tumors that secrete excessive amounts of normal pituitary hormones and non-secreting tumors. The most common of the secreting tumors is the prolactinoma. Fortunately, many prolactinomas can usually be managed medically with dopamine agonist drugs. The second most common functioning pituitary adenoma is the Growth Hormone-secreting tumor (producing Acromegaly), followed by tumors that secrete ACTH (Cushing disease).

The second group of pituitary adenomas is composed of tumors that do not secrete any known biologically active pituitary hormones, and these represent approximately 30% of all pituitary tumors (26). Non-functioning pituitary tumors may cause symptoms related to a mass effect, usually compressing the optic chiasm or invading the cavernous sinus. Those patients harboring nonfunctioning adenomas can also have hypopituitarism as a result of compression of the normal functioning pituitary gland. For both types of pituitary adenomas, a recurrent tumor growth resulting from residual tumor invasion into surrounding cavernous sinus or incomplete tumor resection is quite common (27).

Microsurgery is the gold standard for treatment of sellar tumors. It offers the advantages of pathological confirmation, reduction of tumor volume with immediate decompression of the optic apparatus, and rapid reduction of hormone over-secretion. Transsphenoidal resection is currently the

most widely used approach for pituitary adenomas, but the transcranial approach remains a viable alternative for sellar lesions with extensive supra- or parasellar extension. Even in the best of hands, however, microsurgery alone provides long-term tumor control rates of 50 to 80% (28-29).

Stereotactic radiosurgery is typically employed after surgery, but in selected cases may be employed as the primary treatment. It may serve as a primary treatment for those patients deemed unfit for microsurgical tumor removal because they have other comorbidities or demonstrable tumors in a surgically inaccessible location.

Stereotactic radiosurgery has been performed in more 67 (17% of benign tumors treated; 25 secreting and 42 non-secreting) cases in Puerto Rico to control tumor growth and normalize hormone production from pituitary adenomas. At the same time, great attention and effort in the field of stereotactic radiosurgery have been placed on the function preservation of surrounding neuronal, vascular, and hormone producing structures.

In most series tumor control is defined as either an unchanged or decreased volume on follow-up neuroimaging studies. In nearly all published series, stereotactic radiosurgery afforded excellent control of tumor growth (27-35). In these studies, the tumor control rates varied from 83 to 100% (28, 33-39).

More recently, stereotactic radiosurgery has been demonstrated to be a safe and highly effective treatment for patients with recurrent or residual pituitary adenomas (40).

Malignant Intracranial Tumors

Brain Metastasis

Intracranial metastases have been considered ideal targets for radiosurgery and stereotactic radiotherapy due to their small spherical size, frequently non-infiltrative borders, and in many instances located in non-eloquent areas of the brain. Brain metastases incidence is very high, seen in 25% to 30% of all patients with cancer, particularly in those with lung, breast, or colon cancer or melanoma. At Clínica Las Américas, 192 cases of metastatic brain tumors (75% of malignant tumors treated) have been treated.

Whole Brain Radiotherapy (WBRT) has been the standard treatment for brain metastasis. The prognosis, even after treatment with WBRT, is poor, with an average expected survival time of less than 6 months. With WBRT, the dose of irradiation that can be delivered to the tumor is often limited by the tolerance to radiation of the surrounding normal brain tissues. WBRT has been associated with cognitive decline in long-term survivors (41). With radiosurgery the ionizing radiation is mainly delivered to the tumoral volume, although radiation spread to the optic apparatus or the brainstem has to be taken into consideration. Some initial studies suggested that use of radiosurgery for brain metastases should be limited to patients with three or fewer lesions (42). Currently many stereotactic radiosurgery centers commonly exclude patients

with more than five metastases from undergoing radiosurgery (43-44). It has been difficult to define the maximum number of metastases for which the use of stereotactic radiosurgery is advantageous.

Upon reviewing the literature only one randomized trial in patients with brain metastases was found. Aoyama and colleagues reported on a randomized trial of SRS plus whole brain radiation therapy (WBRT) vs. SRS alone for treatment of patients with 1 to 4 brain metastases. They found a 12-month intracranial tumor recurrence rate of 46.8% in the SRS+WBRT group compared to 76.4% in the group that received only SRS. However, median survival times were not different at 7.5 and 8.0 months, respectively. They also found no difference in neurological functional preservation. In an accompanying editorial, Raizer comments that either treatment approach is a reasonable first step recognizing that those who select SRS alone could require subsequent salvage radiation treatments.

Currently radiosurgery is an important treatment modality for patients presenting with metastatic disease to the brain. Complications from radiosurgical intervention are few, and the treatment is well tolerated (45).

Gliomas

Gliomas are a class of tumor that develops from glial (neuroepithelial or support) cells. Astrocytes, ependymal, and oligodendroglial cells are all examples of glial cells that compose the supportive tissue of the brain. Gliomas comprise nearly one-half of primary brain tumors and one-fifth of all primary spinal cord tumors. Contemporary classification of gliomas is based on the World Health Organization (WHO) system, which classifies the tumors according to the cell of origin and histologic features identified by the pathologist. Grade I tumors are circumscribed lesions and may be potentially cured by complete resection. Therefore, these may be considered benign lesions. Grade II lesions are infiltrative lesions that might progress to become malignant, albeit with much slower progression than other more aggressive higher grade lesions. Thus, Grade II lesions are pathologically and clinically distinct from grade I lesions and should be considered potentially malignant. High grade gliomas grow much more quickly, and are assigned either a grade III (anaplastic) or IV (glioblastoma multiforme). Combined, grade III and IV gliomas represent about 40% of all primary brain tumors in patients aged 40-49 years, and 60% in patients older than 60 years. In most clinical series, grade III tumors represent approximately 10-15% of gliomas and grade IV constituting at least 30% of all primary brain tumors and approximately 50% of gliomas.

Malignant gliomas account for approximately 40% of the 17,000 primary brain tumors diagnosed annually in the United States. In Puerto Rico malignant gliomas account for 14% of all the primary brain tumors intervened annually (46). Forty four (44; 17% of malignant tumors) cases have been treated at Clínicas Las Américas, San Juan, PR. Malignant gliomas are one of the

most devastating tumors that can affect any given individual. Grade IV gliomas, or “GBM” have a mean survival time of less than 12 months with the best available treatment (47).

Current conventional treatment for malignant gliomas involves a combination of surgery, radiation, and chemotherapy. The prognosis of these patients remains poor. Historically, patients treated with surgery alone have median survival duration of less than 6 months. The addition of postoperative radiotherapy extended the median survival time to approximately 9 months. Efforts to increase radiation doses to the local tumor region have included new techniques such as radiosurgery (48) and brachytherapy, (49) which have also met with limited success. Kondziolka et al. (50) reported a survival benefit, but could not exclude selection bias as the cause, on 64 patients treated with gamma knife radiosurgery. The only radiosurgery randomized trial for malignant gliomas published, failed to show any benefit for patients with GBM who were treated with radiosurgery.48

At this time radiosurgery is reserved for patients as a salvage procedure in patients with enlarging malignant gliomas in good neurologic status when all other medical and surgical treatments have been employed.

Conclusion

Surgery still remains the gold standard for the treatment of most intracranial tumors. Nevertheless, patients may experience residual tumor or recurrence and therefore adjuvant treatment is recommended for these patients. Radiosurgery may even serve as a primary treatment for those patients deemed unfit for surgical removal because they have significant comorbidities or tumors in a surgically inaccessible location. More recently, stereotactic radiosurgery has been demonstrated to be a safe and highly effective for many of the tumors described previously. Furthermore, the complications rate associated with radiosurgery are low when compared to surgery. The indications for radiosurgery are expanding. With further sophistication of the radiosurgery treatment algorithm better results with fewer complications are expected in the future.

Resumen

La gran mayoría de las patologías intracraneales son tratadas mediante manejo médico, cirugía, radioterapia y recientemente, la radiocirugía estereotáctica. La radiocirugía estereotáctica se ha desarrollado hasta convertirse en un procedimiento neuroquirúrgico reconocido para el manejo de una amplia variedad de desórdenes intracraneales. La meta de este estudio es describir la experiencia en Puerto Rico con esta tecnología y repasar la eficacia, la seguridad y el papel de la radiocirugía en el tratamiento de los tumores intracraneales más comunes. Se revisó la casuística de pacientes tratados en Clínicas Las Américas, el primer centro en Puerto Rico en implementar esta tecnología y

la base de datos de la literatura médica referente a radiocirugía estereotáctica realizada en las patologías intracraneales más comunes. Cada estudio fue examinado para determinar los parámetros radioquirúrgicos, el seguimiento de los pacientes, el control del crecimiento del tumor y las complicaciones. Un total de 50 estudios fueron repasados. En tumores benignos se obtuvo un control del tamaño del tumor en el 90% de los pacientes. Desafortunadamente, para los tumores primarios cerebrales malignos el procedimiento no es curativo, pero ha sido eficaz en mejorar la supervivencia y la calidad de vida. Aunque la microcirugía sigue siendo la modalidad primaria de tratamiento de muchas lesiones intracraneales, la radiocirugía ofrece una alternativa complementaria segura y eficaz. Refinamientos en estas técnicas radioquirúrgicas probablemente conducirán a mejores resultados.

References

1. Mendenhall WM, Morris CG, Amdur RJ, et al.; Radiotherapy alone or after subtotal resection for benign skull base meningiomas. *Cancer* 2003; 98; 1473–1482
2. Pourel N, Auque J, Bracard S, et al.; Efficacy of external fractionated radiation therapy in the treatment of meningiomas: a 20-year experience. *Radiother Oncol* 2001; 61:65–70.
3. Samii M, Ammirati M, Mahrán A, et al.; Surgery of petroclival meningiomas: report of 24 cases. *Neurosurgery* 1989; 24; 12–17.
4. Tatagiba M, Samii M, Matthies C, et al.; Management of petroclival meningiomas: a critical analysis of surgical treatment. *Acta Neurochir Suppl (Wien)* 1996; 65; 92–94.
5. Borovich B, Doron Y; Recurrence of intracranial meningiomas: the role played by regional multicentricity. *J Neurosurg* 1986; 64; 58–63.
6. Borovich B, Doron Y, Braun J, et al.; Recurrence of intracranial meningiomas: the role played by regional multicentricity. Part 2: Clinical and radiological aspects. *J Neurosurg*; 1986; 65; 168–171.
7. Stafford SL, Perry A, Suman VJ, et al.; Primarily resected meningiomas: outcome and prognostic factors in 581 Mayo Clinic patients, 1978 through 1988. *Mayo Clin Proc* 1998; 73; 936–942.
8. Guidetti B, Ciappetta P, Domenicucci M; Tentorial meningiomas: surgical experience with 61 cases and long-term results. *J Neurosurg* 1988; 69; 183–187.
9. Roberti F, Sekhar LN, Kalavakonda C, et al.; Posterior fossa meningiomas: surgical experience in 161 cases. *Surg Neurol* 2001; 56; 8–20.
10. Kondziolka D, Levy EI, Niranjan A, et al.; Long-term outcomes after meningioma radiosurgery: physician and patient perspectives. *J Neurosurg* 1999; 91; 44–50.
11. Roche PH, Regis J, Dufour H, et al.; Gamma knife radiosurgery in the management of cavernous sinus meningiomas. *J Neurosurg (Suppl 3)* 2000; 93; 68–73.
12. Liscak R, Simonova G, Vymazal J, et al.; Gamma knife radiosurgery of meningiomas in the cavernous sinus region. *Acta Neurochir (Wien)* 1999; 141; 473–480.
13. Flickinger JC, Kondziolka D, Maitz AH, et al.; Gamma knife radiosurgery of imaging-diagnosed intracranial meningioma. *Int J Radiat Oncol Biol Phys* 2003; 56; 801–806.
14. Jawahar A, Jawahar LL, Nanda A, et al; Stereotactic radiosurgery using the Leksell Gamma Knife: current trends and future directives. *Front Biosci* 2004; 9; 932–938.
15. Pollock BE, Stafford SL, Link MJ. Gamma knife radiosurgery for skull base meningiomas. *Neurosurg Clin N Am* 2000; 11; 659–666.
16. Aichholzer M, Bertalanffy A, Dietrich W, et al.; Gamma knife radiosurgery of skull base meningiomas. *Acta Neurochir (Wien)* 2000; 142; 647–652.

17. Iwai Y, Yamanaka K, Yasui T, et al.; Gamma knife surgery for skull base meningiomas. The effectiveness of low-dose treatment. *Surg Neurol* 1999; 52; 40–44.
18. Roche PH, Pellet W, Fuentes S, et al.; Gamma knife radiosurgical management of petroclival meningiomas results and indications. *Acta Neurochir (Wien)* 2003; 145; 883–888.
19. Wallner K, Sheline GE, Pitts LH, et al.; Efficacy of irradiation for incompletely excised acoustic neurilemmomas. *J Neurosurg* 1987; 67; 858–863.
20. Combs SE, Volk S, Schulz-Ertner D, et al.; Management of acoustic neuromas with fractionated radiotherapy (FSRT): long-term results with 106 patients treated in a single institution. *Int J Radiat Oncol Biol Phys*. 2005; 63(1); 75–81.
21. Chang SD, Gibbs IC, Sakamoto GT, et al.; Staged stereotactic irradiation for acoustic neuroma. *Neurosurgery* 2005; 56(6); 1254–61.
22. Weber DC, Chan AW, Bussiere MR, et al. Proton beam radiosurgery for vestibular schwannoma: tumor control and cranial nerve toxicity. *Neurosurgery* 2003; 53(3); 577–586.
23. Pollock BE, Driscoll CLW, Foote RL, et al.; Patients outcomes after vestibular schwannoma management: A prospective comparison of microsurgical resection and stereotactic radiosurgery. *Neurosurgery* 2006; 59(1): 77–85.
24. Laws ER, Ebersold MJ, Piepgras DG. The results of transsphenoidal surgery in specific clinical entities, in Laws ER, Randall RV, Kern EB (eds): *Management of Pituitary Adenomas and Related Lesions with Emphasis on Transsphenoidal Microsurgery*. New York: Appleton-Century-Crofts, 1982, 277–305
25. Laws ER, Vance ML, Thapar K: Pituitary surgery for the management of acromegaly. *Horm Res* 2000; 53 (Suppl 3): 71–75.
26. Milker-Zabel S, Debus J, Thilmann C, et al.; Fractionated stereotactically guided radiotherapy and radiosurgery in the treatment of functional and nonfunctional adenomas of the pituitary gland. *Int J Radiat Oncol Biol Phys* 2001; 50(5): 1279–1286.
27. Thapar K, Laws ER Jr: Pituitary tumors, in Kaye AH, Laws ER Jr (eds): *Brain Tumors*, ed 2. London: Churchill Livingstone, 2001, 803–854.
28. Feigl GC, Bonelli CM, Berghold A, et al.; Effects of gamma knife radiosurgery of pituitary adenomas on pituitary function. *J Neurosurg*; 2002; 97 (Suppl 5); 415–421.
29. Lim YL, Leem W, Kim TS, et al.; Four years' experiences in the treatment of pituitary adenomas with gamma knife radiosurgery. *Stereotact Funct Neurosurg* 1998; 70 (Suppl 1); 95–109.
30. Martinez R, Bravo G, Burzaco J, Rey G: Pituitary tumors and gamma knife surgery. Clinical experience with more than two years of follow-up. *Stereotact Funct Neurosurg*; 1998; 70 (Suppl 1); 110–118.
31. Mokry M, Ramschak-Schwarzer S, Simbrunner J, et al.; A six year experience with the postoperative radiosurgical management of pituitary adenomas. *Stereotact Funct Neurosurg* 1999; 72 (Suppl 1); 88–100.
32. Pollock BE, Carpenter PC: Stereotactic radiosurgery as an alternative to fractionated radiotherapy for patients with recurrent or residual nonfunctioning pituitary adenomas. *Neurosurgery* 2003; 53(5): 1086–1091.
33. Sheehan JP, Kondziolka D, Flickinger J, et al.; Radiosurgery for residual or recurrent nonfunctioning pituitary adenoma. *J Neurosurg* ;2002; 97 (Suppl 5): 408–414.
34. Witt TC, Kondziolka D, Flickinger JC, et al.; Gamma knife radiosurgery for pituitary tumors, in Lunsford LD, Kondziolka D, Flickinger JC (eds): *Gamma Knife Brain Surgery. Progress in Neurological Surgery*. Basel: Karger, Vol 14; 1998, 114–127.
35. Yoon SC, Suh TS, Jang HS, et al.; Clinical results of 24 pituitary macroadenomas with linac based stereotactic radiosurgery. *Int J Radiat Oncol Biol Phys* 1998; 41(4): 849–853.
36. Hoybye C, Grenback E, Rahn T, et al.: Adrenocorticotrophic hormone-producing pituitary tumors: 12- to 22-year follow-up after treatment with stereotactic radiosurgery. *Neurosurgery* 2001; 49: 284–292.
37. Kobayashi T, Kida Y, Mori Y: Gamma knife radiosurgery in the treatment of Cushing disease: long-term results. *J Neurosurg* 2002; 97 (Suppl 5): 422–428.
38. Laws ER: *Acromegaly and gigantism*, in Wilkins RH, Rengachary SS (eds): *Neurosurgery*. New York: McGraw-Hill, 1985, 864–867.
39. Thapar K, Laws ER Jr: Pituitary tumors, in Kaye AH, Laws ER Jr (eds): *Brain Tumors*, ed 2. London: Churchill Livingstone; 2001; 803–854.
40. Sheehan JP, Niranjan A, Sheehan JM, et al.; Stereotactic radiosurgery for pituitary adenomas: an intermediate review of its safety, efficacy, and role in the neurosurgical treatment armamentarium. *J Neurosurg*. 2005; 102(4): 678–91.
41. Chang EL, Wefel JS, Hess KR, et al.; Neurocognition in patients with brain metastases treated with radiosurgery or radiosurgery plus whole-brain irradiation: a randomised controlled trial. *Lancet Oncol*. 2009; 10(11): 1037–44.
42. Kondziolka D, Patel A, Lunsford LD et al. Stereotactic radiosurgery plus whole brain radiotherapy versus radiotherapy alone for patients with multiple brain metastases. *Int J Radiat Oncol Biol Phys* 1999; 45(2): 427–34.
43. Weltman E, Salvajoli JV, Brandt RA et al. Radiosurgery for brain metastases: a score index for predicting prognosis. *Int J Radiat Oncol Biol Phys* 2000; 46(5): 1155–61.
44. Yu C, Chen JC, Apuzzo ML et al. Metastatic melanoma to the brain: prognostic factors after gamma knife radiosurgery. *Int J Radiat Oncol Biol Phys* 2002; 52(5): 1277–87
45. Chang EL, Sele U, Hassenbusch SJ III, et al: Outcome variation among "radioresistant" brain metastases treated with stereotactic radiosurgery. *Neurosurgery* 2005; 56: 936–945.
46. Murray G, Jiménez L., Báez F, et al. Descriptive Profile of Surgically-confirmed Adult Central Nervous System Tumors in Puerto Rico. *PRHSJ*. Vol 28 No. 4: 317–28
47. Krex D, Klink B, Hartmann C, et al. Long-term survival with glioblastoma multiforme. *Brain* 2007; 130: 2596–606.
48. Souhami L, Seiferheld W, Brachman D, et al.; Randomized comparison of stereotactic radiourgy followed by conventional radiotherapy with carmustine to conventional radiotherapy with carmustine for patients with glioblastoma multiforme: Report o Radiation Therapy Oncology Group 93-05 protocol. *Int J Radiat Oncol Biol Phys* 2004; 60: 853–860.
49. Sneed PK, Lamborn KR, Larson DA, et al: Demonstration of brachytherapy boost dose-response relationships in glioblastoma multiforme. *Int J Radiat Oncol Biol Phys* 1996; 35: 37–44.
50. Kondziolka D, Flickinger JC, Bissonette DJ, et al.: Survival benefit of stereotactic radiosurgery for patients with malignant glial neoplasm. *Neurosurgery* 1997; 41: 776–785.