



## Cocaine-Induced Myocardial Infarction Associated with Severe Reversible Systolic Dysfunction and Pulmonary Edema

DANIEL ARZOLA-CASTAÑER, MD\*; CHARLES JOHNSON, MD†

Myocardial infarction (MI) associated to cocaine use was originally reported in 1982 and cases are being encountered more frequently in our milieu. The literature regarding this diagnosis has included mostly cases of cocaine associated chest pain and MI without serious sequelae. A lesser number of reports however focus on the clinical presentation of severe myocardial dysfunction and severe pulmonary edema, with the mechanism for pulmonary edema still being debated. Although previously described individually, these manifestations are thought to be an uncommon complication of cocaine ingestion. In this article the

subject is reviewed and we report our experience with two patients that presented to our care with severe pulmonary edema and concomitant severe left ventricular systolic dysfunction that resolved spontaneously with supportive therapy. It is felt that this clinical picture after cocaine use may be more common than expected. In this article we discuss the possible mechanisms associated to this presentation as well as review the literature regarding this subject.

*Key words:* Cocaine induced myocardial infarction, Pulmonary edema, Cocaine ingestion, Myocardial dysfunction.

**M**yocardial infarction (MI) associated to cocaine use was originally reported by Coleman et al, in 1982. Since that time, the literature regarding this subject has been growing, with several mechanisms for the pathogenesis of myocardial damage and resulting dysfunction being proposed. A lesser number of reports, however, focus on the clinical presentation of severe myocardial dysfunction and severe pulmonary edema, with the mechanism for pulmonary edema still being debated. In this article we report our experience with two patients with a severe presentation after cocaine use and discuss the literature regarding this subject.

### Case Reports

*Case 1.* This is a 29 y/o female with a previous history of bronchial asthma, cigarette smoking of one pack per

day for 17 years and HIV infection diagnosed four months prior to admission. She had a previous history of intravenous (IV) heroin and cocaine use for nine years. The patient was taken to the hospital due to shortness of breath, severe sweats, nausea and vomiting with chills of two days evolution. Upon evaluation, chest radiography revealed severe bilateral air space opacification consistent with pulmonary edema. The ECG showed sinus tachycardia and left atrial abnormality without ST segment or T wave abnormalities. Troponin levels were elevated with a urine toxicology positive for cocaine for which a diagnosis of cocaine induced MI was made. The patient was started on aspirin, enoxaparin, diltiazem, diazepam and nitrates. Blood gases revealed severe hypoxemia, which required a non-rebreathing mask. Due to severe hypoxemia, HIV history and character of opacification in the X-ray, she was also given IV antibiotics for possible pneumonia. Two-dimensional echocardiography revealed global hypokinesia, paradoxical septal motion and a global EF of 11%. The patient was transferred to CCU and showed dramatic improvements the next day with marked improvement in oxygenation and decrease in alveolar-arterial gradient (Table 1), as well as improvement of X-ray findings. Three days after admission the patient had completely recuperated with almost complete resolution

From the Department of Medicine, Cardiology Section, Medical Sciences Campus, University of Puerto Rico, School of Medicine. \*Fellow in Cardiology (2001-2004), †Professor of Medicine, Medical Sciences Campus, University of Puerto Rico.

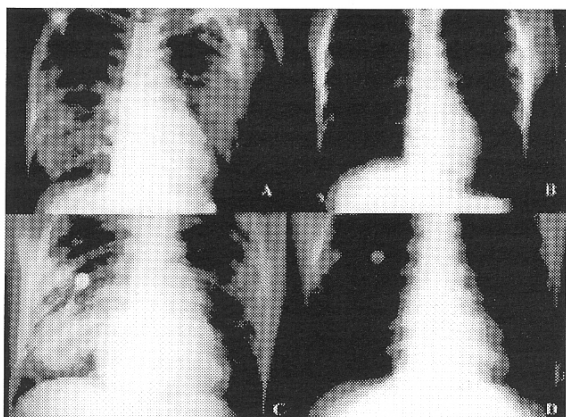
Correspondence address to: Dr. Daniel Arzola-Castañer, Department of Medicine, Cardiology Section, Medical Sciences Campus, University of Puerto Rico, PO Box 365067, San Juan, PR 00936-5067.

of X-ray findings (Figure 1). No diuretics or IV inotropics had been given. Follow-up echocardiogram done seven days after admission showed a global EF of 55% with normal sized chambers (Figure 2). The patient was eventually discharged without further sequelae.

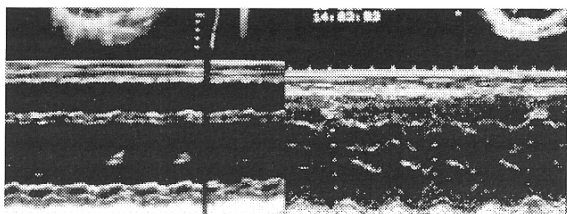
**Table 1.** Serial Arterial Blood Gas Results.

	Case 1		day1	Case 2	
	day 1	day 2		day 2	day 3
pH	7.548	7.506	7.48	7.501	7.543
pO <sub>2</sub> (mmHg)	170	79	109.4	156.8	232.9
FiO <sub>2</sub> (%)	100	21	70	70	50
A-a gradient	507.3	31.8	348.8	312.9	85.2
pO <sub>2</sub> /FiO <sub>2</sub>	170	376	156.3	224.0	465.8
pCO <sub>2</sub> (mmHg)	28.6	31.4	32.7	29.2	30.7
HCO <sub>3</sub>	25.8	26.0	20.6	22.3	25.8

FiO<sub>2</sub> = fraction of inspired oxygen, A-a = alveolar-arterial oxygen gradient, pO<sub>2</sub>/FiO<sub>2</sub> = ratio of arterial oxygen to inspired oxygen.



**Figure 1.** Case 1, Chest X rays on admission (A) and after three days of therapy (B). Case 2, Chest X rays on admission (C) and after four days of therapy (D).



**Figure 2.** M-mode echocardiography views of case 1 demonstrate marked recovery of contractility but persistent paradoxical septal motion.

**Case 2.** This is a 32 y/o male with a previous history of intravenous (IV) cocaine use as well as cigarette smoking, but no history of systemic illness or HIV infection. The patient presented to the ER after being found lethargic in his prison cell, allegedly two days after cocaine use. Upon

arrival the patient was also found hypotensive (84/56 mmHg), in respiratory failure requiring intubation and mechanical ventilation. The initial chest X-ray had severe asymmetric bilateral alveolar opacification without the typical distribution of “cardiogenic” pulmonary edema. It also showed the presence of pneumomediastinum. Troponin and CK-MB levels were elevated with a urine toxicology positive for cocaine, for which a diagnosis of cocaine induced MI was made. The EKG showed sinus tachycardia and no ST segment or T wave changes. A 2D echocardiogram revealed global hypokinesia with left ventricular (LV) cavity dilatation and severe systolic dysfunction with an estimated ejection fraction (EF) of 13%. The patient was initially treated with aspirin, and enoxaparin. No calcium channel blocking agents or nitrates had been started due to hypotension. In fact, patient hypotension persisted despite starting a dopamine infusion and up-titration to 20 µg/kg/min. In view of severe LV dysfunction, pulmonary edema and hypotension a pulmonary artery catheter was placed.

Results of hemodynamic measurements suggested decreased intravascular volume as the cause of hypotension. No diuretics had been given for treatment of pulmonary edema. IV fluids were increased and IV inotropics weaned and discontinued. Serial hemodynamic measurements revealed improvement of blood pressure with increasing wedge pressure (Table 2). Serial blood gas

**Table 2.** Hemodynamic Measurements.

	day 1	Case 2	
		day 2	day 3
CO L/min	4.0	4.8	4.7
CI L/min/m <sup>2</sup>	2.3	2.8	2.7
PCWP mmHg	10	18	18
CVP mmHg	4	13	14
SVR dyne/sec/cm <sup>2</sup>	1938	1448	1309

CO= cardiac output, CI= cardiac index, PCWP= pulmonary capillary wedge pressure, CVP= central venous pressure, SVR= systemic vascular resistance.

samples also showed improvement of oxygenation and gradual resolution of pulmonary edema on X-ray despite IV fluid therapy. The pneumomediastinum also resolved. Patient was finally extubated after 4 days. A follow-up echocardiogram showed normalization of LV size and dramatic improvement in systolic function to normal values (EF 67%). The patient was eventually discharged without further sequelae.

## Discussion

Cocaine-associated myocardial infarction has been described with all routes of ingestion, being inhaled,

intranasal or intravenous. It usually carries a “good” prognosis when compared to the rest of the population with MI and is seldom associated with severe cardiovascular complications. The most common presentation is cocaine associated chest pain. Of these patients it is estimated that 6% reveal a myocardial infarction (1). Patients with infarction are as likely to have abnormal versus normal or non-specific changes in the electrocardiogram (2). On the other hand, the presence of ST segment elevation has been reported in up to 43% of cases without enzymatic evidence of MI(1); therefore the electrocardiogram is not as powerful a discriminator of having sustained an MI in this population. Most of these infarcts do not develop Q waves (3).

Serious cardiovascular complications are relatively uncommon. Ventricular arrhythmias occur in 4-17% and congestive heart failure (CHF) in 5-7%, with fatal cases in less than 2% (3).

Our patients presented with severe LV systolic dysfunction and pulmonary edema. The mechanisms for development of systolic dysfunction in this setting are various, which include acute ischemia or stunning, “catecholamine toxicity” due to sustained sympathetic stimulation and direct effects of the drug or its metabolites causing hypersensitivity reactions or a toxic myocarditis (4). This may present as a dilated cardiomyopathy associated to chronic use or as in our cases, acute and reversible LV dysfunction.

The mechanisms proposed for pulmonary edema are also various. The first reports of fatal pulmonary edema following IV “freebase” cocaine use are from 1981 (5), while non-fatal pulmonary edema after smoking cocaine was reported by Cucco, RA et al. in 1987 (6). Other reports that followed discuss the possibility of acute lung injury or non-cardiogenic pulmonary edema as a result of direct lung toxicity due to adulterants, concomitant opioid use or pulmonary vascular vasoconstriction (6-8). Alveolar hemorrhage has also been reported after IV cocaine use. Animal studies however, proposed that pulmonary edema is a result of hemodynamic changes secondary to increased left atrial pressure due to LV systolic dysfunction or the classic CHF pathophysiology (9). Our patients presented severe pulmonary edema with  $pO_2/FiO_2$  ratios in the acute respiratory distress syndrome range, with a “normal” wedge pressure in case 2. This suggests a non-cardiogenic etiology even in the presence of severe LV systolic dysfunction. This is also supported by the fact that the clinical picture improved even when no diuretics were given, inotropics were discontinued or not used and IV fluid therapy was started to maintain blood pressure. Pneumomediastinum has also been previously reported but thought to be the result of forced inhalation or extreme

Valsalva during inhalation (8), not after the IV route as in case 2. Whether this was related to IV cocaine use or the process of intubation is speculative.

Treatment proposed for patients with acute cocaine induced MI include calcium channel blockers (like verapamil) and IV nitrates to counteract cocaine induced coronary vasoconstriction. Alpha blockers (phentolamine) are considered second line therapy for this purpose. Beta blockers on the other hand should be avoided, specifically propranolol, due to the risk of unopposed  $\alpha$ -adrenergic stimulation. The use of labetalol with both  $\alpha$  and  $\beta$ -blocking properties has been proposed but its usefulness for this purpose has not been established. It has not been demonstrated to counteract cocaine induced coronary vasoconstriction (10). Benzodiazepines are included as first line therapy due to their effect in decreasing heart rate and possible attenuation of cocaine’s local and systemic effects.

Another important mechanism proposed for cocaine induced infarction and myocardial damage is acute thrombosis, both in otherwise angiographically normal arteries or associated to early atherosclerotic disease. Treatment on this level consists initially of aspirin to block cocaine induced platelet aggregation. The use of thrombolytic agents however is more controversial. Although many patients may fulfill electrocardiographic criteria for thrombolytic therapy, and retrospective evaluation of their use has shown overall safety (11), there have been reports of serious complications such as intracranial hemorrhage, even in young patients, and long term benefits of this therapy have not been proven. Coronary angiography and angioplasty have also been performed in these patients with better success (12). The authors of these retrospective studies conclude that thrombolytic agents should therefore be considered after medical therapy has failed and if there is no available invasive facility.

The prognosis for the general population of patients with cocaine induced MI has been reported as “good”, mainly due to the lack of comorbidities in an usually young population and the relatively low incidence of serious cardiovascular complications. This might explain the relatively low number of these patients who get cardiac catheterization or even non-invasive risk stratification after MI. Although a large number of patients have infarction with normal coronary arteries, retrospective studies show that the majority (67%) have at least one vessel significantly involved with greater than 50% stenosis (3). The likelihood of CAD increases with age > 40 yrs., family history, bradyarrhythmias, inferior location of MI and presence of two or more cardiac risk factors (13). Stratification should be guided by the probability of

the patient having coronary artery disease and their long term prognosis. Since long term outcomes are not yet known this is still an area of investigation.

### Conclusions

We present two cases of cocaine induced MI with severe cardiopulmonary compromise that had a good in-hospital outcome. Although the literature refers to this as an uncommon presentation, it is being seen more frequently in our setting. The reversible nature of the acute severe LV systolic dysfunction and pulmonary edema is probably the reason for this short term outcome. The clinical course and hemodynamic data suggest that pulmonary edema results from non-cardiogenic causes despite severely depressed systolic function, either as a direct effect of cocaine or possible concomitant opioid use. The fact that these patients experienced a remarkable recovery with only supportive therapy suggests that conservative initial management may be appropriate but a larger number of patients and further follow-up studies are necessary to evaluate long term prognosis.

### Resumen

El infarto al miocardio asociado al uso de cocaína fue informado originalmente en 1982 y frecuentemente se encuentran más casos en nuestro ambiente. La literatura sobre este diagnóstico ha incluido principalmente casos de dolor de pecho e infarto del miocardio sin serias complicaciones. Un número menor de informes aluden a la presentación clínica de disfunción severa del miocardio y edema pulmonar severo, a la vez que se debate el mecanismo responsable del edema pulmonar. Aunque estos hallazgos habían sido informados individualmente, éstos se consideran una complicación poco común de la ingestión de cocaína. En este artículo se presenta nuestra experiencia con dos pacientes que se presentaron a nuestro cuidado con edema pulmonar severo y disfunción sistólica severa del ventrículo izquierdo, los cuales resolvieron espontáneamente con cuidado de apoyo. Creemos que esta puede ser una complicación más común de lo esperado por lo que en este artículo discutimos los posibles mecanismos asociados a la presentación clínica

en estos pacientes y se revisa la literatura escrita sobre este tema.

### References

1. Lange RA, Hillis LD. Cardiovascular complications of cocaine use. *N Engl J Med* 2001;345:351-8.
2. Hollander JE, Hoffman RS, Burstein JL et al. Prospective multicenter evaluation of cocaine-associated chest pain. *Acad Emerg Med* 1994;1:330-339.
3. Hollander JE, Hoffman RS, Burstein JL et al. Cocaine-associated myocardial infarction. Mortality and complications. Cocaine-Associated Myocardial Infarction Study Group. *Arch Intern Med* 1995; 155:1081-1086.
4. Rump AF, Theisohn M, Klaus W. The pathophysiology of cocaine cardiotoxicity. *Forensic Sci Int* 1995;71:103-115.
5. Allred RJ, Ewer S. Fatal pulmonary edema following IV "freebase" cocaine use. *Ann Emerg Med* 1981;10:441-442.
6. Cucco RA, Yoo OH, Cregler L. et al. Nonfatal pulmonary edema after "freebase" cocaine smoking. *Am Rev Respir Dis* 1987;136:179-181.
7. Efferen L, Palat D, Meisner J. Nonfatal pulmonary edema following cocaine smoking. *NY State J Med* 1989;89:415-6.
8. Hoffman CK, Goodman PC. Pulmonary edema in cocaine smokers. *Radiology* 1989;172:463-465.
9. Lang SA, Maron MB. Hemodynamic basis for cocaine-induced pulmonary edema in dogs. *J Appl Physiol* 1991;71:1166-1170.
10. Pitts WR, Lange RA, Cigarroa JE, et al. Cocaine-induced myocardial ischemia and infarction: pathophysiology, recognition and management. *Prog Cardiovasc Dis* 1997;40:65-76.
11. Hollander JE, Hoffman RS, Burstein JL et al. Cocaine-associated myocardial infarction. Clinical safety of thrombolytic therapy. Cocaine Associated Myocardial Infarction (CAMI) Study Group. *Chest* 1995;107:1237-1241.
12. Sharma AK, Hamwi SM, Garg N et al. Percutaneous interventions in patients with cocaine-associated myocardial infarction: a case series and review. *Catheter Cardiovasc Interv* 2002;56:346-352.
13. Hollander JE, Shih RD, Hoffman RS et al. Predictors of coronary artery disease in patients with cocaine-associated myocardial infarction. *Am J Med* 1997;102:158-163.
14. Kloner RA, Rezkalla SH. Cocaine and the Heart. *N Engl J Med* 2003;348:487-488.
15. Yuen-Green MS, Yen CK, Lim AD et al. Tc-99m sestamibi myocardial imaging at rest for evaluation of cocaine induced myocardial ischemia and infarction. *Clin Nucl Med* 1992;17:923-925.
16. Hoffman RS, Hollander JE. Thrombolytic therapy and cocaine induced myocardial infarction. *Am J Emerg Med* 1996;14:693-695.
17. Hamad A, Khan M. ST-segment elevation in patients with cocaine abuse and chest pain: is there a pattern? *Am J Cardiol* 2001;86:1054.