

Visual Loss associated with Influenza A: a Case Report and Review of Literature

Víctor M. Villegas, MD; Mariola Monagas, MD; Luis Rivera, MD; Carmen Santos MD; Luis Serrano, MD

A 24-year-old female presenting with influenza A pneumonia and simultaneous visual loss was hospitalized. A complete ophthalmological examination was performed three weeks later. Best corrected visual acuity was 20/70 (right eye) and 20/30 (left eye). A dilated fundus exam revealed bilateral vitreous cells and marked bilateral optic nerve swelling with associated peripapillary hemorrhages. A submacular hemorrhage was seen in the right eye. Spinal tap opening pressure was 490 mmHg, with normal cerebrospinal fluid cell counts. Eight months after the initial clinical presentation, the patient was asymptomatic, with normal posterior poles and a best corrected visual acuity of 20/30 in the right eye and 20/25 in the left eye. Although papilledema can produce peripheral retinal hemorrhages secondary to extensive retinal venous congestion, the presence of bilateral vitritis and elevated influenza serum titers suggested that the patient might be suffering from influenza retinopathy. Vitreous polymerase chain reaction could potentially aid in the diagnosis of influenza retinopathy. [*P R Health Sci J* 2012;31:35-37]

Key words: Influenza, Retinitis, Pseudotumor cerebri

Influenza, often referred to as the flu, is caused by an RNA virus of the family Orthomyxoviridae. This family of RNA viruses includes the following five genera: influenza viruses A, B, and C, Isavirus, and Thogotovirus (1). Reports of ocular involvement secondary to influenza virus infection are scarce. We present the case of a young female who developed visual loss during the course of influenza A pneumonia.

Case Report

An obese and hypertensive 24-year-old female developed chills, fever, sore throat, muscle pains, weakness, fatigue, and general discomfort. Two days after the development of symptoms, she was admitted to the intensive care unit because of increasing respiratory difficulty. A chest radiograph showed bilateral interstitial infiltrates. Viral pneumonia was diagnosed and oral oseltamivir phosphate treatment started. Concomitantly the patient complained of visual loss. Influenza A antigen was detected in serum by polymerase chain reaction (PCR). The sample was negative for antigenic particles of influenza B, respiratory syncytial virus A and B, parainfluenza 1/3, rhinovirus, metapneumovirus, and adenovirus. The level of influenza A antibodies in the patient's serum was 32 times higher than normal. The patient was not tested for influenza A subtype H1N1.

Three weeks later, the patient was evaluated by the ophthalmology service because of her persistent visual loss. Bilateral optic nerve swelling was documented. Best-corrected visual acuity was 20/70, right eye (OD), and 20/30, left eye (OS). Intraocular pressure was 16 mmHg in both eyes. Ishihara plates were 14/14 in both eyes. An external eye exam and a slit lamp examination of the anterior segment were normal in both eyes. The pupils were equally round and reactive without relative afferent pupillary defects. A dilated fundus exam revealed vitreous cells and optic nerve swelling, OU, with associated peripapillary hemorrhages (Figures 1 and 2). Retinal hemorrhages were also observed in the peripheries of both eyes. A submacular hemorrhage was seen in the right eye. A diagnosis of papilledema was made. A magnetic resonance imaging study of the orbits was compatible with bilateral optic nerve swelling. The possibility of an influenza-associated retinopathy was considered in view of the history of viral pneumonia with elevated influenza titers.

Department of Ophthalmology, School of Medicine, University of Puerto Rico Medical Sciences Campus, San Juan, Puerto Rico

The authors have no conflict of interest to disclose.

Address correspondence to: Luis Serrano, MD, Department of Ophthalmology, University of Puerto Rico Medical Sciences Campus, PO Box 365067, San Juan, Puerto Rico 00936-5067. Email: luis.serrano7@upr.edu

A neurological evaluation was obtained. The cerebrospinal fluid (CSF) was clear and colorless. Opening pressure was 490 mmHg. White blood cells were undetectable. Total protein was 21 mg/dL and glucose was 51 mg/dL. CSF cultures were negative for bacteria and fungi. A diagnosis of pseudotumor cerebri was made and acetazolamide treatment was started.

Eight months after the initial clinical presentation, the patient was asymptomatic, and best-corrected visual acuity using the Snellen chart was 20/20 OD and 20/25 OS. The posterior segment of both eyes was normal and the fundus showed no signs of optic nerve swelling or retinal hemorrhages.

Discussion

The reported ocular complications resulting from the influenza virus include influenza retinopathy, macular edema, optic neuritis, small intraretinal hemorrhages, color vision deficiency, uveitis, keratitis, ulcerative keratopathy, dacryoadenitis, and sclerotic vasculopathy (3-6). All of these changes appear to be reversible; however, post-influenza retinal pigmentary degeneration can be a complication (3). Herein, we report a case that occurred during the 2009 swine flu pandemic in which the patient developed papilledema and posterior uveitis associated with high serum levels of influenza A virus. Sarcoidosis, multiple sclerosis, lymphomas, and leukemia were considered in the differential diagnosis. These entities, nevertheless, are visible in orbital and chest imaging and do not respond to acetazolamide. Fungi, bacteria, and herpes viruses can also cause a similar clinical presentation, but these entities are usually fulminant in nature. The spatial association

between events and spontaneous improvement without antiviral treatment further suggest influenza A as a likely etiology.

Similar to other cases in the literature, the diagnosis was clinical, with supporting evidence of high serum titers (3-5). Furthermore, this is the first case in which idiopathic intracranial hypertension and concomitant uveitis were associated with influenza A. Although increased intracranial pressure can lead to bilateral optic nerve swelling, it does not cause vitritis. In addition, papilledema can produce peripheral retinal hemorrhaging secondary to extensive retinal venous congestion. However, the presence of bilateral vitreous cells raised the possibility of influenza retinopathy (7).

Severe intracranial hypertension has also been reported in cases of influenza encephalitis (5, 8). Because of the absence of additional neurologic findings and the normal CSF composition, a diagnosis of influenza encephalitis was unlikely.

Medical management in this case consisted of intravenous and oral acetazolamide to decrease CSF production. Decreased intracranial pressure restores axonal flow in the optic nerve head and decreases optic nerve swelling only if it is secondary to increased intracranial pressure. The acute posterior uveitis was not treated because of the self-limiting nature of influenza retinopathy. Other viral conditions such as cytomegalovirus retinitis and herpetic acute retinal necrosis are typically aggressive and unremitting, and resolution results in retinochoroidal pigmentary changes or retinal detachment.

The main limitation of our report is the lack of vitreous viral titers. Intraocular viral titers and polymerase chain reaction would potentially aid in the diagnosis of influenza retinopathy.

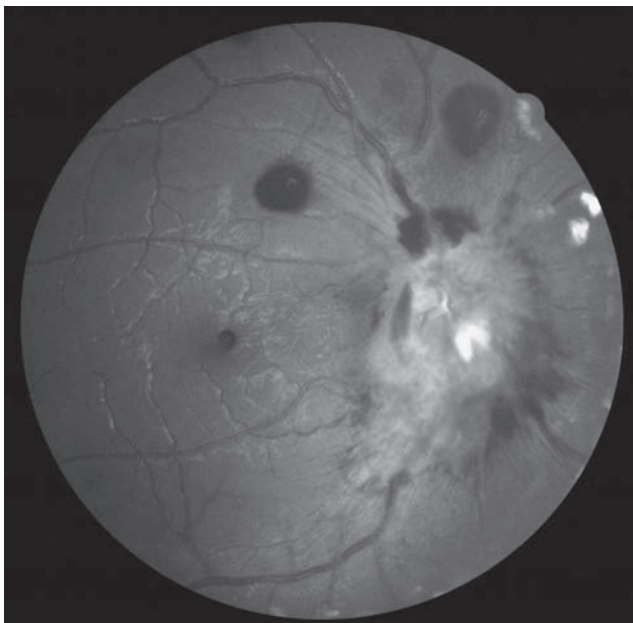


Figure 1. Right-eye fundus photograph.

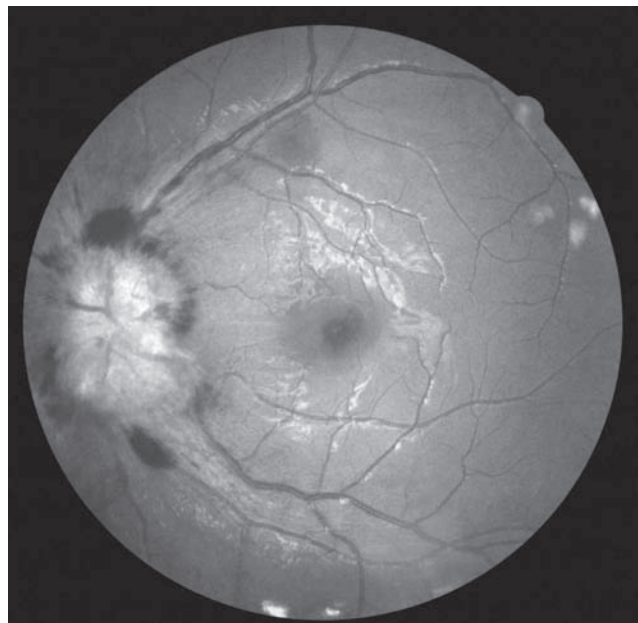


Figure 2. Left-eye fundus photograph.

To the best of our knowledge, this is the first reported case of visual loss associated with the influenza A virus in Puerto Rico. This case adds to the ophthalmic literature because it provides details about a previously unreported association between influenza A, idiopathic intracranial hypertension, and uveitis. The prognosis for this clinical presentation appears to be a good one. Further documentation of the ocular manifestations of the influenza virus will increase our understanding of the pathogenesis of this virus, especially as new strains continue to develop.

Resumen

Una fémina de 24 años de edad fue hospitalizada al presentar simultáneamente pulmonía causada por Influenza A y pérdida de visión. La paciente fue evaluada por un oftalmólogo tres semanas después. La agudeza visual mejor corregida fue 20/70 (ojo derecho) y 20/30 (ojo izquierdo). El fondo de ojo reveló células en vitreo, hinchazón del nervio óptico y hemorragias peripapilares bilateralmente. Hemorragias retinales también fueron observadas en la periferia de ambos ojos. Una hemorragia submacular fue encontrada en el ojo derecho. La presión de apertura de la punción lumbar fue de 490 mmHg con una composición normal de células en el fluido cefalorraquídeo. Ocho meses después de la presentación clínica inicial, el paciente

estaba asintomático, con un fondo de ojo normal y agudeza visual mejor corregida de 20/30 (ojo derecho) y 20/25 (ojo izquierdo). Aunque papiledema puede producir hemorragias retinales periféricas secundario a congestión venosa extensa, la presencia de vitritis bilateral y aumento en títulos de Influenza A en suero son altamente sugestivos de retinopatía por influenza. La reacción en cadena de polimerasa del vitreo pudiera ayudar en el diagnóstico de retinopatía por influenza.

References

1. Jankovics I. The influenza viruses: past, present and future. *Lege Artis Med* 1996;6:62-68.
2. Miller N, Newman N. Walsh & Hoyt's Clinical Neuro-Ophthalmology. Sixth ed., vol. 3 Baltimore, MD: Williams and Wilkins; 2005:3229-3233.
3. Yoser SL, Forster DJ, Rao NA. Systemic viral infections and their retinal and choroidal manifestations. *Surv Ophthalmol* 1993;37:313-352.
4. Weinberg RJ, Nerney JJ. Bilateral sub macular hemorrhages associated with an influenza syndrome. *Ann Ophthalmol* 1983;15:710-712.
5. Fukami S, Wakakura M, Inouye J. Influenza retinitis: association with influenza encephalitis. *Ophthalmologica* 2005;219:119-121.
6. Jo T, Mizota A, Hatano N, Tanaka M. Frosted branch angiitis-like fundus following presumed influenza virus type A infection. *Jpn J Ophthalmol* 2006;50:563-564.
7. Miller N, Newman N. Walsh & Hoyt's Clinical Neuro-Ophthalmology. Sixth ed., vol. 1. Baltimore, MD: Williams and Wilkins; 2005;1:245.
8. Citerio G, Sala F, Patruno A, Gori A, Grioni D, Rossi M, Giussani C, Grimaldi M. Influenza A (H1N1) encephalitis with severe intracranial hypertension. *Minerva Anestesiol* 2010;76:459-462.