

ELECTROCARDIOGRAPHY

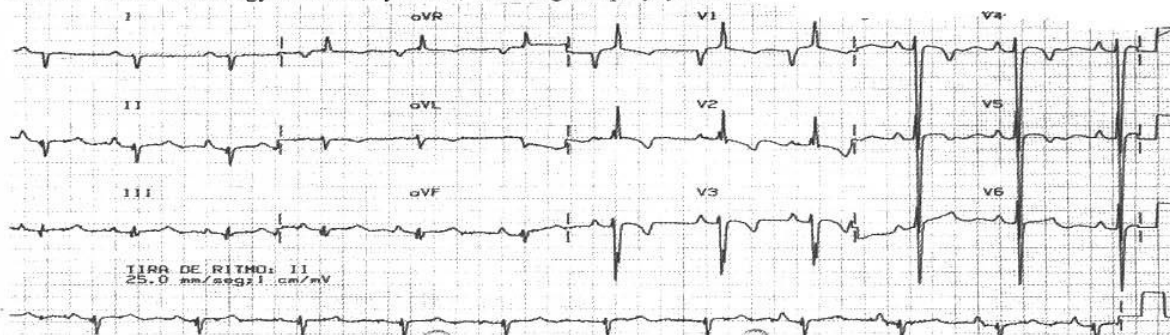
Himalayan P Waves

CHARLES D. JOHNSON, MD, FACC

The term "Himalayan P waves" was first applied by Dr. Helen Taussig of Johns Hopkins Hospital in Baltimore MD, to describe the large tall, peaked, sometimes broad P waves of certain congenital heart defects, such as tricuspid atresia and Ebstein's anomaly (1,2). Such electrocardiograms (ECG) with giant P waves, are a striking, dramatic and helpful diagnostic feature in electrocardiography. Other appellations for these huge P

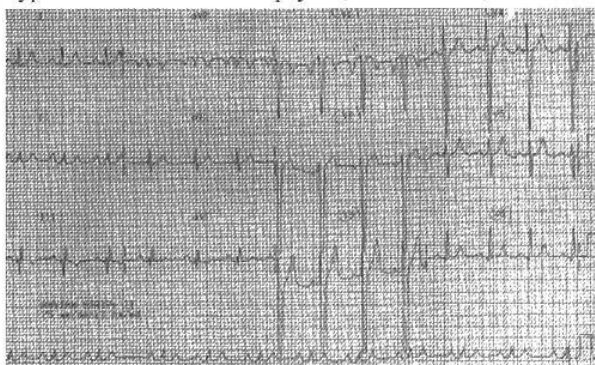
waves are "P congenitale of Zuckermann" (3) and "P tricuspidae of Zuckermann" and Gamboa (4). The P waves in some patients with "P pulmonale" may simulate the large P waves observed in P congenitale. I present several illustrative electrocardiographic cases of giant Himalayan-like P waves. Large P waves of negative deflection will also be included in this general category of Himalayan P waves.

Case 1. 46 M. Pentalogy of Fallot, cyanosis, clubbing and polycythemia.

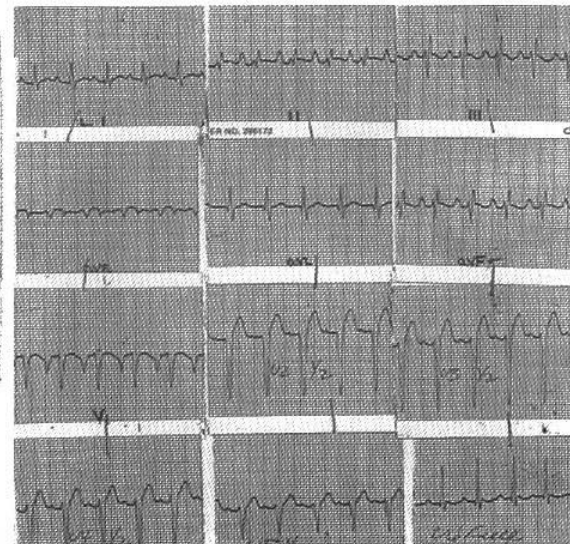


RAE. Right ventricular hypertrophy (RVH) and left ventricular hypertrophy (LVH).

Case 2. 17, 19 M. Single ventricle (SV), pulmonary hypertension, cyanotic spells, congestive heart failure. Severe kyphoscoliosis. Died. Autopsy SV, mitral atresia, LVH.



RAE. "LVH"

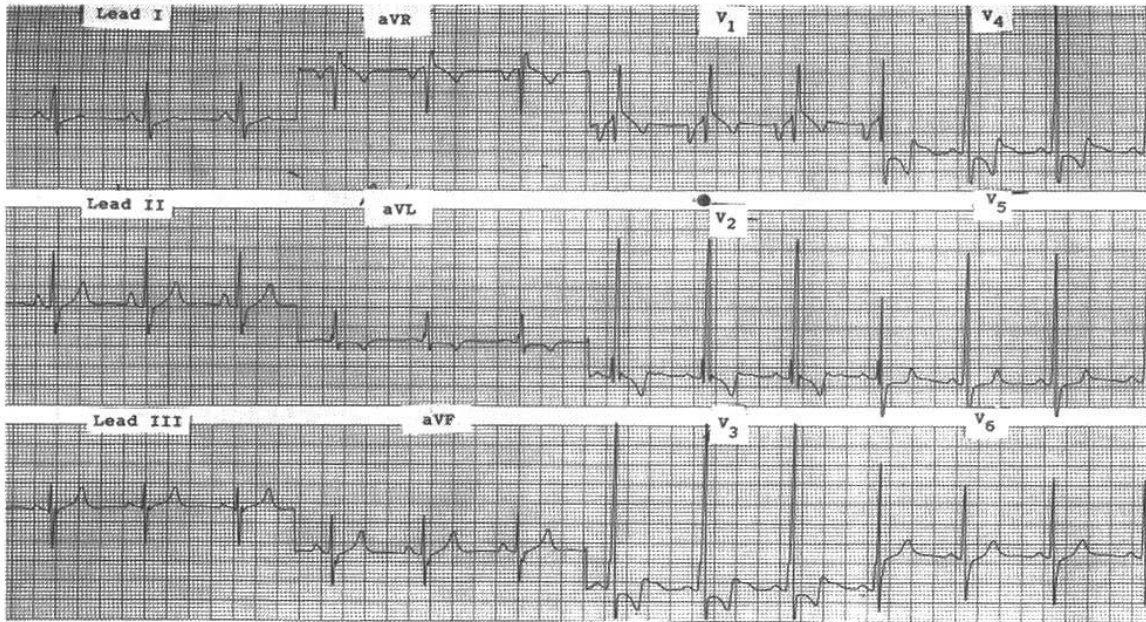


Same. r's complex V₁-V₆

From the Cardiology Section, Department of Medicine, Medical Sciences Campus, University of Puerto Rico

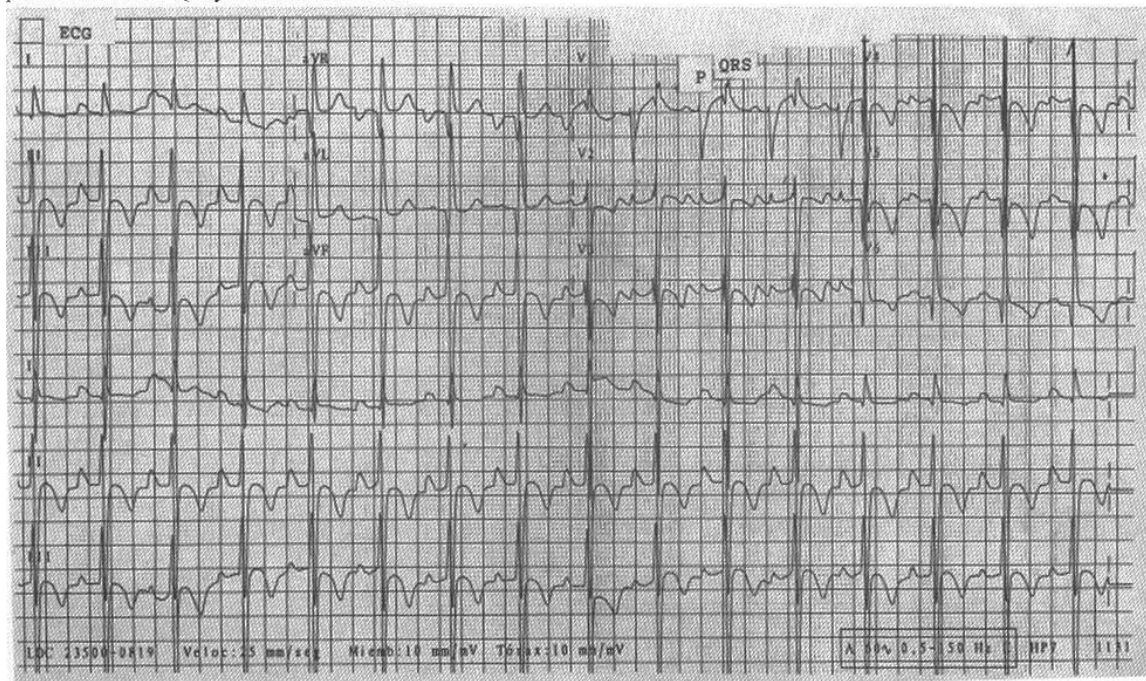
Address correspondence to: Charles D. Johnson, MD, Cardiology Section, Dept. of Medicine, Medical Sciences Campus, University of Puerto Rico, PO Box 365067, San Juan, Puerto Rico 00936-5067

Case 3. 17 M. Tetralogy of Fallot, Peripheral PS. Rubella syndrome. At age 5 years: Blalock-Taussig shunt; age 12 years: Total correction.



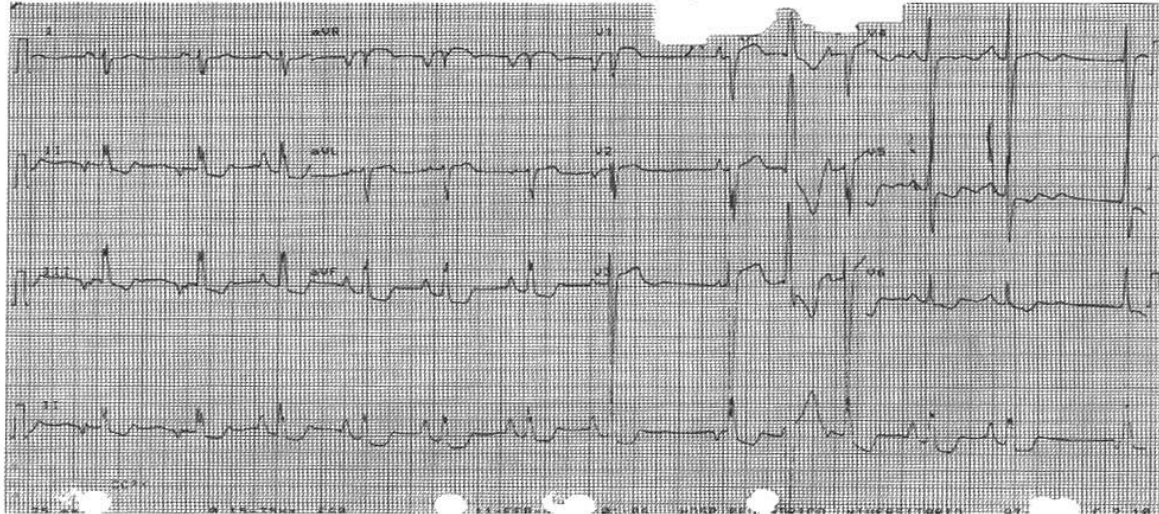
RAE. LAE. RBBB. RVH. LVH.

Case 4. 25 M. Tricuspid atresia. Atrial septal defect (ASD), VSD. Watson, Blalock-Taussig, Glenn and Fontan procedures. Non-Q myocardial infarction.



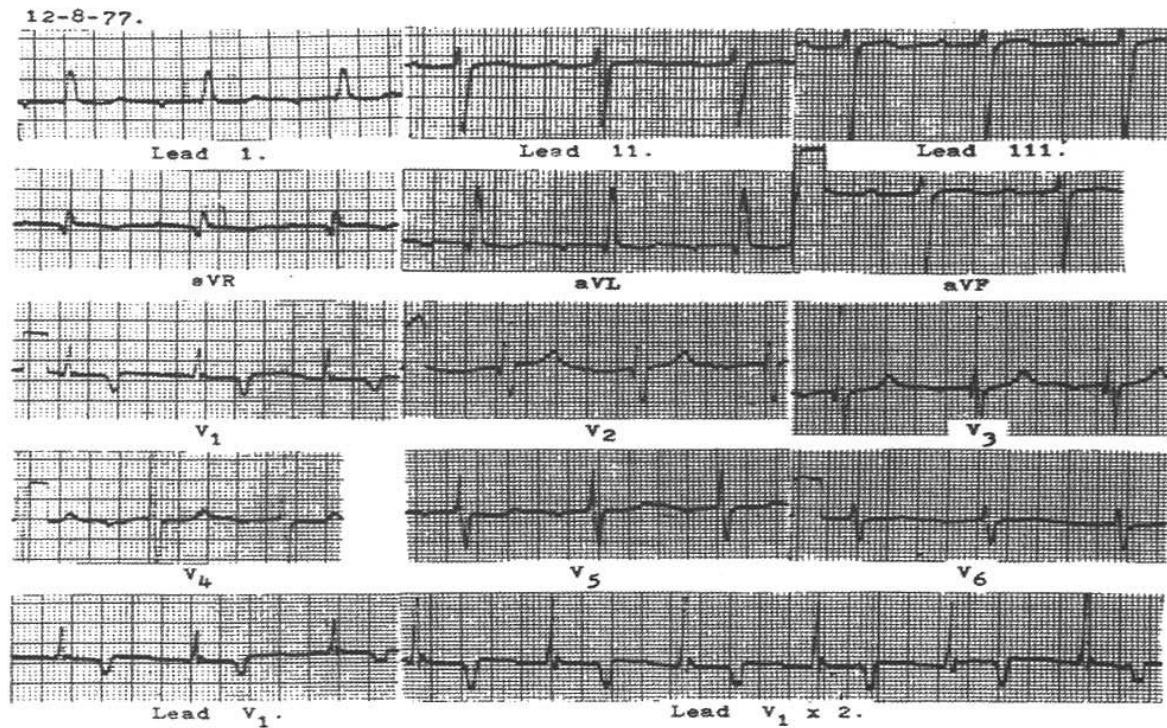
RAE. LAE. Left anterior hemiblock (LAH), type IV. LVH. ST-T wave abnormalities. P wave larger than the QRS complex in lead V₁.

Case 5. 15 M. Double outlet right ventricle, TGA. Severe PS. Large ASD (near single atrium), small right ventricle (RV), large VSD, cleft mitral valve, cyanotic. Blalock-Taussig shunts, Glenn procedure, etc.

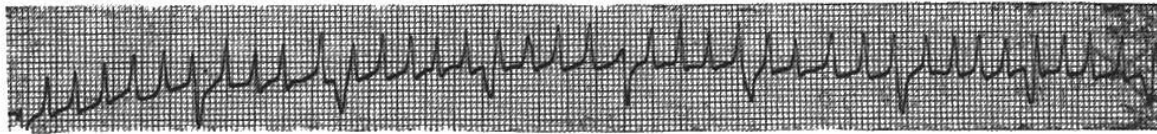


RAE, RVH, LVH. ST-T wave abnormalities. Coronary sinus / high junctional rhythm and sinus rhythm. Coronary sinus escape beats; the eighth beat and the last (dissociated). The ninth beat is an interpolated qR premature ventricular contraction.

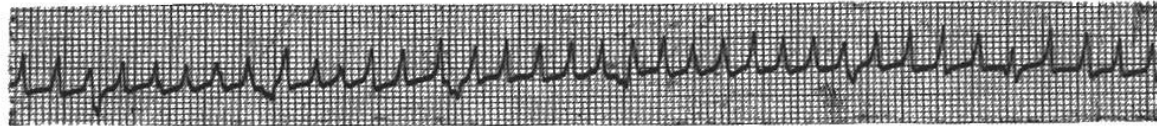
Case 6. 64½ F. Tricuspid atresia (Type 1b). The oldest known case at her death.



Electrocardiogram of the patient at age 59 years. There are tall, spike Himalayan P waves of right atrial enlargement, a rightward P wave vector, marked superior left-axis deviation, first-degree atrioventricular block, incomplete right bundle branch block, and a pseudoanteriorseptal myocardial infarction pattern. The giant tall P waves measure 8 mm in amplitude. (Courtesy of Cardiovascular Reviews and Reports, Reference (6).



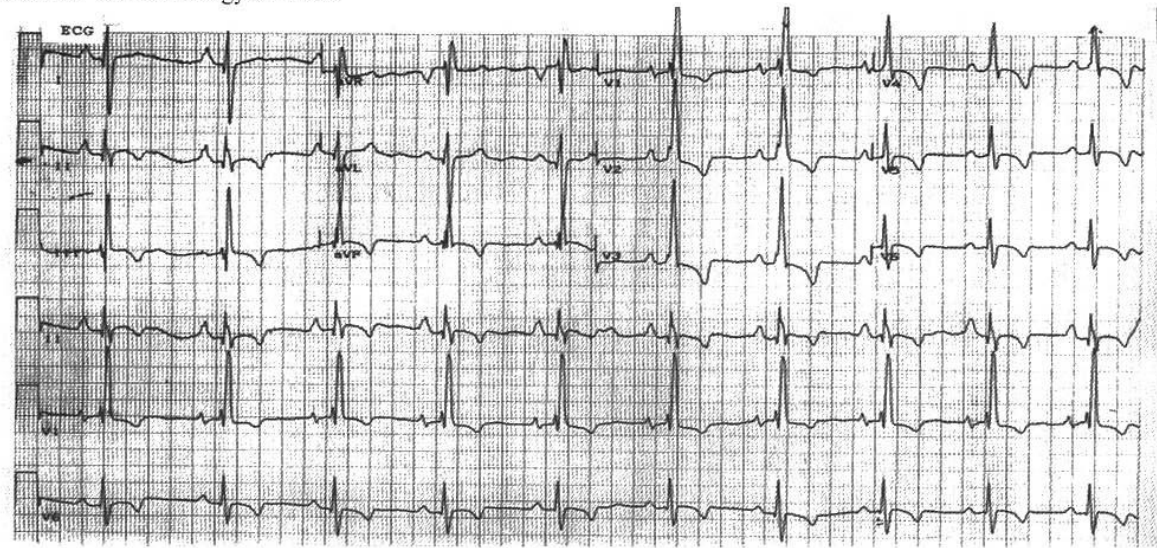
Lead V₁.



Lead V₁

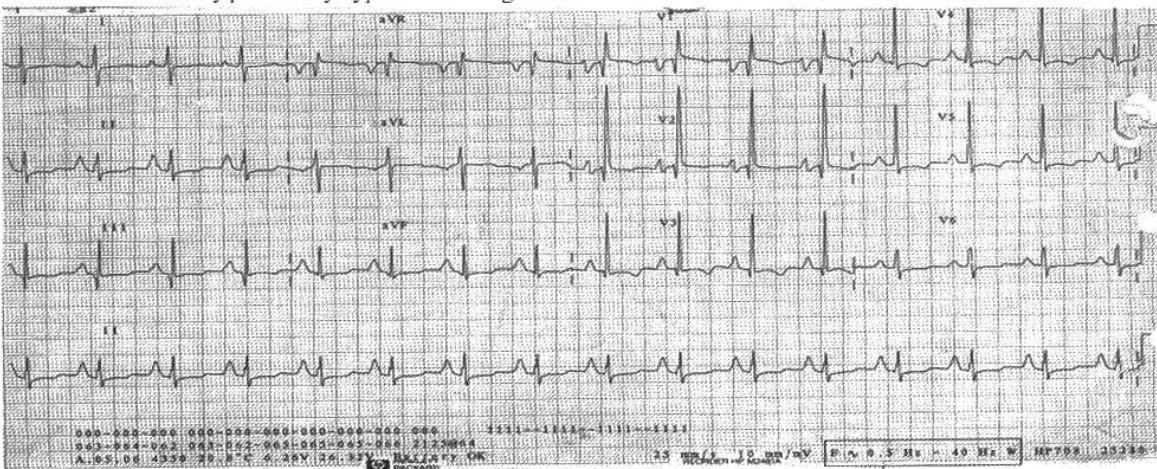
Huge atrial fibrillation (AF) waves (7 mm amplitude), reflecting atrial enlargement (References 5, 6).

Case 7. 36 F. Pentalogy of Fallot.



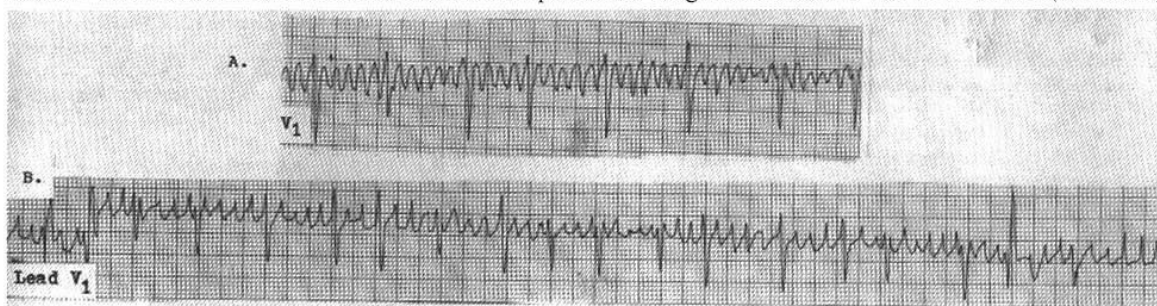
RAE. LAE. RBBB. RVH. PR interval minimally prolonged.

Case 8. 26 F. Primary pulmonary hypertension. Right heart failure.



"Himalayan" P waves, marked RAE. LAE also. RVH. ST-T wave abnormalities. P pulmonale.

Case 9. 28 M. Rheumatic heart disease Mitral valve replacement. Large left atrium. AF. ECG: LAE. LVH (not shown).



Panel A. AF. LAE. Panel B. AF-F waves of different morphology than in panel A. Ashman beats.

Six (6) additional similar cases with large P waves were also observed, but are not included in this report.

Discussion

Giant P waves of marked right atrial enlargement (RAE) are most characteristic of certain congenital heart defects, particularly tricuspid atresia, pulmonary atresia, Ebstein's anomaly of the tricuspid valve, valvular pulmonic stenosis (PS) and anomalous pulmonary venous connection (3, 4, 7, 8). These large tall, positive Himalayan P waves, pointing anteriorly, present typically in leads II, III, aVF, V₁ and V₂. Sometimes they are peaked or pointed and narrow. Their amplitudes may range from 2 to 8 mm. In tricuspid disease the P waves may be tall and notched, with the first peak taller than the second, referred to as "P tricuspidale" (9). Right atrial hypertrophy or overloading may present in lead V₁ as diphasic, tall P waves, which Cabrera described as "a fast intrisicoid deflection between two acuminated vertices" (8).

Other criteria for RAE are: P wave amplitude of 2.5 mm or more in leads II, III, aVF and 1.5 mm in lead V₁; an initial positive component of the P in V₁ of over 0.04 second; a P axis of +75° or more; a qR/QR pattern in lead V₁ reflecting an enlarged right ventricle which is shifted forward changing the direction of the septal vector which points forward and leftward so that lead V₁ faces the tail of the vector and observed frequently in Ebstein's anomaly. Also a small QRS voltage in lead V₁ (<4mm) and an abrupt increase (three fold or more) in the QRS voltage in V₂-attributed to a very dilated right atrium which points toward V₁, and acting as a barrier reduces the QRS voltage in this lead (3, 4, 7-10).

RAE may be accompanied by left atrial enlargement (LAE) in 30% of cases, especially in the presence of increased pulmonary blood flow. A broad, double-peaked P wave of increased duration may reflect both RAE and

LAE-biatrial enlargement. Gamboa et al noted biatrial hypertrophy with P tricuspidale in 81% of their patients with tricuspid atresia (4). However, a wide P wave, positive and then negative in the anterior chest leads can be observed in RAE alone which prolongs the activation time and delays the onset of left atrial activation (4, 9, 10).

Sometimes when the right atrium enlarges sufficiently to extend toward the left across the front of the heart, the P wave of RAE may be inverted in V₁ and thus create the illusion of left atrial enlargement (9). Puech, Martins de Oliveira and Zimmerman described in tricuspid atresia in lead V₁ deep and narrow negative P waves, which returned to the isoelectric line by means of a fast upward segment, and tall positive, peaked P waves in lead V₂-reflecting right atrial overloading. They attributed this to a forward and slight leftward rotation of a very enlarged right atrium, so that the atrial vector points away from V₁. They noted that in left atrial overload the negative phase of the P wave is wide and unaccompanied by a positive atrial wave in V₂, helping to distinguish it from right atrial overload (8).

This mimic presentation of LAE was observed in many of the cases of this report. However, one might consider true LAE in patients who have undergone large aortico-pulmonary shunts, which have resulted in volume overloading and increased flow to the left atrium.

Moreover, coarse atrial fibrillation (AF) and atrial fibrillation F waves measuring more than 1-1.5 mm in amplitude may indicate RAE, LAE or biatrial enlargement (11).

Acknowledgement

Dr. José E. López

References

1. Taussig HB. The clinical and pathological findings in congenital malformations of the heart due to defective

- development of the right ventricle associated with tricuspid atresia or hypoplasia. *Bull J Hopkins Hosp* 1936;59:435-445.
2. Bialostosky D, Horitz S, Espino-Vela J. Ebstein's malformation of the tricuspid valve: a review of 65 cases. *Am J Cardiol* 1972;29:826-836.
 3. Zuckermann R, Guzmán de la Garza C, Cisneros F, Medrano GA. El electrocardiograma en 21 tipos diferentes de cardiopatías congénitas. *Arch Inst Cardiol Mex* 1952;22:550-596.
 4. Gamboa R, Gersony WM, Nadas AS. The electrocardiogram in tricuspid atresia and pulmonary atresia with intact ventricular septum. *Circulation* 1966;34:24-37.
 5. Johnson CD. The electrocardiogram and vectorcardiogram in tricuspid atresia. *P R Health Sci J* 1983;2:49-58.
 6. Johnson CD. Longevity in tricuspid atresia. A case of a 64½ year-old woman. *Cardiovasc Rev and Rep* 1984;5:188-197.
 7. Anselmi G, Muñoz-Armas S, Salazar A, et al. Electrocardiographic patterns of right atrial overloading in some congenital heart conditions. *Am J Cardiol* 1968;21:628-638.
 8. Martins de Oliveira J, Zimmerman HA. Auricular overloadings. Electrocardiographic analysis of 193 cases. *Am J Cardiol* 1959;3:453-471.
 9. Marriott HJL. *Practical electrocardiography*. 8th Ed. Baltimore: Williams and Wilkins, 1988, p.59.
 10. Antoni Bayés de Luna. *Clinical electrocardiography: a textbook*. 2nd Ed. Armonk, NY; Futura Publ. Co., 1998, 55-57.
 11. Thurmann M. Coarse atrial fibrillation in congenital heart disease. *Circulation* 1965;32:290-291.
 12. Reddy SC, Zuberbuhler JR. Himalayan P-waves in a patient with tricuspid atresia. *Circulation* 2003;107:498.
-