

## • CASE REPORT •

# Granulomatous Enterocolitis Secondary to *Yersinia* in an 11-year-old Boy from Puerto Rico, Confirmed by PCR: A Case Report

Fabian J. Rohena, MS-IV; MI Almira-Suárez, MD; Carmen González-Keelan, MD

We report the case of an 11-year-old boy without any history of systemic illness and who developed fever and chills and experienced a 10 lbs. weight loss 3 weeks prior to admission. Two days before admission, he experienced abdominal pain that became localized to the right lower quadrant within 24 hours. A non-enhanced abdominal computed tomography scan revealed a 5 mm, amorphous, hyperdense, right lower quadrant calcification associated with a 9 mm fluid-filled structure. An exploratory laparotomy revealed thickening of the proximal vermiform appendix extending to the cecum, with mesenteric adenopathy. An en-bloc excision of the distal ileum, cecum, mesocolon, and vermiform appendix with an end-to-end ileo-ascending colon anastomosis was performed because of a suspected neoplasm. Pathologic examination of the specimen revealed granulomatous enterocolitis with associated acute suppurative appendicitis and a cecum abscess. Polymerase chain reaction analysis of a paraffin-embedded tissue block confirmed *Yersinia enterocolitica* DNA in the tissue, pointing to *Yersinia* as being the etiologic microbe. To our knowledge, this is the first case of yersiniosis to be reported in Puerto Rico. [*P R Health Sci J* 2014;33:27-30]

*Key words:* *Yersinia enterocolitica*, Cecum abscess, Granulomatous enterocolitis, Mesenteric adenopathy, Puerto Rico

A foodborne pathogen associated with undercooked pork, *Yersinia enterocolitica* is a gram-negative coccobacillus causing appendicitis, ileitis, colitis, and mesenteric lymphadenitis (1). It is one of the most common agents of bacterial enteritis in Europe, with a rising incidence both in Europe and in the United States (USA) (2). Granulomatous enterocolitis and mesenteric lymphadenitis are pathologic findings that must be considered in the differential diagnosis of chronic enteritis, including Crohn's enterocolitis. To our knowledge, we are describing the first confirmed case of *Yersinia enterocolitica* in Puerto Rico (PR).

### Case presentation

An 11-year-old boy with no history of systemic illness developed fever, night chills, and anorexia and experienced a 10 lbs. weight loss that was not accompanied by abdominal pain, nausea, or vomiting. A viral syndrome was diagnosed, and he received oral cefadroxil for 7 days. Symptoms improved for 2 weeks, but he developed generalized abdominal pain not associated with eating or defecation. After 24 hours, the pain became localized in the right lower quadrant (RLQ). A non-enhanced computed tomography scan revealed a 5 mm, suspicious, amorphous, hyperdense, RLQ calcification associated with a 9 mm fluid-filled structure. Acute appendicitis was suspected.

Physical examination revealed an acutely ill, well-nourished boy measuring 137 cm and weighing 47 Kg, with normal vital signs and a temperature of 36°C. A head and neck examination revealed moist oral mucosa and an erythematous pharynx without neck lymphadenopathy. There was no evidence of dehydration. Cardiopulmonary auscultation was normal. The abdomen was distended, and further examination revealed hyperactive bowel sounds, rebound tenderness, and voluntary guarding at the RLQ. No organomegaly was identified upon abdominal palpation. No neurological deficit was identified. Laboratories revealed mild microcytic anemia, indicated by a hemoglobin level of 10.1 g/dL, a mean corpuscular volume of 77fL, a normal platelet count (250,000/ $\mu$ L), and a white blood cell count of 8.8/ $\mu$ L. The comprehensive metabolic panel was unremarkable and the urinalysis was normal. Upon exploratory laparotomy, a proximally thickened appendix with invasion of the cecum and scattered enlarged mesenteric lymph nodes were identified. Suspecting neoplasia, an en-bloc excision of the distal

Department of Pathology, School of Medicine, University of Puerto Rico Medical Sciences Campus, San Juan, Puerto Rico

*The authors have no conflicts of interest to disclose.*

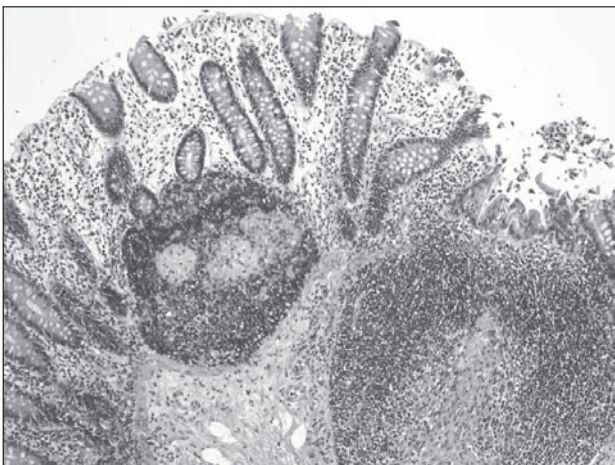
Address correspondence to: Carmen González-Keelan, MD, Department of Pathology, University of Puerto Rico Medical Sciences Campus, PO Box 365067, San Juan, PR 00936-5067. Email: carmen.gonzalez22@upr.edu

ileum, cecum, mesocolon, and appendix, with end-to-end ileo-ascending anastomosis, was performed. The day after surgery, the patient had a temperature of 37.7°C. A 3-day regimen of intravenous (IV) gentamicin (80 mg every 8 hours) and Timentin® (ticarcillin and clavulanate, 3.1 gm every 6 hours) was administered. Oral amoxicillin/clavulanic acid (875 mg/125 mg for 2 weeks) was prescribed when he was discharged home. Upon interviewing his mother 2.5 years later, it was determined that he was doing well, had experienced no clinical sequelae, and had not complained of any of the following: arthritis, arthralgia, erythema nodosum, or any gastrointestinal disorder, including diarrhea, abdominal pain, anal fissures or tags, or rectal bleeding. At that time, the patient was 14 years old, 183 cm tall, and played basketball competitively. Identified risk factors were that the family eats pork and owns a cat.

### Pathologic description

An enterocolectomy including the distal ileum (2.5 cm), the cecum (8 x 3 cm), and dilated vermiform appendix (8 cm long x 1.5 cm wide), containing thick, yellow pus was received. On sectioning, the wall of the cecum was thickened, measuring 0.6 cm. The ileocecal valve was edematous. The bowel mucosa presented normal folds.

Microscopically, the ileum and colon mucosa presented preserved architecture without cryptitis or basal plasmacytosis (Figure 1). The colon presented lymphoid hyperplasia, with multiple non-caseating granulomas replacing germinal centers (Figure 1), transmural lymphocytic inflammation, and an abscess involving the muscularis propria. The ileum Peyer patches were prominent. The vermiform appendix was dilated, with lymphoid hyperplasia and acute periappendicitis. Special stains for acid-fast bacilli and fungi were negative for organisms. The final diagnosis was granulomatous enteritis and lymphadenitis with a cecum abscess and acute appendicitis, consistent with yersiniosis presenting as right iliac fossa syndrome.



**Figure 1.** Normal colon mucosa crypt architecture with non-caseating granulomas replacing lymphoid germinal centers

A paraffin-embedded tissue block was sent to Microbac Laboratories, Inc. (Maryville, TN), where PCR analysis confirmed the presence of *Yersinia enterocolitica* DNA. Microbac Laboratories uses standard 2-primer PCR to detect the presence of *Y. enterocolitica*. Samples are extracted using a modified bead-beating procedure, which includes a pre-extraction step during which the paraffin-embedded sample is incubated at 65°C for 3 to 4 hours in AE buffer to liquefy it. The aqueous layer is allowed to separate and is then removed to a sterile 1.5 ml screw cap tube with glass beads, which are then placed in a bead beater for 30 to 45 sec. to rupture the cell membranes. The sample is further incubated in lysis buffer for 10 minutes, and the DNA is recovered by column filtration using the QIAGEN DNeasy kit. PCR primers and cycling conditions are referenced in Wannet et al., 2001 (3). The primer set Y1 and Y2 was used to perform the PCR reactions. Optimization and analysis were performed on a Stratagene Robocycler 96, and amplicons were resolved using a 1.5% agarose gel stained with ethidium bromide.

### Discussion

First isolated in the USA in 1934 by McIver and described further by Schleifstein in 1939, *Yersinia enterocolitica* is a gram-negative coccobacillus that was not recognized as a human pathogen until the late 1960s, when it was identified in foodborne gastroenteritis (4). In the 1970s, *Y. enterocolitica* spread globally among pigs and is now known to be linked to undercooked pork (5). The incidence of infection and the prevalence of serotypes vary geographically; infections are more common in Europe than in North America and are also linked to the ingestion of raw milk and contaminated water. In developed countries, the incidence of yersiniosis is higher in infants and young children (2). Other possible modes of transmission include contact with sick pets, the transfusion of contaminated blood products, and the preparation of chitterlings (6). In the course of the patient's treatment, it was discovered that the family eats pork and also own a cat, both of which have been linked to the transmission of this infection. Yearly, foodborne infections cause illnesses and thousands of deaths, with most infections going undiagnosed and unreported (4). Recently, *Yersinia* has become a worldwide concern, and foodborne infections have been reported in many countries (2). Although most infections are sporadic and resolve spontaneously, large outbreaks have occurred, and chronic sequelae have been documented (7). Extra-intestinal symptoms, such as pharyngitis, arthralgia, and erythema nodosum, frequently occur and complications, including sterile arthritis, Reiter syndrome, myocarditis, glomerulonephritis, and thyroiditis, have been reported.

Preferentially involving the ileum, right colon, and appendix, *Y. enterocolitica* mimics CD, being histologically similar to it. Both diseases present transmural lymphoid aggregates, skip lesions, and fissuring ulcers. However, yersiniosis is not associated

with chronic mucosal changes as mucosal cobblestoning, thick muscularis mucosae, neural hyperplasia and crypt distortion. Fistulas and anal tags, which are associated with CD are not seen either. Clinically, chronic yersiniosis may manifest as recurrent abdominal pain, diarrhea, and weight loss, also like CD (7). In fact, several studies have identified *Y enterocolitica* DNA in CD specimens and *Yersinia* antibodies in serum from CD patients (7,8,9), raising the possibility that yersiniosis could trigger the development of CD in some patients. Therefore, the presence of *Yersinia* DNA does not exclude CD.

Compared to other enterobacteria, *Yersinia* is slow growing, requiring 10 days for incubation and a special medium for identification (4). However, the organism is not always detected, as occurred in this case. Therefore, molecular techniques, including PCR and mass spectrometry, are often needed for confirmation (10). Another difficulty in diagnosing yersiniosis is the deep localization of the granulomas, which are missed in biopsies and are best identified in resected specimens (11). Currently, the most effective treatment for yersiniosis includes the use of fluoroquinolones and third-generation cephalosporins (4).

In 1989, Elias-Montalvo et al. demonstrated that *Y. enterocolitica* can survive in tropical freshwater in PR (12). They also mentioned 2 stool isolates of *Yersinia* in 2 asymptomatic paraplegic patients at the Veterans Administration Hospital in San Juan, PR.

Taking into consideration the ability of *Yersinia* to survive in the tropical freshwater of PR, the high consumption of pork on the island, and the difficulty of growing and isolating this bacterium as well as the deep-seated granulomas in the tissue biopsies, we believe that it (*Y. enterocolitica*) is being underdiagnosed in PR.

The predominant histological findings in this case were non-caseating granulomas accompanying a cecal abscess. The differential diagnosis of granulomatous enteritis includes *Histoplasma capsulatum*, tuberculosis bacillus (Tb), Hermansky-Pudlak syndrome (HPS), and Crohn's disease (CD). Special stains for acid-fast bacilli and fungi were negative, allowing us to rule-out tb and histoplasmosis as the diagnosis. The patient did not have a platelet dysfunction or albinism, symptoms which would suggest HPS. Since the routine culture did not grow *Y. enterocolitica*, it was only after PCR testing that yersiniosis was confirmed.

In summary, this patient's 3-week clinical presentation, lack of chronic mucosal changes, and chronic gastrointestinal symptoms argue against CD. Moreover, since short stature is a manifestation of pediatric CD, his growth spurt of 35 cm (reaching a height of 183 cm by age 14) is also an argument against a diagnosis of CD, for the time being.

We were unable to find additional information regarding the incidence or prevalence *Y. enterocolitica* in PR, where it so far has not been a reportable disease. Furthermore, we found

no reports of yersiniosis, in spite of pork being a traditional local food. It is our aim to increase awareness of this microbe as a potential cause of enteritis locally and to promote its consideration in the differential diagnosis of granulomatous enteritis and appendicitis.

## Conclusion

To our knowledge, this is the first report of *Yersinia enterocolitica* in PR. We aim to increase awareness of this infection since it is probable that it is underdiagnosed or misdiagnosed. Additional research is needed to determine the incidence and prevalence as well as understand the health implications of *Y. enterocolitica* infections in Puerto Rico.

## Resumen

Describimos el caso de un niño de 11 años sin historial médico de enfermedades sistémicas que desarrolló fiebre, escalofríos y tuvo una pérdida en peso de 10 libras tres semanas antes de su admisión. Dos días previos a la admisión, desarrolló dolor abdominal, que se localizó al cuadrante inferior derecho en 24 horas. La tomografía computarizada reveló una calcificación amorfa, hiperdensa, midiendo 5 mm, asociada a una estructura líquida de 9 mm, localizada en el cuadrante inferior derecho. La laparotomía exploratoria reveló un apéndice engrosado a nivel proximal con invasión al ciego asociado a una adenopatía mesentérica. Se realizó una resección en bloque del íleo distal, ciego, mesocolon y apéndice, seguida de anastomosis entre el íleo restante y el colon ascendente, porque se sospechó neoplasia. El análisis patológico del espécimen demostró una enterocolitis granulomatosa asociada a apendicitis supurativa aguda y absceso en el ciego. La prueba de reacción en cadena de polimerasa en el tejido de parafina confirmó la presencia de DNA de *Yersinia enterocolitica*, implicando así a *Yersinia* como agente etiológico. Hasta donde conocemos, éste es el primer caso a reportarse de yersiniosis en Puerto Rico.

## Acknowledgments

Special thanks go to University of Puerto Rico librarian Margarita Gonzalez for her assistance with the bibliographical research process and to Robert Brooks, Biotechnology Manager/QAD, of Microbac Laboratories, Inc., in Maryville, TN, for his contribution in describing PCR methodology in the detection of *Yersinia*.

## References

1. El Qouqa IA, El Jarou MA, Samaha AS, Al Afifi AS, Al Jarousha AM. *Yersinia enterocolitica* infection among children aged less than 12 years: a case-control study. *Int J Infect Dis* 2011;15:e48-53.

2. Sabina Y, Rahman A, Ray RC, Montet D. Yersinia enterocolitica: Mode of Transmission, Molecular Insights of Virulence, and Pathogenesis of Infection. *J Pathog* 2011;2011:429069.
  3. Wannet WJ, Reessink M, Brunings HA, Maas HM. Detection of Pathogenic Yersinia enterocolitica by a Rapid and Sensitive Duplex PCR Assay. *J Clin Microbiol* 2001;39:4483-6.
  4. Fabrega A, Vila J. Yersinia enterocolitica: pathogenesis, virulence and antimicrobial resistance. *Enferm Infecc Microbiol Clin*. [Research Support, Non-U.S. Gov't]. 2012;30:24-32.
  5. Tauxe RV. Emerging foodborne diseases: an evolving public health challenge. *Emerg Infect Dis*. [Review] 1997;3:425-34.
  6. Lee LA, Gerber AR, Lonsway DR, Smith JD, Carter GP, Puhr ND, et al. Yersinia enterocolitica O:3 infections in infants and children, associated with the household preparation of chitterlings. *N Engl J Med* 1990;322:984-7.
  7. Saebo A, Lassen J. Acute and chronic gastrointestinal manifestations associated with Yersinia enterocolitica infection. A Norwegian 10-year follow-up study on 458 hospitalized patients. *Ann Surg* 1992;215:250-5.
  8. Lamps LW, Madhusudhan KT, Havens JM, Greenson JK, Bronner MP, Chiles MC, et al. Pathogenic Yersinia DNA is detected in bowel and mesenteric lymph nodes from patients with Crohn's disease. *Am J Surg Pathol* 2003;27:220-7.
  9. Leu SB, Shulman SC, Steelman CK, Lamps LW, Bulut OP, Abramowsky CR, et al. Pathogenic Yersinia DNA in Intestinal Specimens of Pediatric Patients with Crohn's Disease. *Fetal Pediatr Pathol* 2013;32:367-70. doi: 10.3109/15513815.2013.768744. Epub 2013 Apr 23.
  10. Rosado FG, Stratton CW, Mosse CA. Clinicopathologic correlation of epidemiologic and histopathologic features of pediatric bacterial lymphadenitis. *Arch Pathol Lab Med* 2011;135:1490-3.
  11. Montgomery E, Voltaggio L. Biopsy interpretation of the gastrointestinal tract mucosa. Volume 1: Non-neoplastic. 2nd ed. Philadelphia, PA; Lippincott Williams & Wilkins (LWW); 2012:126.
  12. Elias-Montalvo EE, Calvo A, Hazen TC. Survival and Distribution of Yersinia-Enterocolitica in a Tropical Rain-Forest Stream. *Curr Microbiol* 1989;18:119-26.
-