

Comprehensive Management of Diffuse Leiomyomatosis in a Patient with Alport Syndrome

Roberto Burgos, MD*; Eduardo Muñiz, MD*; Edgardo Rivera Rosa, MD*;
Carlos J. Olivares, BS*; Josefina Romaguera, MD, MPH*†

Alport syndrome with diffuse leiomyomatosis (ASDL) is a complex combination that doesn't have a specific course of treatment. In this case report, we present a 44-year-old woman with ASDL and detail her treatment. The patient presented at the emergency room (ER) with symptoms of anemia, bronchial asthma, and abnormal uterine bleeding (AUB). The patient had diffuse myomas in different areas of her body, including the esophagus and genital tract. She was treated by a multidisciplinary team that included members from the hematology/oncology, pulmonary, interventional radiology, anesthesia, surgery, and gynecology services. A physician from interventional radiology performed an embolization of the uterine arteries to treat the patient's AUB. Surgery was done in May 2011 to remove the esophageal leiomyomas to improve her pulmonary function. Surgery included a distal esophagectomy, a proximal gastrostomy, and the resection of the leiomyomatous mass. In order to shrink the tumor in her genito pelvic region so that it could be extirpated with the highest likelihood of success, the patient was treated with gonadotropin-releasing hormone agonist (leuprolide acetate, 3.75 mg/month for 4 months). In May 2012, the patient had a total abdominal hysterectomy (TAH), with a bilateral salpingo-oophorectomy (BSO), the excision of a leiomyoma, and a posterior colporrhaphy. [*P R Health Sci J* 2013;4:200-202]

Key words: ASDL, GnRH agonist

Alport syndrome (AS) is an inherited disorder that can affect the kidneys, eyes, and ears. Rarely AS is seen in combination with diffuse leiomyomatosis (DL), which is a tumorous process involving smooth muscle cells, mostly of the esophagus, tracheobronchial tree, and female genital tract. Patients with AS, have deletions in the COL4A5 and COL4A6 genes that result in the removal of the 5'-ends of these genes (1). Alport syndrome is caused by defects in the genes encoding the alpha-3, alpha-4, or alpha-5 chains of the type-IV collagen of the basement membranes. The estimated gene frequency ratio of Alport syndrome is 1:5000; AS is genetically heterogeneous. Three genetic forms of Alport syndrome exist: XLAS, which results from mutations in the COL4A5 gene (85% of cases); ARAS, which is caused by mutations in either the COL4A3 or COL4A4 gene (10-15% of cases); and ADAS, which also is caused by mutations in COL4A3 or COL4A4 and accounts for the remainder of the cases (2,3). We report on a 44-year-old female patient with Alport syndrome and diffuse leiomyomatosis (ASDL) who was treated by a multidisciplinary team of specialists.

Case history and report

Our patient, G7P4A3, is a 44-year-old woman who was diagnosed with ASDL at age 25 (her symptoms were not

then considered serious enough to warrant immediate action) following the birth of her third child. In a 2010 visit, she was evaluated for abnormal uterine bleeding (AUB) and was diagnosed with a myomatous uterus and genital leiomyomatosis. She presented with symptoms of anemia and bronchial asthma and had a palpable and painful abdominal mass below the umbilicus. A genital exam revealed clitoral hypertrophy, leiomyomas involving the right labia minora and in the lateral vaginal walls, a normal cervix, an irregular and movable uterus (up to 14cm), and a rectal prolapse.

A workup revealed normal biochemical parameters and symptomatic iron-deficiency anemia (6.7g/dL hemoglobin), later treated with blood transfusion (4 units of packed red blood cells). A thorax CT revealed diffuse esophageal dilatation with intraluminal debris a large mass around the esophagus, and a gastro-esophageal hernia. A trans-vaginal ultrasound revealed an enlarged lobulated uterus; a subcutaneous myoma extended

*Department of Obstetrics and Gynecology, San Juan City Hospital, San Juan, Puerto Rico; †Department of Obstetrics and Gynecology, School of Medicine, University of Puerto Rico Medical Sciences Campus, San Juan, Puerto Rico

The authors have no conflicts of interest to disclose.

Address correspondence to: Josefina Romaguera, MD, MPH, University of Puerto Rico Medical Sciences Campus, PO Box 365067, San Juan, PR 00936-5067. Email: josefina.romaguera@upr.edu

to the right labia majora with inferior circumferential perirectal and perianal extension. A pelvic MRI showed an anteverted, enlarged, myomatous uterus (10.7cm long x 11.6cm AP x 9.6cm) with posterior uterine body, anterior uterine body, and subserosal myomas (5.3cm x 4.5cm x 6.9cm, 3.3cm x 5.2cm x 3.8cm, and 1.6cm x 0.8cm x 1.5cm, respectively). There was an additional complex mass with a cystic component (3.9cm) at the anterior urethra.

The interdisciplinary approach used with this patient led to her being treated with GnRH for 4 months. A pulmonary function test revealed severe obstructive impairment secondary to the esophageal mass's effect. A gastroenterology evaluation revealed the existence of an esophageal hernia and a mass (biopsy revealed leiomyoma). The interventional radiology service embolized the uterine arteries, successfully treating the patient's persistent AUB. A partial esophagectomy (with a leiomyectomy and a partial gastrectomy) was performed successfully in May 2011. Upon discharge and after having already undergone a chest surgery, the patient began GnRH

treatment for the reduction of the genital leiomyoma (a myomectomy was planned for a later date). Mild vaginal bleeding persisted during GnRH therapy, despite the patient having undergone the uterine arteries embolization; her anemia remained asymptomatic. Imaging studies done after the GnRH treatment revealed a still-enlarged lobulated uterus (though with decreased myomas and some calcifications) and lobulated lesions with calcifications arising from the anterior lower vaginal wall (3.5cm x 2.3cm), which gave rise to a right labial leiomyoma. In May 2012, the patient underwent TAH and BSO, including the excision of a vulvar myoma and a posterior colporrhaphy; no complications attended the procedure. The patient's son was diagnosed with ASDL at age 9 and underwent several surgeries, including cataract surgery (4).

Discussion

ASDL is defined as the association of AS with esophageal, gastric, vulvovaginal, and/or bronchial leiomyomatosis. Garcia-Torres and Guarner first identified ASDL in 1983 (5). Since then, clinical reports have been published, though mainly in the pediatric literature. There is no protocol for ASDL. Treatment for our patient was individualized and performed sequentially, taking into consideration her concerns about morbidity associated with genital surgery. The delay in gynecological surgical treatment was due to the potentially fatal pulmonary complications sometimes seen in ASDL. The patient was reluctant to undergo surgery because of the possible complications associated with her clinical findings, especially that which raised the possibility of her requiring a colostomy because of the involvement of the inferior circumferential perirectal and perianal extension. Rectal leiomyomas were therefore not addressed.

To induce tumor regression and render surgery feasible, GnRH was used for 4 months. In most cases leiomyomas are estrogen-receptor positive. The use of GnRH has been described in the literature for intravascular leiomyomatosis with genital involvement (6, 7, 8). This patient's overall treatment was considered successful because of her improved pulmonary function and hemoglobin status and the reduction in tumor size. The TAH and BSO were performed without complications in May 2012. An oophorectomy was done because the probable presence of estrogen receptors in these tumors decreased the

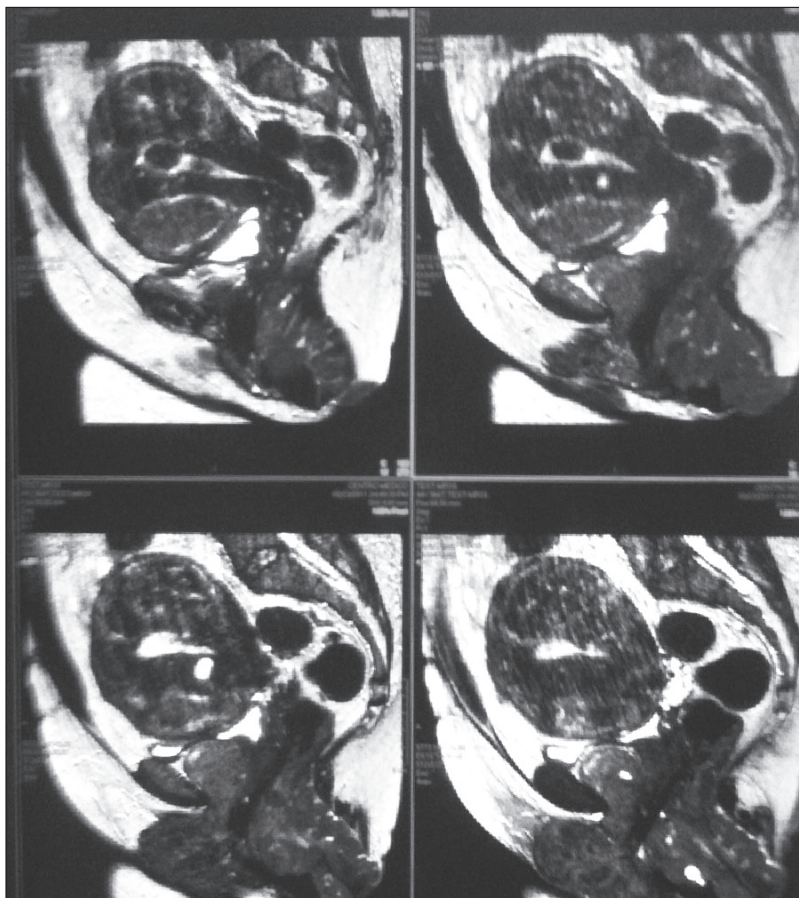


Figure 1. Pelvic MRI reveals an anteverted, enlarged, myomatous uterus (10.7cm long x 11.6cm AP x 9.6cm). Myoma sizes: posterior uterine body, 5.3cm x 4.5cm x 6.9cm; anterior uterine body, 3.3cm x 5.2cm x 3.8cm; and subserosal, 1.6cm x 0.8cm x 1.5cm. Enhancing complex mass associated with the anterior urethra, with a cystic component measuring 3.9cm, possibly secondary to diffuse leiomyomatosis; rectal prolapse.

possibility of tumor recurrence. A recurrence of disease, despite the patient's having undergone a hysterectomy, has been reported (9, 10). Intravascular extension of tumors was not identified. The vulvar leiomyoma was partially resected: This lesion was connected to the rectal myoma, and a complete resection would have increased surgical and postoperative complications. The clitoral enlargement, which remains despite GnRH treatment, was not addressed surgically, in order to decrease genital mutilation and preserve sexual function. The postoperative follow-up was uncomplicated. The patient is stable at present, with adequate sexual function. Although no genetic studies were done on the patient, her son's having the same condition supports the genetic transmission of Alport syndrome. To date, few cases of ASDL have been reported; data concerning its biological behavior, prognosis, and treatment are needed. Using GnRH as an adjuvant to decrease tumor size prior to surgery is a strategy to consider.

Resumen

El síndrome de Alport con leiomiomatosis difusa (ASDL, por sus siglas en inglés) es una combinación compleja que no tiene un tratamiento específico. Esta presentación de caso es de una mujer de 44 años de edad con ASDL y de los detalles de su tratamiento. La paciente acudió a la sala de emergencias con síntomas de anemia, asma bronquial y sangrado uterino anormal (AUB, por sus siglas en inglés). La paciente tenía miomas esparcidos en diferentes áreas del cuerpo, entre estos en el esófago y en el tracto genital. Fue tratada por un equipo multidisciplinario de especialistas que incluía hematólogos/oncólogos, neumólogos, radiólogos intervencionistas, anestesiólogos, cirujanos y ginecólogos. Un radiólogo intervencionista realizó una embolización de la arteria uterina para tratar el AUB del paciente. Se realizó una cirugía en mayo del 2011 para remover el leiomioma esofágico en orden a mejorar la función pulmonar de la paciente. La cirugía incluyó

una esofagectomía distal, gastrostomía proximal y la resección de la masa leiomiomatosa. Para lograr una reducción del tumor de la zona genito pélvica para que fuese extirpada con el mayor éxito posible, la paciente fue tratada con hormona antagonista de gonadotropina (leuprolide 3.75 mg/mensual) por un periodo de 4 meses. En mayo del 2012, se le realizó a la paciente una histerectomía abdominal total con salpingooforectomía bilateral, extirpación del mioma vulvar y colporrafia posterior.

References

1. Anker MC, Arnemann J, Neumann K, Ahrens P, Schmidt H, König R. Alport syndrome with diffuse leiomyomatosis. *Am J Med Genet A* 2003;119A:381-5.
2. Miner JH. Alport syndrome with diffuse leiomyomatosis. When and when not? *Am J Pathol* 1999;154:1633-5.
3. Van Loo A, Vanholder R, Buytaert I, et al. Alport syndrome and diffuse leiomyomatosis with major morbid events presenting at adult stage. *Nephrol Dial Transplant* 1997;12:776-80.
4. Santiago-Caban L, Cruz C, Izquierdo NJ. Cataract in a patient with the Alport syndrome and diffuse Leiomyomatosis. *Rev Bras Oftalmol* 2008;67:309-12.
5. Garcia-Torres R, Cruz D, Orozco L, Heidet L, Gubler MC. Alport syndrome and diffuse leiomyomatosis. Clinical aspects, pathology, molecular biology and extracellular matrix studies. A synthesis. *Nephrologie* 2000;21:9-12.
6. Le Bras A, David A, Knipping M, Mensier A, Heidet L, Lopes P. Diffuse leiomyomatosis with genital involvement and Alport syndrome, report of two cases [in French]. *J Gynecol Obstet Biol Reprod (Paris)* 1998;27:523-8.
7. Lewis EL, Chason RJ, DeCherney AH, Armstrong A, Elkas J, Venkatesan AM. Novel hormone treatment of benign metastasizing leiomyoma: an analysis of five cases and literature review. *Fertil Steril* 2013;99:2017-24.
8. An YS, Kim DY. 18F-fluorodeoxyglucose PET/CT in a patient with esophageal and genital leiomyomatosis. *Korean J Radiol* 2009;10:632-4.
9. Tresukosol D, Kudelka A, Malpica A, Varma D, Edwards C, Kavanagh J. Leuprolide acetate and intravascular leiomyomatosis. *Obstet Gynecol* 1995;86:688-92.
10. Morice P, Chapelier A, Darteville P, Castaigne D, Lhommé C. Late intracaval and intracardiac leiomyomatosis following hysterectomy for benign myomas treated by surgery and GnRH agonist. *Gynecol Oncol* 2001;83:422-3.