

NEUROPATHOLOGY

Desmoplastic Astrocytoma of Infancy: a Case Report With Histopathologic and Immunohistochemistry Profile

EDDA L. RODRIGUEZ-MORALES, MD; MARIA S. CORREARIVAS, MD;
LILLIAN E. COLON CASTILLO, MD.

The clinicopathological features and immunohistochemistry profile of desmoplastic cerebral astrocytoma of infancy are discussed in a 4 month old male infant who presented with an increasing head circumference more pronounced in the last two weeks prior to admission to the University Pediatric Hospital. This is a rare tumor that occurs in infants within the first two years of life and it is characterized by a massive, often cystic, supratentorial lesion usually in the

frontoparietal region. It has a biphasic histologic pattern with an astrocytic and desmoplastic component and a good prognosis after total or near total surgical resection. This patient represents the first case of desmoplastic cerebral astrocytoma of infancy diagnosed in the Puerto Rico Medical Center.

Key words: Desmoplastic astrocytoma, Ganglioglioma, Brain tumors, Classification, Infancy.

Desmoplastic astrocytoma of infancy is a rare tumor that presents as a large hemispheric mass attached to the dura, involving the cortex, and leptomeninges. It was originally described by Taratuto et al in 1982, as meningocerebral astrocytoma attached to dura with desmoplastic reaction, and reported later in 1984 as superficial cerebral astrocytoma attached to the dura (1,2). It was later included in Russel & Rubinstein's classification of astrocytic tumours as desmoplastic cerebral astrocytoma of infancy. It is a rare neoplasm arising in the cerebral hemispheres within the first two years of life, and it is defined by its distinctive clinicopathologic features.

The tumor most distinguishing features include its well-circumscribed cystic structure, biphasic histologic pattern consisting of astrocytes embedded in a desmoplastic stroma, its favorable response to surgical treatment, and

its absence of neuronal differentiation. Despite the huge size these tumors may achieve, cellular pleomorphism, and cellular atypia, prognosis is good, following total or near total surgical resection (3).

In this case we discuss the clinicopathologic features and immunohistochemistry profile of desmoplastic cerebral astrocytoma of infancy that distinguishes it from other similar tumors such as the desmoplastic infantile ganglioglioma, and the fibroproliferative, meningeal, and Schwann cell neoplasms; although in an infant with this clinicopathologic presentation, the latter three are less likely.

Case Report

A 4 months old male infant with unremarkable prenatal history, normal growth and development, was referred to our institution by his private pediatrician due to increased head circumference more pronounced during the last two weeks prior to admission to the University Pediatric Hospital. No other signs or symptoms were reported.

At neurosurgery evaluation, the patient was found with macrocephaly, a bulging and tense anterior fontanel, and sunset eyes. There were no facial asymmetries or any other abnormalities, the cranial nerve function was intact. There was adequate muscle mass and tone and evidence

From the Department of Pathology and Laboratory Medicine, Medical Sciences Campus, University of Puerto Rico, San Juan, Puerto Rico.

The case was presented in a Grand Round at the University Pediatric Hospital.

Address correspondence to: Lillian E. Colón Castillo, Department of Pathology and Laboratory Medicine, Medical Sciences Campus, University of Puerto Rico, San Juan, Puerto Rico. PO Box 365067, San Juan, Puerto Rico 00936-5067.

of involuntary activity was not observed. The patient was active and alert with adequate sensorium, intact deep tendon reflexes, positive Moro reflex, and no clonus. A computerized tomography scan revealed an irregular density with contrast enhancement at the right temporal lobe associated with a large cystic component at the right temporal, frontal, and parietal lobes. There was also a secondary mass effect with obliteration of the right ventricle and shifting of the ventricular system to the left side. A magnetic resonance imaging study (Fig. 1) showed a right cystic panhemispheric mass with a lateral mural nodule causing obliteration of the right lateral ventricle and a subfalcine herniation. A right craniotomy was performed and the mass was totally removed without complications.

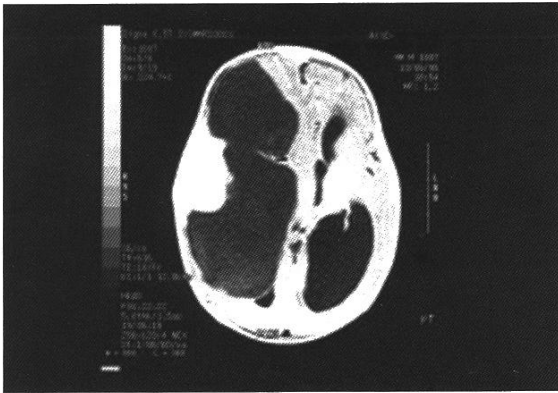

Figure 1. T-1-weighted MR image showing a right cystic mass with temporal mural nodule producing obliteration of the lateral ventricle.

Materials and Methods

The tumor was received in the Anatomic Pathology Division, fixed in formalin and was processed and stained with hematoxylin and eosin stains. The tumoral mass measured 5.1 X 4.4 X 2.0 cm. Externally, it was solid, lobulated and rubbery. On section, it revealed a homogenous gray whorled cut surface. Histologic examination disclosed a neoplasm of astrocytic origin with a biphasic pattern consisting of a prominent desmoplastic stroma and a neuroepithelial component composed of cells with abundant eosinophilic cytoplasm, round to oval nuclei, and mild nuclear pleomorphism (See Figures 2 and 3). Mitotic figures or areas of necrosis were not seen. Immunohistochemical studies were performed using a standard avidin-biotin complex method, and glial fibrillary acidic protein, synaptophysin, neuron specific enolase, placental alkaline phosphatase, and vimentin were applied to the deparaffinized sections (See Table 1).

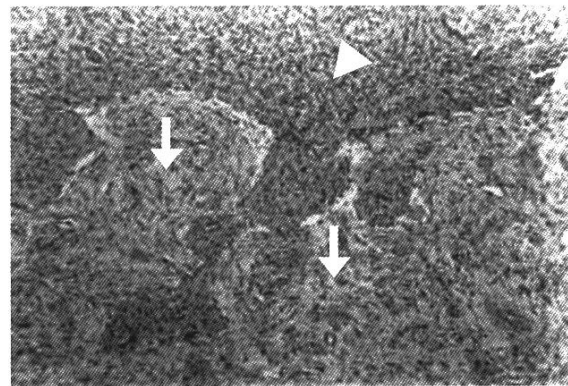


Figure 2. Light microscopic appearance of DCAI. Biphasic pattern. Fascicles of spindle-shaped tumor cells with prominent desmoplasia (arrow) and neuroepithelial component (arrowhead) (H&E 200X).

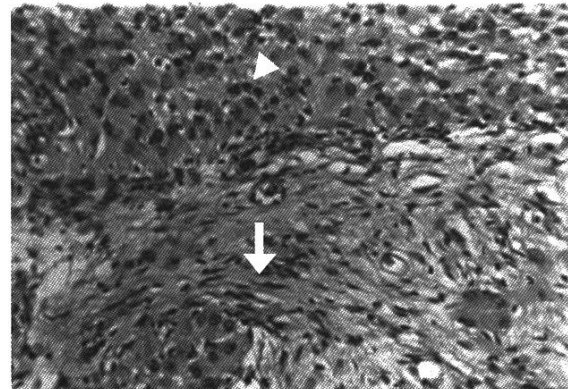


Figure 3. High-power view showing tumor cells with abundant eosinophilic cytoplasm, round to oval nuclei, and mild nuclear pleomorphism (superior) (arrowhead). In the inferior field, elongated spindle cells in a dense fibrous stroma can be seen (arrow) (H&E 400X).

Table 1.

Antibody	Source	Species	Clone	Dilution
GFAP	DAKO	Rabbit	-----	Prediluted
PLAP	DAKO	Monoclonal mouse	8B6	1: 25-1: 50
Vimentin	DAKO	Monoclonal porcine	V9	Prediluted
NSE	DAKO	Monoclonal mouse	BBS/NC/VI-H14	Prediluted
SYN	DAKO	Rabbit	-----	Prediluted

GFAP, glial fibrillary acidic protein; PLAP, placental alkaline phosphatase
NSE, neuron specific enolase; SYN, synaptophysin

Results

Immunohistochemistry showed diffuse intense positivity for glial fibrillary acidic protein (GFAP) confirming the astrocytic origin of the neoplastic cells

(Fig. 4), and positivity for Vimentin highlighting the desmoplastic stroma (Fig. 5). Silver impregnation and immunohistochemistry for neuronal differentiation (NSE, SYN, PLAP) were negative.




Figure 4. GFAP immunostain with cytoplasmic staining in the astrocytic cell population (arrow).

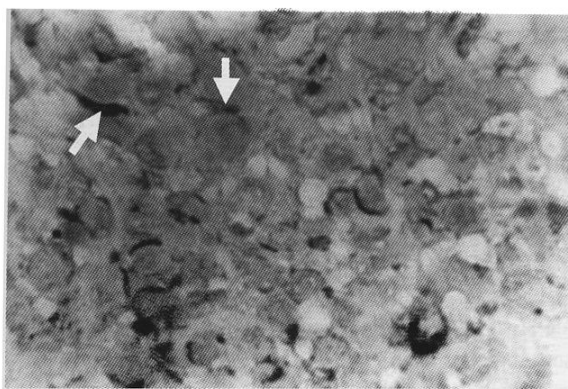


Figure 5. Immunostains for vimentin highlight the spindle cells and desmoplastic stroma from the astrocytic component (arrow).

Discussion

Desmoplastic cerebral astrocytoma of infancy (DCAI) was originally described by Taratuto et al in 1982, as meningocerebral astrocytoma attached to dura with desmoplastic reaction, and reported later in 1984 as superficial cerebral astrocytoma attached to dura (1,2). It was later included in Russel & Rubinstein's classification of astrocytic tumors as desmoplastic cerebral astrocytoma of infancy. It is a rare neoplasm arising in the cerebral hemispheres within the first two years of life, and it is defined by its distinctive clinicopathologic features.

Desmoplastic cerebral astrocytoma of infancy is a massive, often partially cystic lesion involving both the dura mater and cerebral cortex, invariably occurring in a supratentorial location. Involvement of multiple lobes is common with predilection for the frontoparietal lobes. In one series of nine reported cases of DCAI, all patients presented between 1.5-24 months of age, (mean 6.8 months, median 6 months) and a male to female ratio of 0.8:1 (3). The tumor most distinguishing features include its well-circumscribed cystic structure, biphasic histologic pattern consisting of a prominent desmoplastic stroma and a neuroepithelial component consisting of cells with abundant eosinophilic cytoplasm, round to oval nuclei, and mild nuclear pleomorphism. Other features of DCAI include its absence of neuronal differentiation and its favorable response to surgical treatment following total or near total surgical resection despite their huge size, cellular pleomorphism, and cellular atypia (3).

Desmoplastic cerebral astrocytoma of infancy shares a number of clinicopathologic features with the desmoplastic infantile ganglioglioma (DIG), including presentation in infancy, supratentorial cerebral location, and desmoplastic stroma. However, their main histopathological difference resides in the absence of neuronal differentiation in the DCAIs, as its neuroepithelial component is restricted to neoplastic astrocytes, embedded in a dense fibrous stroma, with no mitotic figures or micronecrosis. Besides the absence of neurons or neuronal differentiation, they also lack the presence of more primitive, mitotically active cells. Since their clinical behavior is similarly benign (3), some authors have proposed to use the generic term 'desmoplastic supratentorial neuroepithelial tumors of infancy' for these lesions (4).

The clinicopathologic features and immunohistochemistry profile presented in this case are characteristic of this rare tumor, desmoplastic cerebral astrocytoma of infancy, and similar to those reported in the medical literature (5-6). The immunohistochemistry profile confirmed our morphological diagnosis, and differentiates it from the desmoplastic ganglioglioma of infancy providing precise histological classification.

Resumen

Los hallazgos clinicopatológicos y el perfil inmunohistoquímico del astrocitoma desmoplásico cerebral de la infancia se describen en un infante de 4 meses con aumento en la circunferencia de la cabeza, más pronunciado desde dos semanas antes de su admisión al Hospital Pediátrico Universitario. El astrocitoma desmoplásico cerebral de la infancia es un tumor raro, que

ocurre en los primeros dos años de la infancia y se caracteriza por ser un tumor masivo, usualmente quístico, en una localización supratentorial, de patrón histológico bifásico con un componente astrocítico, otro desmoplásico y una respuesta favorable luego de la resección quirúrgica total o casi total. Este paciente representa el primer caso diagnosticado en el Centro Médico de Puerto Rico desde 1985.

References

1. Taratuto AI, Monges J, Lylyk P, Leiguarda R. Superficial cerebral astrocytoma attached to dura. Report of six cases in infants. *Cancer*, 1984;54:2505-2512.
 2. Taratuto AL, Rorke LB. Desmoplastic cerebral astrocytoma of infancy and desmoplastic ganglioglioma. In: Kleiheus P, Cavenee WK, editors. *Pathology and genetics, tumours of the nervous system*. Lyon (France): IARC Press; 2001.p.70-72.
 3. VandenBerg SR. Desmoplastic infantile ganglioglioma and desmoplastic cerebral astrocytoma of infancy. *Brain Pathol* 1993;3:275-281.
 4. Paulus W, Schlote W, Perentes E, Jacobi G, Warmuth-Metz M, Roggendorf W. Desmoplastic supratentorial neuroepithelial tumors of infancy. *Histopathology*, 1992;21:43-49.
 5. Louis DN, von Deimling A, Dickersin GR, Dooling EC, Seizinger BR. Desmoplastic cerebral astrocytomas of infancy: a histopathologic, immunohistochemical, ultrastructural, and molecular genetic study. *Human Pathol* 1992;23:1402-1409.
 6. Aydin F, Ghatak NR, Salvant J, Muizelaar P. Desmoplastic cerebral astrocytoma of infancy: a case report with immunohistochemical, ultrastructural and proliferation studies. *Acta Neuropathol* 1993;86:666-670.
-