

A Case of Fenofibrate-Induced Immune Thrombocytopenia: First Report

Dimitris I. Agapakis, MD*; Eleni V. Massa, MSc; MD†

Fenofibrate is widely prescribed as a hypolipidemic drug and is well tolerated by most patients. We present the case of a 40-year-old woman who developed severe immune thrombocytopenia while on fenofibrate treatment. Clinical features included spontaneous bruising on the feet and hands, a purpuric rash, and menorrhagia. All the laboratory results were normal except for the finding of isolated thrombocytopenia. The subsequent evolution was favorable after fenofibrate removal and with the administration of immunoglobulin G (IgG) plus corticosteroids. Drug-induced thrombocytopenia is briefly reviewed, and a possible mechanism responsible for causing this side effect of fenofibrate is suggested. This is the first reported case of fenofibrate-induced immune thrombocytopenia. [P R Health Sci J 2015;34: 170-173]

Key words: Drug-induced thrombocytopenia, Fenofibrate, Adverse drug reaction

Drug-induced thrombocytopenia (DITP) is a relatively common complication in clinical practice. It is caused by many agents and may be life-threatening in some cases (1). The identification of the causative drug is not always easy, especially when the patient is taking several medications. Furthermore, a number of severe disorders are associated with thrombocytopenia. In this report, we describe a patient who developed severe thrombocytopenia while on fenofibrate treatment.

Fenofibrate is a drug of the fibrate class. It is a potent lipid-modifying agent that acts by activating peroxisome proliferator-activated receptor α (PPAR α), which last is indicated for the treatment of primary hypertriglyceridemia or mixed dyslipidemia, especially in patients at high cardiovascular risk. Primarily, the drug reduces elevated triglyceride (TRG) levels and increases high-density lipoprotein levels (HDL). Fenofibrate is well tolerated by the majority of patients with dyslipidemia, and its most common adverse effects are gastrointestinal derangement, muscle aches, and back pain (2).

Although there are rare reports of spontaneous thrombocytopenia in subjects treated with fenofibrate, the causative correlation between starting the drug and a resulting decline of platelets has not been established adequately (3).

Case presentation

A 40-year-old woman with consistently elevated TRG levels was examined at the outpatient lipidology clinic of our hospital. In particular, serum TRG was 311 mg/dl and serum HDL was 38 mg/dl, while serum total cholesterol and low density lipoprotein levels were 240 mg/dl and 139.8 mg/dl, respectively. The patient had no significant medical history (no coagulopathy, infections, or other disorders) and was not

taking any prescription medication or “natural” drugs, either at the time of the examination or in the previous several years. In addition, she was neither a smoker nor an alcohol consumer. A physical examination revealed no abnormalities. The common laboratory findings with regard to the serum markers of liver and renal functions were within the normal range (NR). Specifically, the platelet count (PLT) was $277 \times 10^3/\mu\text{l}$ and mean platelet volume (MPV) was 8.1 fL (NR 7–10.5). It was noted that previous routine laboratory testing had revealed a baseline PLT count of $241 \times 10^3/\mu\text{l}$. Additionally, the C-reactive protein (CRP) level was 0.55 mg/dl (NR 0-1); T4 and TSH serum levels were also within NR. The patient’s blood pressure was 130/80 mmHg, and her body mass index was 26.8.

Fenofibrate (200 mg per day) was administered orally to the patient. Three weeks later, spontaneous bruising on the feet and hands as well as a purpuric rash suddenly appeared. Furthermore, the patient was menorrhagic although she was not menstruating, so she was admitted to the hospital.

The patient did not have a fever and, except for the skin lesions and the weakness, the results of the physical examination were unremarkable. The patient did not report any family history of bleeding diathesis; moreover she had never undergone a blood transfusion. The complete blood count revealed isolated thrombocytopenia, as evidenced by a PLT count of $11 \times 10^3/\mu\text{L}$, an increase of MPV to 12.1 fl, a white

*Department of Internal Medicine, General Hospital of Goumenissa, Kilkis, Greece; †General Hospital of Hippokratio, Thessaloniki, Greece

The authors have no conflicts of interest to disclose.

Address correspondence to: Agapakis Dimitrios, MD, Department of Internal Medicine, General Hospital of Goumenissa, Kilkis, Greece, Politechniou str 75, PC 55535, Thessaloniki, Greece. Email: dimagap@yahoo.gr

blood count of $7.3 \times 10^3/\mu\text{L}$ (neutrophils: 62%; lymphocytes: 31%; monocytes: 6.0%; eosinophils: 0.8%; bands: 0.2%), and a hemoglobin level of 10.1 g/dL. The erythrocyte sedimentation rate was 10 mm in the first hour. Coagulation (PT, PTT), liver (SGOT, SGPT, ALP, γ -GT), renal (urea, creatinine), and thyroid values were within NR. The test for hepatitis and tumor markers was negative. The serum CRP level was 0.3 mg/dl. The laboratory profile of disseminated intravascular coagulation was normal (D-dimer: 225 ng/ml-NR:0-500; fibrinogen: 213 mg/dl-NR:190-380). In addition, the measurement of serum autoimmune markers was within NR (RF, ANA, anti-dsDNA, ANCA, and antiphospholipid antibodies). There was no evidence of hemolytic anemia (total bilirubin/LDH, within NR; Coombs test, negative). A urinalysis revealed no abnormalities. A chest x-ray and ECG were both normal. The abdominal ultrasonography did not reveal splenomegaly or hepatomegaly/cirrhosis. The gynecological examination was also normal. The peripheral blood smear confirmed the presence of isolated thrombocytopenia without any other abnormal findings (such as platelet clumping or schistocytes). A bone marrow biopsy and aspiration revealed only a slight increase of megakaryocytes, which were large (normal myelopoiesis and erythropoiesis).

Based on the above findings, DITP was diagnosed and fenofibrate discontinued. Subsequently, the patient was treated with intravenous (iv) immunoglobulin G, 60 g per day for 2 days, and prednisolone (iv, 50 mg/pd for 4 days). After this, the PLT count rose to $65 \times 10^3/\mu\text{L}$, and the bleeding stopped within next 4 days. There was no transfusion of blood or platelets -she received only supplementary ferrum (Fe^{++}) per os to help with her erythropoiesis. The administration of corticosteroids was continued for another 6 weeks, with a gradually decreasing dosage; her PLT count increased to $173 \times 10^3/\mu\text{L}$, 2 months later. To date, the patient's platelet count has remained normal on follow-up evaluations (Figure 1 shows the platelet counts, both after starting and after discontinuing fenofibrate).

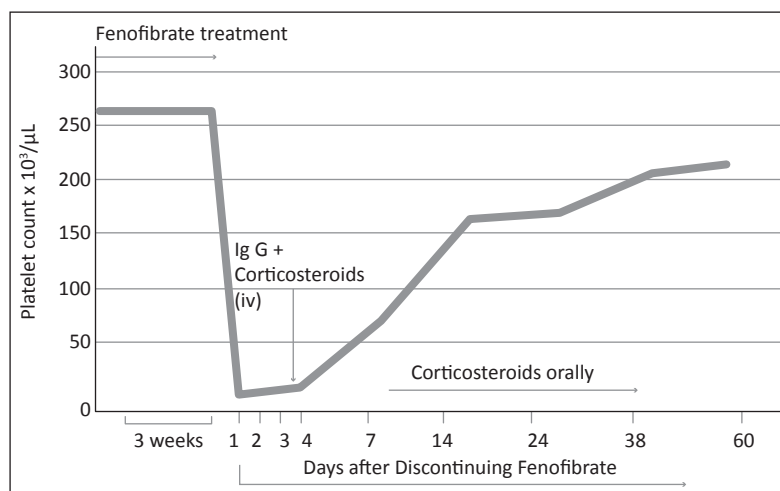


Figure 1. Time course of platelet count-starting and discontinuing fenofibrate

Discussion

Fenofibrate is a widely prescribed hypolipidemic drug that is considered to be safe. However, we herein report on a case of thrombocytopenia that appears to have been induced by fenofibrate use. There exists a clear correlation between the onset and resolution of thrombocytopenia and the period during which fenofibrate was started and discontinued. Our patient had no other conditions associated with thrombocytopenia, such as infection, systemic disease, autoimmune disease, malignancy, or congenital disorders; nor did she have a history of bleeding disorders; fenofibrate was the only medication that she had received. In addition, the peripheral blood smear revealed isolated thrombocytopenia. The above combined with the favorable effect of the discontinuation of treatment with fenofibrate is highly suggestive that the patient's of DITP was caused by this agent.

The estimated annual incidence of DITP is about 10 cases per million persons per year (4). Usually thrombocytopenia occurs at least 1 week after beginning to take whatever drug. Although many of cases of DITP are mild, some are characterized by life-threatening bleeding symptoms (5-6). The severity of bleeding tends to be inversely related to the platelet count (5). Our patient experienced menorrhagia due to thrombocytopenia, 3 weeks after the initiation of fenofibrate treatment. Although the unexpected bleeding was not a life-threatening event-because her hemoglobin level was not very low-it was nevertheless considered to be a severe manifestation of thrombocytopenia.

In general, drug-induced thrombocytopenic disorders can be classified into 3 basic categories: bone marrow suppression, immune-mediated destruction, and platelet aggregation (7).

As for our patient, a bone marrow examination ruled out myelosuppression.

In addition, it is known that fibrates may attenuate platelet activation by inhibiting ADP-induced platelet aggregation (8). Specifically, fenofibrate is able to reduce platelet activation in dyslipidemic patients via the inhibition of the thromboxane A₂ receptor, cytosolic calcium mobilization, and COX-1 activity (9). Thus, thrombocytopenia due to aggregation alone appeared to be unlikely in this patient:

Immune-mediated DITP caused by peripheral platelet destruction is our case.

That assertion is supported by the remarkable increase of MPV levels found in our patient. MPV indicates the average volume of platelets in a blood sample. In general, thrombocytopenia occurring via immune-mediated mechanisms results in an increased MPV, as normal marrow releases younger, larger platelets to keep up with ongoing losses (10).

Immune-mediated DITP is an idiosyncratic reaction which an unusual class of drug-dependent antibodies binds firmly to specific epitopes on

platelet surface glycoproteins. Such an immune-mediated reaction requires the presence of the sensitizing drug (5).

In general, the pathogenesis of immune-mediated DITP is quite complex, and at least 6 different specific mechanisms have been proposed (11). However, determining the exact mechanism in our patient has not been easy.

Thus, the mechanism of immune-complex reaction, in which drug-dependent antibodies (such as in heparin-induced thrombocytopenia), react with platelets via their fragment crystallizable (Fc) domains, could be excluded since the patient had no thrombotic events (12).

Likewise, thrombocytopenia induced by a conformational change in GPIIb/IIIa that is recognized by naturally occurring antibodies (such as is case with glycoprotein IIb/IIIa inhibitors abciximab, eptifibatide, and tirofiban) usually leads to the rapid onset of thrombocytopenia on the first exposure to the drug within hours or a few days; thus, such a mechanism probably can also be excluded in our patient (1, 5).

In our opinion, an obvious explanation may be that the formation of drug-dependent specific antibodies that react with PLTs via their fragment antigen-binding (Fab) domains in the presence of fenofibrate resulted in the gradual destruction of those PLTs over a period of 3 weeks.

The diagnosis of DITP requires that an antibody that reacts with normal platelets in the presence of the responsible drug, which drug the patient has received, be detected. However, such detection is not always technically feasible and also is not useful in acute management; therefore, the decision to discontinue the suspect medication should be made on clinical grounds. In order to accomplish this, George JN et al. proposed clinical criteria for assessing the likelihood that individual drugs are capable of causing DITP, which criteria include the following: 1) Therapy with the candidate drug preceded thrombocytopenia, and recovery from thrombocytopenia was complete and sustained after the therapy with the drug was discontinued; 2) the candidate drug was the only drug used before the onset of thrombocytopenia, or other drugs were continued or reintroduced after the discontinuation of the therapy that featured the candidate drug and upon attaining a sustained normal PLT count; 3) other causes of thrombocytopenia have been ruled out; and 4) re-exposure to the candidate drug resulted in recurrent thrombocytopenia (13). According to the above criteria, the diagnosis of DITP should be considered probable in our patient (criteria 1, 2, and 3 were met).

As for the treatment of DITP, as most drugs are cleared within a few days, PLT levels often start to increase within a day or 2 of hospital admission, so drug discontinuation usually results in a recovery from thrombocytopenia. However, if thrombocytopenia or bleeding symptoms persist for several weeks, treatment with corticosteroids, intravenous IgG, and plasmapheresis may be beneficial (5-6).

This turned out to be the case with our patient: Along with the discontinuation of the drug, intravenous IgG and

prezolon were administered, a treatment strategy that was ultimately successful.

Although fibrates-induced thrombocytopenia affects only a small fraction of patients taking medications of this class (3), this case report reinforces the fact that fibrates may cause thrombocytopenia. Clinicians should avoid overlooking or misdiagnosing DITP. The unexpected occurrence of severe thrombocytopenia should always trigger a suspicion of DITP. What is important in the treatment of DITP is the immediate withdrawal of the drug thought to be responsible for bringing on the condition.

To the best of our knowledge, this is the first case of thrombocytopenia induced by fenofibrate to be described in the literature. No other clinical case report describing this particular illness (which its attendant circumstances) has been published on Medline, so far. Further studies are needed to establish the causality between thrombocytopenia and fenofibrate treatment, as well as the responsible mechanism.

Resumen

El fenofibrato se prescribe ampliamente como fármaco hipolipemiente y es bien tolerado por la mayoría de los pacientes. Presentamos el caso de una mujer de 40 años de edad que desarrolló trombocitopenia inmune severa durante el tratamiento fenofibrato. Las características clínicas incluyen hematomas espontáneos en los pies y las manos, erupción purpúrica y menorragia. Todas las investigaciones de laboratorio fueron normales excepto por el hallazgo de trombocitopenia aislada. La evolución posterior fue favorable tras la eliminación fenofibrato y la administración de inmunoglobulina G (IgG) más corticosteroides. El tema de la trombocitopenia inducida por medicamentos se repasa brevemente y se sugiere un posible mecanismo responsable de este efecto secundario de fenofibrato. Este es el primer reportado caso de fenofibrato- inducida inmune trombocitopenia.

References

1. Aster RH, Bougie DW. Drug-induced immune thrombocytopenia. *N Engl J Med* 2007;357:580-587.
2. Alsheikh-Ali AA, KuvvinJT, Karas RH. Risk of adverse events with fibrates. *Am J Cardiol* 2004;94:935-958.
3. FDA Adverse Events Reporting System (AERS). Food and Drug Administration Website. Available at: <http://www.drugcite.com/?q=FENOFIBRATE>. Accessed June, 1, 2009.
4. van den Bemt PM, Meyboom RH, Egberts AC. Drug-induced immune thrombocytopenia. *Drug Saf*. 2004; 27(15):1243-1252.
5. Aster RH, Curtis BR, McFarland JG, Bougie DW. Drug-induced immune thrombocytopenia: pathogenesis, diagnosis, and management. *J Thromb Haemost* 2009;7:911-918.
6. Kenney B, Stack G. Drug-induced thrombocytopenia. *Arch Pathol Lab Med* 2009;133:309-314.
7. Wazny LD, Ariano RE. Evaluation and management of drug-induced thrombocytopenia in the acutely ill patient. *Pharmacotherapy* 2000;20:292-307.
8. Undas A, Celińska-Löwenhoff M. [Antiplatelet effects of micronized fenofibrate in subjects with dyslipidemia.] [Article in Polish] *Pol Arch Med Wewn* 2007;117:235-240.

9. Lee JJ, Jin YR, Yu JY, et al. Antithrombotic and antiplatelet activities of fenofibrate, a lipid-lowering drug. *Atherosclerosis* 2009;206:375-382.
 10. Lippi G, Filippozzi L, Salvagno GL, et al. Increased Mean Platelet Volume in Patients With Acute Coronary Syndromes. *Arch Pathol Lab Med* 2009;133:1441-1443.
 11. Aster RH. Drug-induced immune cytopenias. *Toxicology* 2005;209:149-153.
 12. Warkentin TE, Hayward CP, Boshkov LK, et al. Sera from patients with heparin-induced thrombocytopenia generate platelet-derived microparticles with procoagulant activity: an explanation for the thrombotic complications of heparin-induced thrombocytopenia. *Blood* 1994;84:3691-3699.
 13. George JN, Raskob GE, Shah SR, et al. Drug-induced thrombocytopenia: a systematic review of published case reports. *Ann Intern Med* 1998;129:886-890.
-